An 18-year-old woman collapsed while practicing for a marathon in hot, humid weather. The patient subsequently vomited 3 times and had a tonic-clonic seizure. She has no chronic medical conditions and takes no medications. The patient does not use alcohol or illicit drugs. Temperature is 40.8 C (105.4 F), blood pressure is 90/60 mm Hg, pulse is 130/min, and respirations are 22/min. The patient is profusely sweating and is confused. Pupils are sluggishly reactive to light. Cardiopulmonary examination reveals clear lungs and normal heart sounds. Laboratory results are as follows:

Complete blood count

Hemoglobin	15.8 g/dL
Platelets	90,000/mm^3
Leukocytes	10,000/mm^3

Coagulation studies

PT	20 sec
Activated PTT	43 sec

Which of the following sets of hematologic findings is most likely to be present in this patient?

	Fibrinolysis	Thrombin production	Plasmin generation
A.	↓	↓	↓
B.	↓	↓	↑
C.	↓	↑	↑
D.	↓	↑	↓

Hemoglobin	15.8 g/dL
Platelets	90,000/mm^3
Leukocytes	10,000/mm^3

Coagulation studies

PT	20 sec
Activated PTT	43 sec

Which of the following sets of hematologic findings is most likely to be present in this patient?

	Fibrinolysis	Thrombin production	Plasmin generation
A.	↓	↓	↓
B.	↓	↓	↑
C.	↓	↑	↑
D.	↓	↑	↓
E.	↑	↑	↑
F.	↑	↑	↓

Submit

Hemoglobin	15.8 g/dL
Platelets	90,000/mm^3
Leukocytes	10,000/mm^3

Coagulation studies

PT	20 sec
Activated PTT	43 sec

Which of the following sets of hematologic findings is most likely to be present in this patient?

	Fibrinolysis	Thrombin production	Plasmin generation
A. (21%)	↓	↓	↓
B. (12%)	↓	↓	↑
C. (9%)	↓	↑	↑
D. (11%)	↓	↑	↓
✓ E. (36%)	↑	↑	↑
F. (7%)	↑	↑	↓

Correct answer
E

Answered correctly

Time Spent

Last Updated

Explanation

This patient with extreme hyperthermia and seizures has **exertional heat stroke**, a life-threatening multisystem disorder caused by inadequate body heat dissipation. Severe hyperthermia increases tissue oxygen demand and metabolic rate and shunts blood away from the central organs (eg, brain, kidneys, liver, GI tract) to the skin to dissipate heat. This can lead to tissue ischemia/necrosis and the release of procoagulant proteins (eg, tissue factor), which can trigger **disseminated intravascular coagulation** (DIC).

DIC is marked by the excessive activation of the extrinsic (tissue factor) coagulation cascade, leading to the **generation of thrombin** and cross-linked fibrin clots. **Fibrinolysis is then activated** to clear the intravascular thrombi; plasminogen is converted to **plasmin**, which cuts the cross-linked fibrin-fibers and generates fibrin-degradation products (eg, elevated D-dimer). Other anticoagulant proteins (eg, protein C, protein S) are also rapidly consumed.

Patients with acute DIC usually have bleeding (eg, oozing from venipuncture sites) and end organ damage (eg, confusion, lung injury, renal insufficiency); laboratory studies are diagnostic and show **thrombocytopenia** (due to consumption of platelets) and **prolonged PT/PTT** (due to consumption of coagulation factors).

Educational objective:
Disseminated intravascular coagulation is marked by widespread activation of the coagulation cascade, leading to excessive thrombin production and formation of microthrombi. Subsequent conversion of plasminogen to plasmin results in increased fibrinolysis to clear the thrombi. Laboratory studies show a consumption of clotting factors (prolonged PT/PTT) and platelets (thrombocytopenia) and signs of excessive fibrinolysis (eg, elevated D-dimer).

Pathophysiology	Hematology & Oncology	DIC
Subject	System	Topic

Copyright © UWorld. All rights reserved.

Correct answer
E

Answered correctly

Time Spent

Last Updated

Exhibit Display

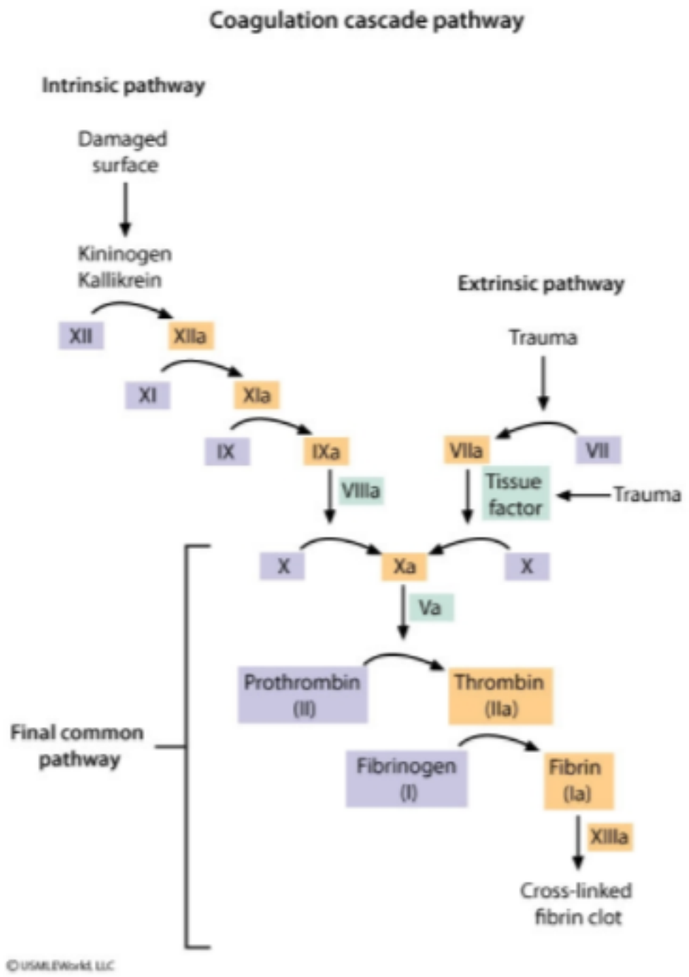

Zoom In | Zoom Out | Reset | Add To New Card | Existing Card

A 23-year-old Italian American man comes to the clinic for a follow-up visit. He was found to have mild anemia during a routine checkup 3 weeks ago and was started on iron supplementation. He has been taking the supplements as prescribed. The patient has otherwise been well. He feels that his energy levels are normal, and he has run several half-marathons in the last 2 years. The patient's initial hemoglobin level was 12.3 g/dL. Laboratory results obtained during today's visit are as follows:

Hemoglobin	12.2 g/dL
Erythrocyte count	5.8 million/mm^3
Mean corpuscular volume	70 μm^3
Leukocytes	6,500/mm^3
Platelets	180,000/mm^3
Hemoglobin A2	6% (normal 1%-3%)

The patient's blood smear is shown in the image below.

Which of the following processes is the initial step in the pathogenesis of this patient's disorder?

A. Cell membrane stability
B. DNA replication
C. Heme synthesis
D. Intracellular oxidant detoxification
E. mRNA formation
F. Protein folding
G. Protein solubility

4
5
6
7
8
9
10
11
12
13
14
15
16
17
18
19
20
21
22
23
24
25
26
27
28
29
30
31
32
33
34

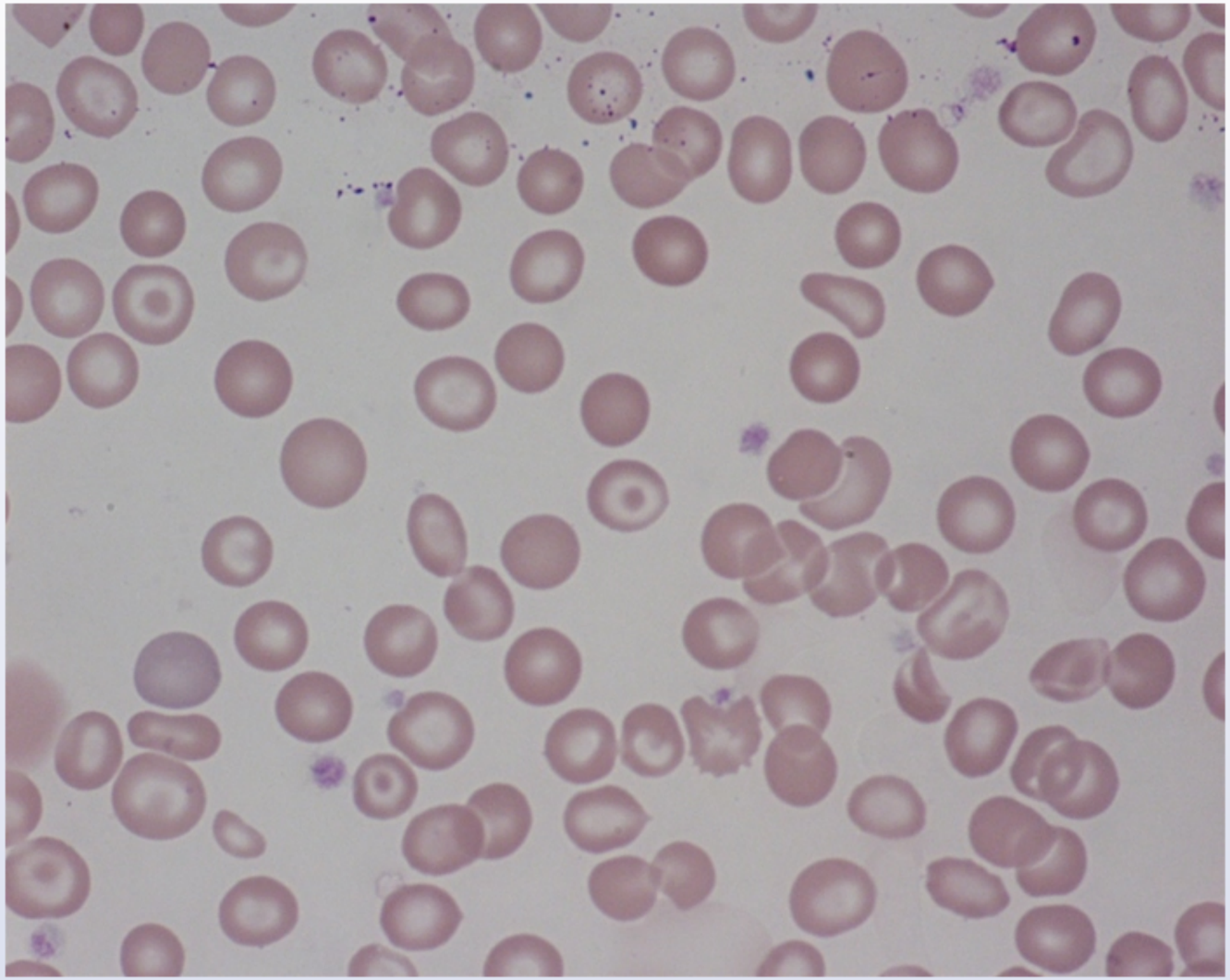

Which of the following processes is the initial step in the pathogenesis of this patient's disorder?

A. Cell membrane stability

4
5
6
7
8
9
10
11
12
13
14
15
16
17
18
19
20
21
22
23
24
25
26
27
28
29
30
31
32
33
34

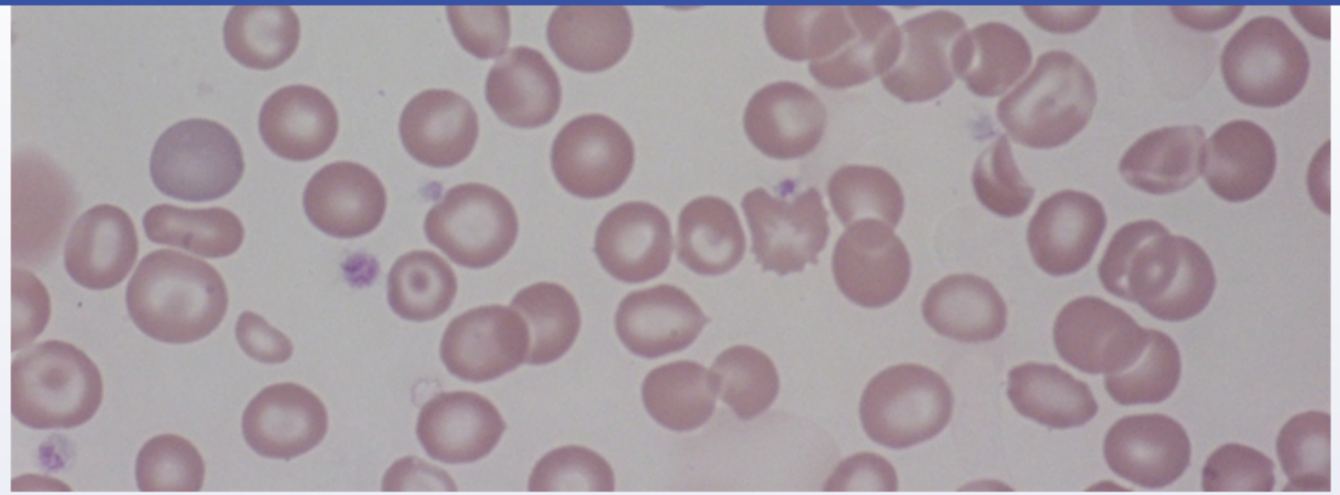

Which of the following processes is the initial step in the pathogenesis of this patient's disorder?

- A. Cell membrane stability
- B. DNA replication
- C. Heme synthesis
- D. Intracellular oxidant detoxification
- E. mRNA formation
- F. Protein folding
- G. Protein solubility

Submit

4
5
6
7
8
9
10
11
12
13
14
15
16
17
18
19
20
21
22
23
24
25
26
27
28
29
30
31
32
33
34

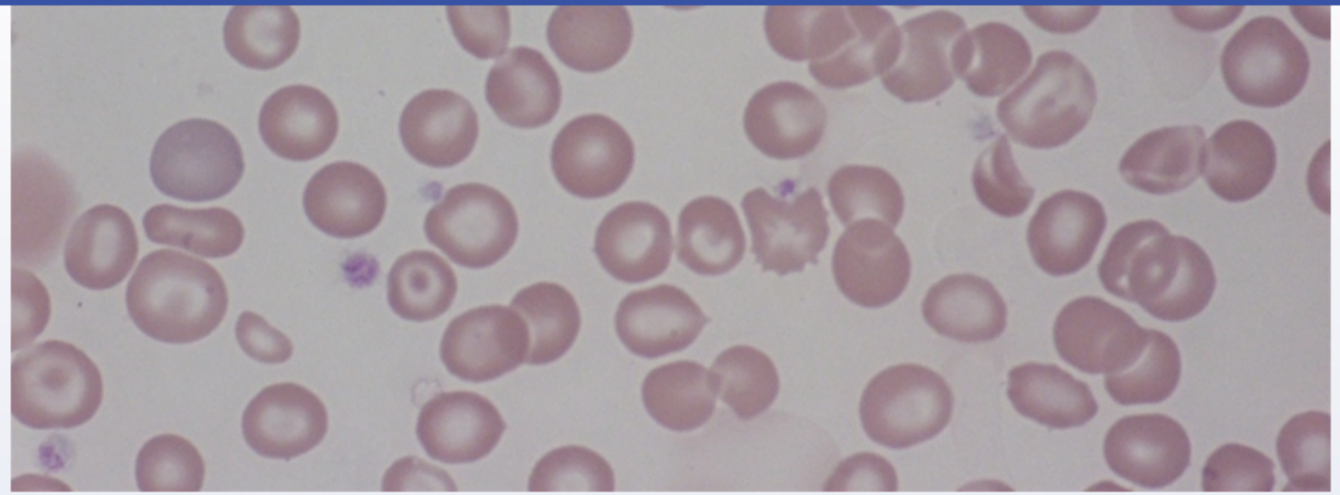

Which of the following processes is the initial step in the pathogenesis of this patient's disorder?

A. Cell membrane stability (13%)

B. DNA replication (7%)

C. Heme synthesis (25%)

D. Intracellular oxidant detoxification (3%)

✓ E. mRNA formation (29%)

F. Protein folding (18%)

G. Protein solubility (2%)

Omitted
Correct answer

29%
Answered correctly

08 secs
Time Spent

02/16/2020
Last Updated

4
5
6
7
8
9
10
11
12
13
14
15
16
17
18
19
20
21
22
23
24
25
26
27
28
29
30
31
32
33
34

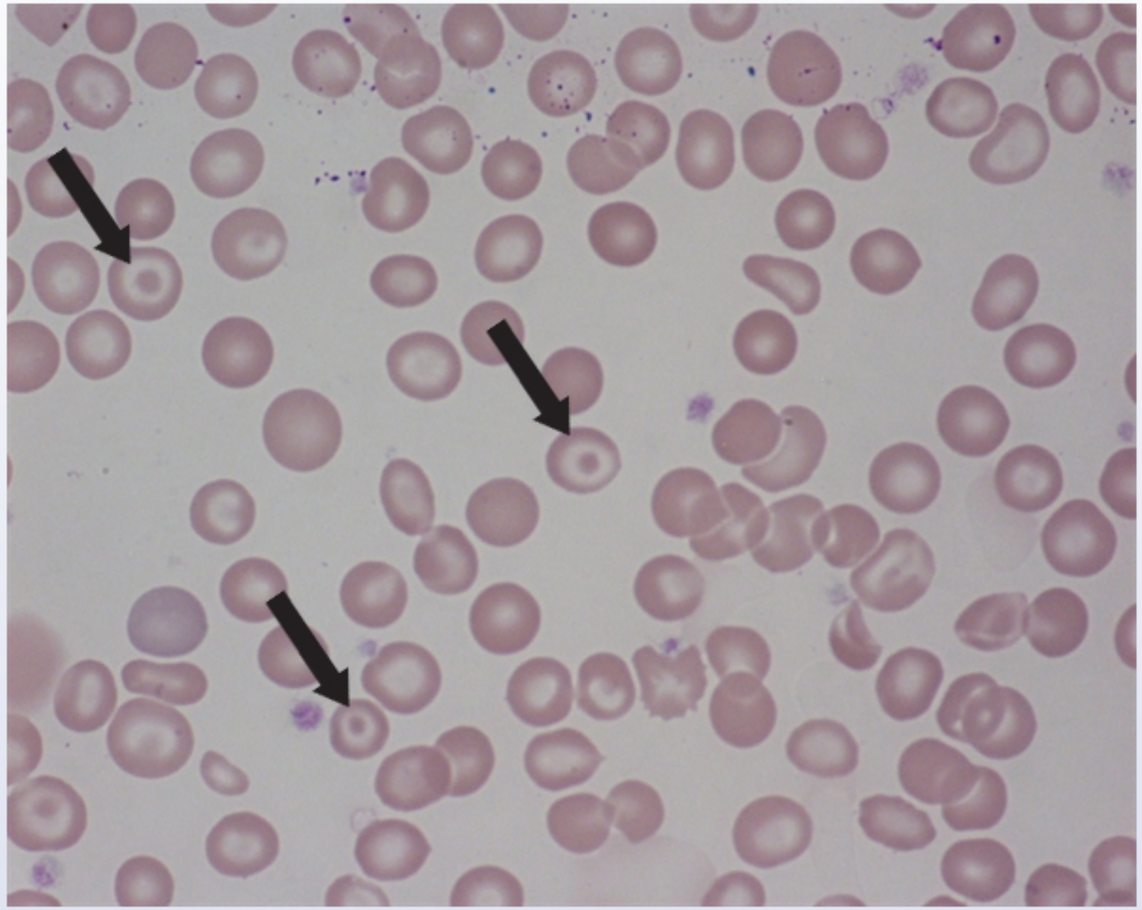

This patient has a **microcytic** (mean corpuscular volume [MCV] <75 μm^3) anemia and increased **hemoglobin A2** (α2δ2) concentration. His peripheral blood smear shows hypochromia and poikilocytes, including spherocytes and target cells (arrows). This constellation of findings in an asymptomatic adult of Mediterranean heritage suggests **beta-thalassemia minor**. Beta-thalassemia is the most common thalassemia in patients of Mediterranean descent; alpha-thalassemia is more common in individuals from Southeast Asia. The microcytic anemia is often incorrectly attributed to iron deficiency, but iron supplements do not benefit these patients as they are not iron deficient.

This patient has a **microcytic** (mean corpuscular volume [MCV] <75 μm³) anemia and increased **hemoglobin A2** (α2δ2) concentration. His peripheral blood smear shows hypochromia and poikilocytes, including spherocytes and target cells (arrows). This constellation of findings in an asymptomatic adult of Mediterranean heritage suggests **beta-thalassemia minor**. Beta-thalassemia is the most common thalassemia in patients of Mediterranean descent; alpha-thalassemia is more common in individuals from Southeast Asia. The microcytic anemia is often incorrectly attributed to iron deficiency, but iron supplements do not benefit these patients as they are not iron deficient.

Normal adult hemoglobin (hemoglobin A) contains 2 alpha chains and 2 beta chains (α2β2) in combination with heme. Beta-thalassemia affects beta-chain production and can be caused by a variety of DNA mutations affecting the **transcription, processing**, and **translation** of beta-globin **mRNA**. Most commonly, these mutations cause aberrant precursor mRNA splicing or premature chain termination during mRNA translation. In some cases, point mutations prevent RNA polymerase from binding to the promoter region. The resulting beta-globin deficiency occurs in the setting of normal heme and alpha-chain synthesis, leading to increased formation of hemoglobin A2 and (in some patients) **hemoglobin F** (α2γ2).

(Choices A and G) Decreased beta-chain synthesis in beta-thalassemia results in the formation of insoluble alpha-chain tetramers that precipitate within red blood cells. This can affect the membrane cytoskeleton and reduce membrane stability. However, the initial pathogenic abnormality in beta-thalassemia is a deficiency in beta-chain synthesis.

(Choice B) In patients with beta-thalassemia, the DNA replicates normally despite the mutations in the beta-globin gene. It is not until the DNA is transcribed into mRNA that hemoglobin production becomes abnormal. Anemias due to DNA synthesis defects include the megaloblastic anemias (vitamin B_{12} or folic acid deficiency), which are characterized by an elevated MCV (>100 μm³).

(Choice C) Heme is an iron-containing porphyrin that is incorporated into globin proteins to form hemoglobin. Globin synthesis, not heme synthesis, is abnormal in thalassemia syndromes. Porphyrias are disorders of heme synthesis.

(Choice D) Impaired intracellular oxidant detoxification occurs with glucose-6-phosphate dehydrogenase deficiency, a cause of hemolytic anemia.

(Choice F) An example of a protein folding defect is that caused by the Z mutation in the gene coding for alpha-1 antitrypsin.

Educational objective:
Beta-thalassemia is caused by mutations that result in defective transcription, processing, and translation of beta-globin mRNA. This leads to deficiency of the beta-globin chains required for normal hemoglobin synthesis.

mRNA. Most commonly, these mutations cause aberrant precursor mRNA splicing or premature chain termination during mRNA translation. In some cases, point mutations prevent RNA polymerase from binding to the promoter region. The resulting beta-globin deficiency occurs in the setting of normal heme and alpha-chain synthesis, leading to increased formation of hemoglobin A2 and (in some patients) **hemoglobin F** ($\alpha_2\gamma_2$).

(Choices A and G) Decreased beta-chain synthesis in beta-thalassemia results in the formation of insoluble alpha-chain tetramers that precipitate within red blood cells. This can affect the membrane cytoskeleton and reduce membrane stability. However, the initial pathogenic abnormality in beta-thalassemia is a deficiency in beta-chain synthesis.

(Choice B) In patients with beta-thalassemia, the DNA replicates normally despite the mutations in the beta-globin gene. It is not until the DNA is transcribed into mRNA that hemoglobin production becomes abnormal. Anemias due to DNA synthesis defects include the megaloblastic anemias (vitamin B_{12} or folic acid deficiency), which are characterized by an elevated MCV (>100 μm^3).

(Choice C) Heme is an iron-containing porphyrin that is incorporated into globin proteins to form hemoglobin. Globin synthesis, not heme synthesis, is abnormal in thalassemia syndromes. Porphyrias are disorders of heme synthesis.

(Choice D) Impaired intracellular oxidant detoxification occurs with glucose-6-phosphate dehydrogenase deficiency, a cause of hemolytic anemia.

(Choice F) An example of a protein folding defect is that caused by the Z mutation in the gene coding for alpha-1 antitrypsin.

Educational objective:
Beta-thalassemia is caused by mutations that result in defective transcription, processing, and translation of beta-globin mRNA. This leads to deficiency of the beta-globin chains required for normal hemoglobin synthesis.

References

- Control of human beta-globin mRNA stability and its impact on beta-thalassemia phenotype.
- Update on fetal hemoglobin gene regulation in hemoglobinopathies.

Pathophysiology	Hematology & Oncology	Thalassemia
Subject	System	Topic

Copyright © UWorld. All rights reserved.

A 50-year-old man with a long history of alcoholism is admitted to the hospital with difficulty breathing. Blood pressure is 90/40 mm Hg, pulse is 114/min, respirations are 22/min, and pulse oximetry is 92% on room air. Physical examination shows bilateral basal crackles, increased jugular venous pressure, hepatomegaly, ascites, and peripheral pitting edema. Chest x-ray demonstrates cardiomegaly. Scattered ecchymoses are present across each extremity. Laboratory results are as follows:

Platelets	120,000/mm^3
Prothrombin time	26 sec
Activated partial thromboplastin time	38 sec

The patient is given intramuscular vitamin K. Two days later, his laboratory results are unchanged. Which of the following is the most likely cause of this patient's laboratory abnormality?

A. Dietary vitamin K deficiency
B. Factor VII deficiency
C. Factor VIII deficiency
D. Intrinsic platelet dysfunction
E. Von Willebrand factor deficiency

Submit

A 50-year-old man with a long history of alcoholism is admitted to the hospital with difficulty breathing. Blood pressure is 90/40 mm Hg, pulse is 114/min, respirations are 22/min, and pulse oximetry is 92% on room air. Physical examination shows bilateral basal crackles, increased jugular venous pressure, hepatomegaly, ascites, and peripheral pitting edema. Chest x-ray demonstrates cardiomegaly. Scattered ecchymoses are present across each extremity. Laboratory results are as follows:

Platelets	120,000/mm^3
Prothrombin time	26 sec
Activated partial thromboplastin time	38 sec

The patient is given intramuscular vitamin K. Two days later, his laboratory results are unchanged. Which of the following is the most likely cause of this patient's laboratory abnormality?

- A. Dietary vitamin K deficiency (6%)
- ✓ B. Factor VII deficiency (53%)
- C. Factor VIII deficiency (10%)
- D. Intrinsic platelet dysfunction (15%)
- E. Von Willebrand factor deficiency (13%)

Omitted
Correct answer
B

53%
Answered correctly

03 secs
Time Spent

03/30/2020
Last Updated

Explanation

1
2
3
4
5
6
7
8
9
10
11
12
13
14
15
16
17
18
19
20
21
22
23
24
25
26
27
28
29
30
31

Signs of liver cirrhosis

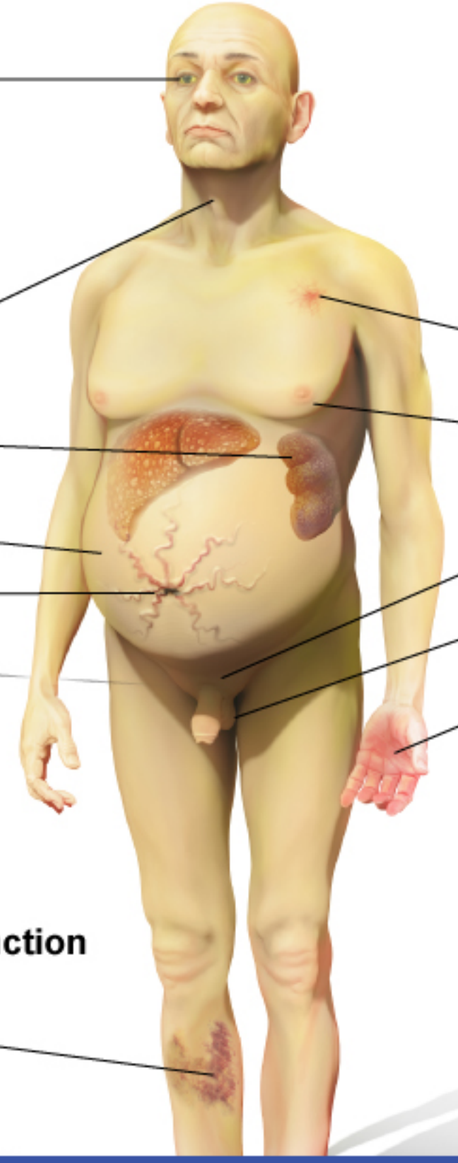

1
2
3
4
5
6
7
8
9
10
11
12
13
14
15
16
17
18
19
20
21
22
23
24
25
26
27
28
29
30
31

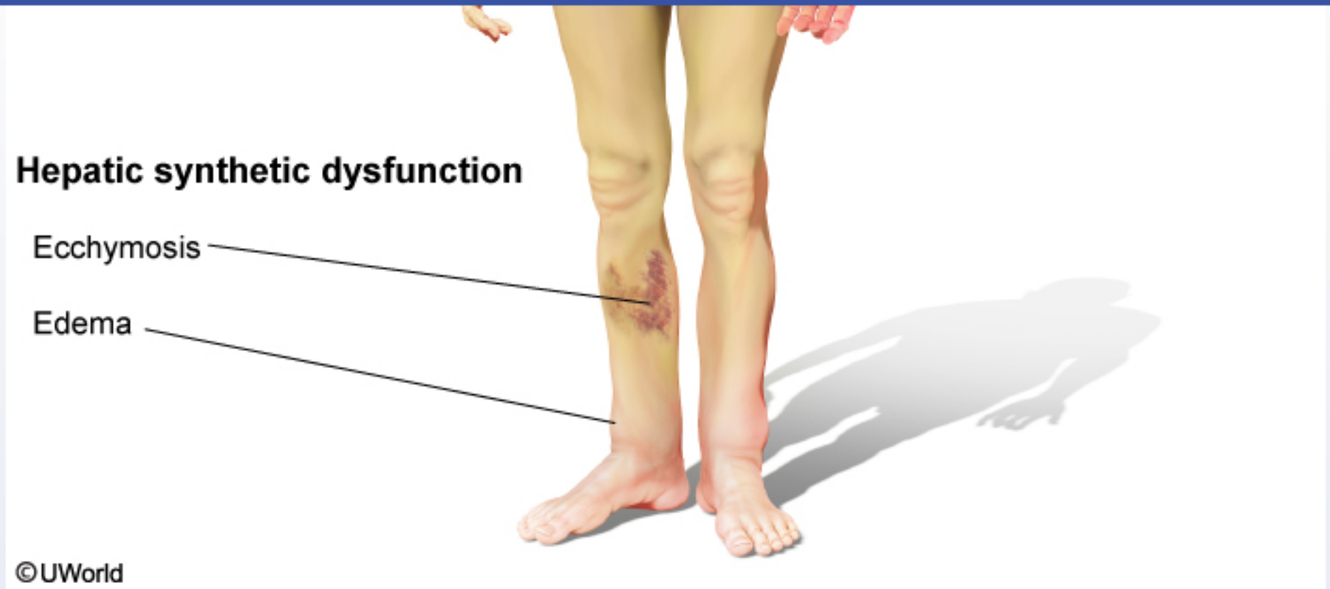

This patient has **liver dysfunction** due to **alcoholism**. The liver synthesizes many proteins, including clotting factors. Chronic alcohol use leads to progressive hepatic fibrosis/**cirrhosis**, resulting in acquired coagulopathy.

Clotting factors II, VII, IX, and X are produced initially by the liver in an inactive form and then activated by vitamin K-dependent carboxylation. **Factor VII**, part of the extrinsic pathway, has the **shortest half-life** of all coagulation factors. Prothrombin time (PT) assesses the extrinsic and common pathways of coagulation and is the first to become abnormal in liver disease. This patient's PT prolongation is likely due to factor VII deficiency in the setting of cirrhosis. Because clotting factor synthesis is impaired, PT may not improve with vitamin K supplementation as there are insufficient quantities of clotting factors to undergo vitamin K-dependent carboxylation/activation.

The liver also synthesizes albumin, and hypoalbuminemia results in ascites and peripheral edema. In addition, severe cirrhosis causes high-output heart failure due to chronic splanchnic vasodilation and development of mesenteric and intrahepatic arteriovenous shunts.

(Choice A) Dietary vitamin K deficiency impairs activation of factors II, VII, IX, and X. Risk factors include severe malnourishment (eg, alcoholism) and long-term antibiotic use (alters vitamin K-producing gut flora). In vitamin K deficiency, supplementation would likely improve PT.

(Choice C) In contrast to other coagulation factors, factor VIII is synthesized by endothelial cells. As part of the intrinsic pathway, factor VIII

This patient has **liver dysfunction** due to **alcoholism**. The liver synthesizes many proteins, including clotting factors. Chronic alcohol use leads to progressive hepatic fibrosis/**cirrhosis**, resulting in acquired coagulopathy.

Clotting factors II, VII, IX, and X are produced initially by the liver in an inactive form and then activated by vitamin K-dependent carboxylation. **Factor VII**, part of the extrinsic pathway, has the **shortest half-life** of all coagulation factors. Prothrombin time (PT) assesses the extrinsic and common pathways of coagulation and is the first to become abnormal in liver disease. This patient's PT prolongation is likely due to factor VII deficiency in the setting of cirrhosis. Because clotting factor synthesis is impaired, PT may not improve with vitamin K supplementation as there are insufficient quantities of clotting factors to undergo vitamin K-dependent carboxylation/activation.

The liver also synthesizes albumin, and hypoalbuminemia results in ascites and peripheral edema. In addition, severe cirrhosis causes high-output heart failure due to chronic splanchnic vasodilation and development of mesenteric and intrahepatic arteriovenous shunts.

(Choice A) Dietary vitamin K deficiency impairs activation of factors II, VII, IX, and X. Risk factors include severe malnourishment (eg, alcoholism) and long-term antibiotic use (alters vitamin K-producing gut flora). In vitamin K deficiency, supplementation would likely improve PT.

(Choice C) In contrast to other coagulation factors, factor VIII is synthesized by endothelial cells. As part of the intrinsic pathway, factor VIII deficiency results in prolonged activated partial thromboplastin time (PTT) with a normal PT. Hemophilia A is an X-linked recessive disorder of factor VIII deficiency.

(Choice D) Cirrhosis is associated with intrinsic platelet dysfunction and thrombocytopenia due to decreased hepatic synthesis of thrombopoietin and increased splenic platelet sequestration (secondary to hypersplenism). Platelet dysfunction and significant thrombocytopenia (eg, platelets <50,000/mm^3) lead to mucocutaneous bleeding/petechiae and prolonged bleeding time but do not affect PT.

(Choice E) Von Willebrand disease causes defects in platelet adhesion and coagulation (due to associated factor VIII deficiency). PTT may be normal or prolonged based on the level of factor VIII deficiency, and platelet aggregation to ristocetin will be abnormal.

Education objective:
Vitamin K-dependent coagulation factors (II, VII, IX, and X) are synthesized in the liver. Factor VII has the shortest half-life of the coagulation factors. Failure of the prothrombin time to correct with vitamin K supplementation indicates factor VII deficiency, which is often due to underlying liver disease.

References

The liver also synthesizes albumin, and hypoalbuminemia results in ascites and peripheral edema. In addition, severe cirrhosis causes high-output heart failure due to chronic splanchnic vasodilation and development of mesenteric and intrahepatic arteriovenous shunts.

(Choice A) Dietary vitamin K deficiency impairs activation of factors II, VII, IX, and X. Risk factors include severe malnourishment (eg, alcoholism) and long-term antibiotic use (alters vitamin K-producing gut flora). In vitamin K deficiency, supplementation would likely improve PT.

(Choice C) In contrast to other coagulation factors, factor VIII is synthesized by endothelial cells. As part of the intrinsic pathway, factor VIII deficiency results in prolonged activated partial thromboplastin time (PTT) with a normal PT. Hemophilia A is an X-linked recessive disorder of factor VIII deficiency.

(Choice D) Cirrhosis is associated with intrinsic platelet dysfunction and thrombocytopenia due to decreased hepatic synthesis of thrombopoietin and increased splenic platelet sequestration (secondary to hypersplenism). Platelet dysfunction and significant thrombocytopenia (eg, platelets <50,000/mm^3) lead to mucocutaneous bleeding/petechiae and prolonged bleeding time but do not affect PT.

(Choice E) Von Willebrand disease causes defects in platelet adhesion and coagulation (due to associated factor VIII deficiency). PTT may be normal or prolonged based on the level of factor VIII deficiency, and platelet aggregation to ristocetin will be abnormal.

Education objective:
Vitamin K-dependent coagulation factors (II, VII, IX, and X) are synthesized in the liver. Factor VII has the shortest half-life of the coagulation factors. Failure of the prothrombin time to correct with vitamin K supplementation indicates factor VII deficiency, which is often due to underlying liver disease.

References

- Coagulation abnormalities in the cirrhotic patient.
- Bleeding and bruising: a diagnostic work-up.

Pathophysiology	Hematology & Oncology	Cirrhosis
Subject	System	Topic

Copyright © UWorld. All rights reserved.

1
2
3
4
5
6
7
8
9
10
11
12
13
14
15
16
17
18
19
20
21
22
23
24
25
26
27
28
29
30
31

Exhibit Display

Coagulation cascade pathway

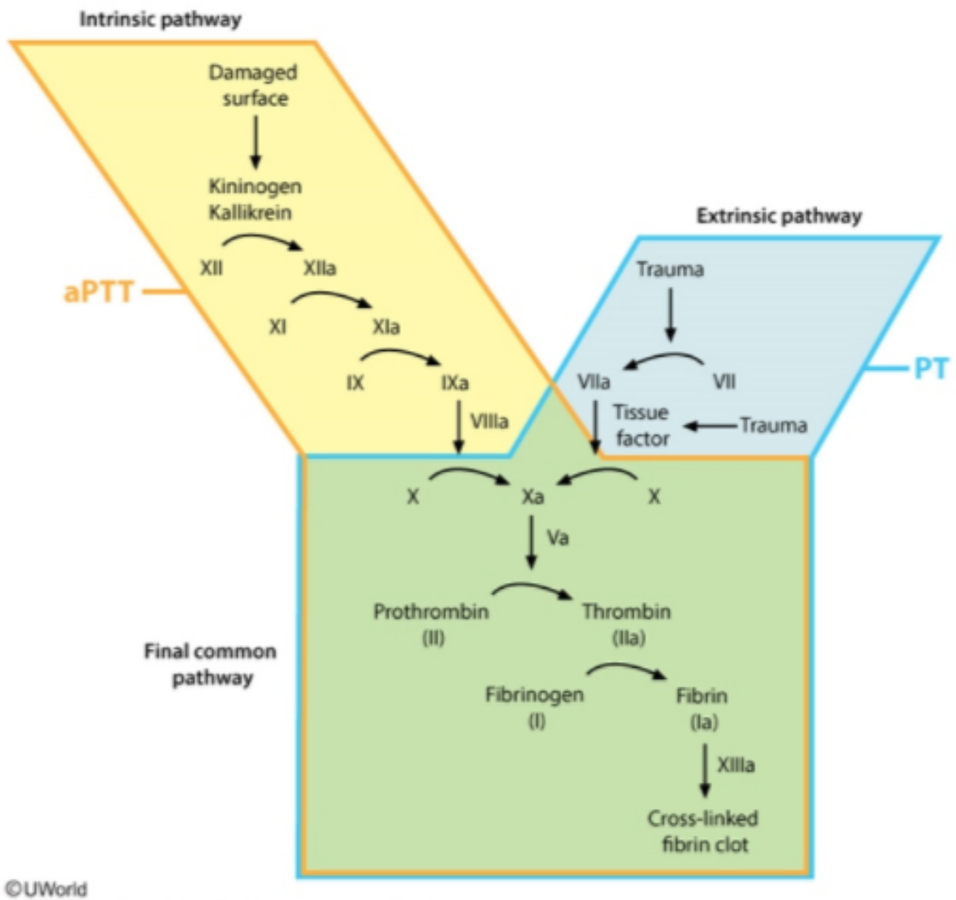

aPTT = activated partial thromboplastin time; PT = prothrombin time.

Zoom In | Zoom Out | Reset | Add To New Card | Existing Card

and increased splenic platelet sequestration (secondary to hypersplenism). Platelet dysfunction and significant thrombocytopenia (eg, platelets

1
2
3
4
5
6
7
8
9
10
11
12
13
14
15
16
17
18
19
20
21
22
23
24
25
26
27
28
29
30
31

Exhibit Display

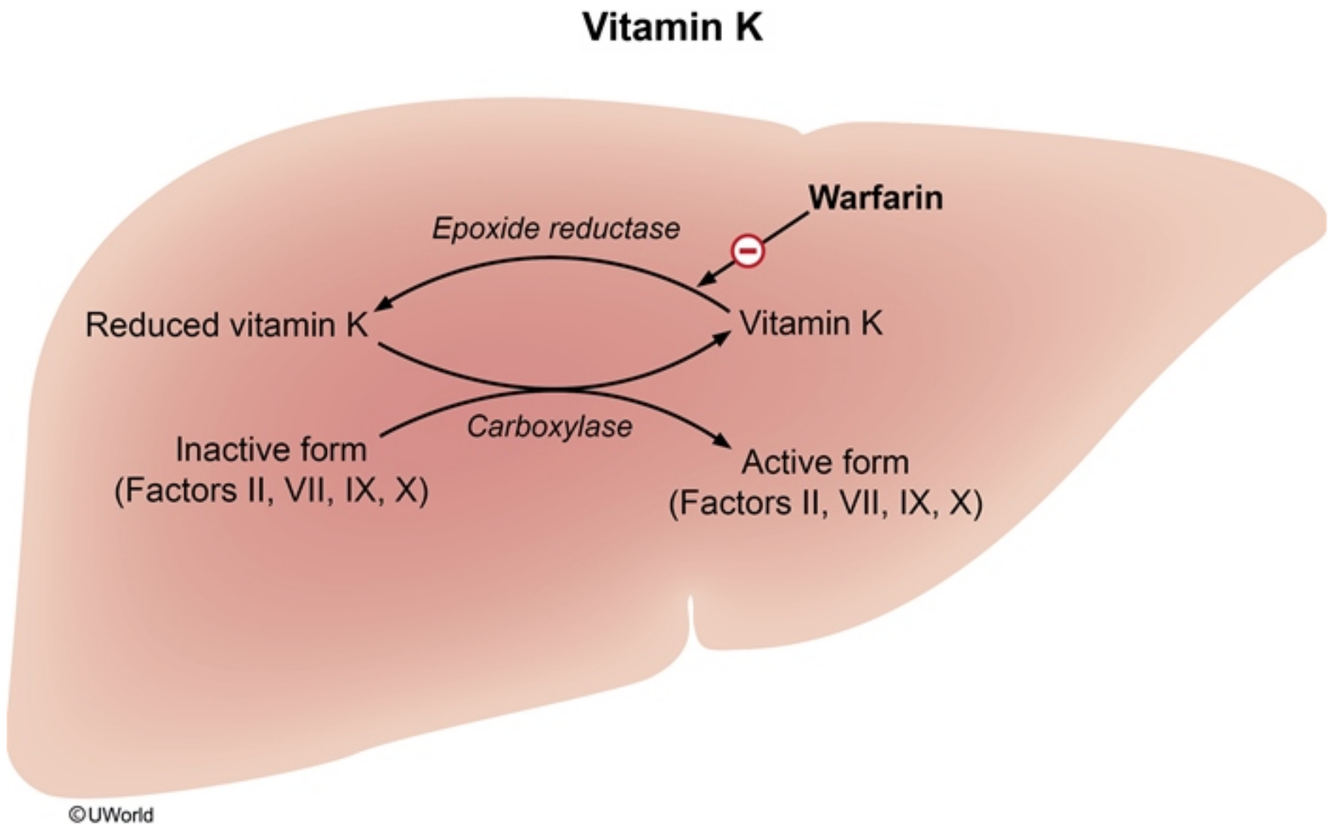

Zoom In | Zoom Out | Reset | Add To New Card | Existing Card

and increased splenic platelet sequestration (secondary to hypersplenism). Platelet dysfunction and significant thrombocytopenia (eg, platelets

The following vignette applies to the next **2** items. The items in the set must be answered in sequential order. Once you click **Proceed to Next Item**, you will not be able to add or change an answer.

A 24-year-old woman is being evaluated for chronic fatigue. She has a history of heavy menstrual periods since menarche and also recalls frequent nosebleeds as a child. Her past medical history is otherwise insignificant and she takes no medications. Laboratory studies show a hemoglobin level of 9.2 g/dL, a mean corpuscular volume of 72 fL, and decreased levels of ferritin.

Item 1 of 2

Which of the following is the most likely diagnosis?

- A. Antiphospholipid syndrome
- B. Factor VIII deficiency
- C. Factor XIII deficiency
- D. Immune thrombocytopenia
- E. Protein C deficiency
- F. von Willebrand factor deficiency

Submit

The following vignette applies to the next **2** items. The items in the set must be answered in sequential order. Once you click **Proceed to Next Item**, you will not be able to add or change an answer.

A 24-year-old woman is being evaluated for chronic fatigue. She has a history of heavy menstrual periods since menarche and also recalls frequent nosebleeds as a child. Her past medical history is otherwise insignificant and she takes no medications. Laboratory studies show a hemoglobin level of 9.2 g/dL, a mean corpuscular volume of 72 fL, and decreased levels of ferritin.

Item 1 of 2

Which of the following is the most likely diagnosis?

A. Antiphospholipid syndrome (7%)
B. Factor VIII deficiency (10%)
C. Factor XIII deficiency (1%)
D. Immune thrombocytopenia (11%)
E. Protein C deficiency (3%)
✓ F. von Willebrand factor deficiency (65%)

Omitted
Correct answer
F

65%
Answered correctly

02 secs
Time Spent

06/20/2020
Last Updated

Explanation

1 2 3 4 5 6 7 8 9 10 11 12 13 14 15 16 17 18 19 20 21 22 23 24 25 26 27 28 29 30 31

Laboratory characteristics of coagulopathies

	PT	aPTT	Platelet count	Bleeding time
Hemophilia A & B	Normal	↑	Normal	Normal
von Willebrand factor deficiency	Normal	Normal or ↑	Normal	↑
Disseminated intravascular coagulation	↑	↑	↓	↑
Uremic platelet dysfunction	Normal	Normal	Normal	↑
Heparin administration	Normal	↑	Normal (except in heparin-induced thrombocytopenia)	Normal
Warfarin use	↑	↑ (weak effect)	Normal	Normal
Immune thrombocytopenia	Normal	Normal	↓	↑

©UWorld

This patient has microcytic anemia with a low ferritin level, which is characteristic of **iron deficiency anemia**. In developed countries, iron deficiency anemia is most commonly caused by overt or occult blood loss. The patient's history of heavy menstrual periods (**menorrhagia**) since menarche and frequent nosebleeds (**epistaxis**) as a child further suggests **von Willebrand disease** (vWD) as the most likely etiology of her anemia.

In vWD, a mutation results in impaired synthesis in von Willebrand factor, leading to a qualitative defect in platelet binding and aggregation. As a result, patients with vWD experience easy bleeding from **skin and mucosal sites**, including the gingivae, nasal mucosa, gastrointestinal tract, and endometrium.

(Choice A) Antiphospholipid syndrome causes a hypercoagulable state that increases the risk of thromboses and spontaneous abortion.

(Choice B) Factor VIII deficiency causes hemophilia A. Severe forms of vWD can also result in factor VIII deficiency as factor VIII is protected from degradation by vWF. However, this patient does not have the characteristic deep-tissue bleeding (eg, bleeding into joints/muscles, gastrointestinal bleeding, hematuria) typically seen with clotting factor deficiencies.

(Choice C) Factor XIII deficiency is an extremely rare autosomal recessive disorder that causes clot instability. Affected patients often have delayed, recurrent bleeding after trauma or surgery. Hemophilia-like bleeding (eg, deep-tissue bleeding) is seen in factor XIII deficiency.

(Choice D) Immune thrombocytopenia (formerly immune thrombocytopenic purpura) produces isolated thrombocytopenia with episodic bleeding that is typically mucocutaneous (eg, petechiae, purpura, epistaxis). However, the associated bleeding is unlikely to be chronic and unrelenting since childhood.

(Choice E) Protein C is a natural anticoagulant protein, and deficiency results in a procoagulant state that most commonly manifests with recurrent deep venous thromboses.

Educational objective:
Patients with von Willebrand disease often present with a lifelong history of mucosal bleeding, including gingival bleeding, epistaxis, and/or menorrhagia. These patients have normal platelet levels but typically have a prolonged bleeding time due to impaired platelet functioning.

Pathophysiology	Hematology & Oncology	Von willebrand disease
Subject	System	Topic

Item 2 of 2

Further evaluation shows decreased von Willebrand factor activity in the patient's serum. This protein normally binds to which of the following?

A. Collagen

B. Fibrin polymer

C. Prostacyclin

D. Protein C

E. Thrombin

Submit

1 2 3 4 5 6 7 8 9 10 11 12 13 14 15 16 17 18 19 20 21 22 23 24 25 26 27 28 29 30 31

Item 2 of 2

Further evaluation shows decreased von Willebrand factor activity in the patient's serum. This protein normally binds to which of the following?

- ✓ A. Collagen (74%)
- B. Fibrin polymer (11%)
- C. Prostacyclin (1%)
- D. Protein C (3%)
- E. Thrombin (8%)

Omitted
Correct answer
A

74%
Answered correctly

02 secs
Time Spent

06/20/2020
Last Updated

Explanation

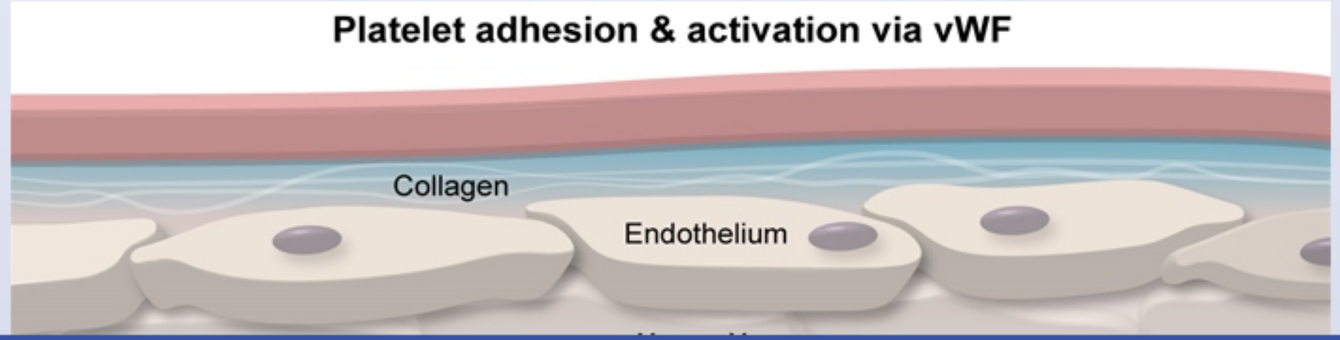

1
2
3
4
5
6
7
8
9
10
11
12
13
14
15
16
17
18
19
20
21
22
23
24
25
26
27
28
29
30
31

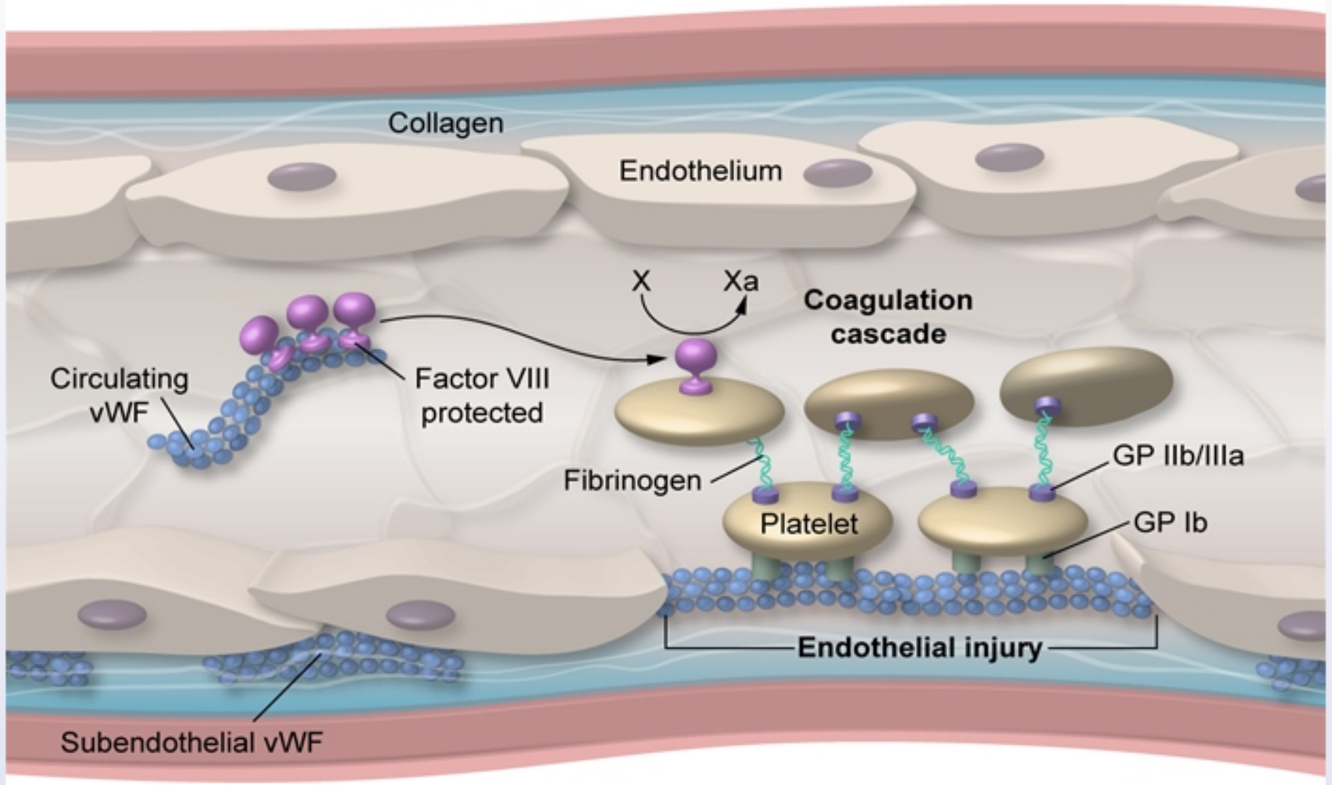

GP = glycoprotein; **vWF** = von Willebrand factor.

©UWorld

von Willebrand factor (vWF) serves 2 important roles in hemostasis:

1. vWF promotes **platelet adhesion** at sites of vascular injury by binding to and crosslinking **platelet glycoproteins** (primarily GpIb) with **exposed collagen** underneath damaged endothelium. vWF also enhances platelet aggregation, particularly under conditions of high shear stress (such as in small vessels).

2. vWF functions as a protective **carrier protein for factor VIII** that increases its plasma half-life. In the absence of vWF, factor VIII is rapidly degraded in the circulation via proteolytic inactivation.

GP = glycoprotein; vWF = von Willebrand factor.

©UWorld

von Willebrand factor (vWF) serves 2 important roles in hemostasis:

1. vWF promotes **platelet adhesion** at sites of vascular injury by binding to and crosslinking **platelet glycoproteins** (primarily GpIb) with **exposed collagen** underneath damaged endothelium. vWF also enhances platelet aggregation, particularly under conditions of high shear stress (such as in small vessels).
2. vWF functions as a protective **carrier protein for factor VIII** that increases its plasma half-life. In the absence of vWF, factor VIII is rapidly degraded in the circulation via proteolytic inactivation.

(Choice B) A hemostatic fibrin polymer is the end result of the coagulation cascade. Fibrin also plays a role in inflammation and coagulation regulation.

(Choice C) Prostacyclin functions both as an inhibitor of platelet aggregation and a vasodilator.

(Choice D) Protein C is a vitamin K-dependent anticoagulant activated by bound thrombin in the presence of endothelial thrombomodulin. Protein C acts together with protein S to inactivate the activated forms of factors V and VIII, which are necessary for the production of thrombin.

(Choice E) Thrombin is produced from prothrombin by activated factor X. Thrombin, in turn, converts fibrinogen to fibrin. Thrombin also activates factors V, VIII, and XIII.

Educational objective:
von Willebrand factor (vWF) functions as a promoter of platelet adhesion at sites of vascular injury by binding platelet glycoproteins to subendothelial collagen on injured blood vessel walls. It also acts as a protective carrier protein for circulating factor VIII.

References

- Platelet adhesive dynamics. Part II: high shear-induced transient aggregation via GPIba-vWF-GPIba bridging.
- The role of von Willebrand factor in thrombus formation.

Pathophysiology	Hematology & Oncology	Von willebrand disease
Subject	System	Topic

A 65-year-old man comes to the office due to several months of severe fatigue that limits his ability to do daily activities. He has also had upper abdominal fullness, early satiety, and unintentional weight loss but no fever, night sweats, cough, or rash. The patient has not seen a physician for many years. He does not use tobacco, alcohol, or illicit drugs and is a retired chemical engineer. Physical examination shows mucosal pallor with no scleral icterus. The lungs are clear on auscultation, and heart sounds are normal. There is mild hepatomegaly, and the spleen tip is palpable close to the midline of the abdomen. Laboratory evaluation reveals pancytopenia. Peripheral blood smear shows immature granulocytes, nucleated erythrocytes, and teardrop cells. Bone marrow aspiration is attempted but yields no marrow. Which of the following histopathological features is most likely to be present in this patient's spleen?

- A. Accumulation of macrophages with fibrillary cytoplasm
- B. Diffuse neutrophilic infiltration and follicular necrosis
- C. Dilated sinusoids and fibrous nodules with hemosiderin
- D. Large islands of hematopoietic progenitor cells
- E. Numerous noncaseating epithelioid granulomas

Submit

A 65-year-old man comes to the office due to several months of severe fatigue that limits his ability to do daily activities. He has also had upper abdominal fullness, early satiety, and unintentional weight loss but no fever, night sweats, cough, or rash. The patient has not seen a physician for many years. He does not use tobacco, alcohol, or illicit drugs and is a retired chemical engineer. Physical examination shows mucosal pallor with no scleral icterus. The lungs are clear on auscultation, and heart sounds are normal. There is mild hepatomegaly, and the spleen tip is palpable close to the midline of the abdomen. Laboratory evaluation reveals pancytopenia. Peripheral blood smear shows immature granulocytes, nucleated erythrocytes, and teardrop cells. Bone marrow aspiration is attempted but yields no marrow. Which of the following histopathological features is most likely to be present in this patient's spleen?

- A. Accumulation of macrophages with fibrillary cytoplasm (12%)
- B. Diffuse neutrophilic infiltration and follicular necrosis (4%)
- C. Dilated sinusoids and fibrous nodules with hemosiderin (18%)
- ✓ D. Large islands of hematopoietic progenitor cells (63%)
- E. Numerous noncaseating epithelioid granulomas (1%)

Omitted
Correct answer
D

63%
Answered correctly

01 sec
Time Spent

04/14/2020
Last Updated

Explanation

Primary myelofibrosis	
	Chronic myeloproliferative disorder with **clonal megakaryocytes** → secrete transforming growth factor-beta →

Primary myelofibrosis	
Pathogenesis	Chronic myeloproliferative disorder with **clonal megakaryocytes** → secrete transforming growth factor-beta → stimulates fibroblasts in BM to produce collagen → **BM fibrosis** → hematopoietic stem cells migrate to liver & spleen → **extramedullary hematopoiesis**
Manifestations	• Severe fatigue • Hepatomegaly + **massive splenomegaly** (can compress stomach) • ≥1 cytopenias • **Dacryocytes** (teardrop cells) on peripheral blood smear • BM aspiration – often **dry tap** due to fibrosis

BM = bone marrow.

Primary myelofibrosis is a chronic myeloproliferative disorder marked by the clonal expansion of atypical megakaryocytes. These atypical cells produce the cytokine transforming growth factor-beta, which stimulates fibroblasts in the bone marrow to lay down collagen, leading to subsequent **bone marrow fibrosis**. Because fibrotic bone marrow is inhospitable to hematopoietic stem and progenitors cells, these precursor cells migrate out of the bone marrow to the liver and spleen, the primary sites of **extramedullary hematopoiesis**.

The proliferation of erythroid, myeloid, and megakaryocytic **progenitor cells in the spleen** leads to a marked expansion of the splenic red pulp and usually results in **dramatic splenomegaly**. Nucleated red cells and immature granulocytes spill into the circulation and can be identified on peripheral blood smear. Dacrocytes are also common due to erythrocyte membrane damage during red blood cell production in the spleen or fibrotic marrow. Because extramedullary hematopoiesis is less efficient than medullary hematopoiesis, patients typically have one or more **cytopenias**.

The diagnosis of primary myelofibrosis requires bone marrow evaluation. Aspiration of bone marrow is frequently unsuccessful (**dry tap**) due to fibrosis. Therefore, bone marrow biopsy is generally required and usually shows hypocellular marrow with significant fibrosis and atypical megakaryocytes. A minority of primary myelofibrosis cases have been linked to chemical exposure (eg, toluene, benzene).

(Choice A) Gaucher disease is an autosomal recessive lysosomal storage disease associated with hepatosplenomegaly and pancytopenia due to the accumulation of fibrils of glucocerebroside (crumpled-paper appearance) within the cytoplasm of macrophages. However, most cases

Primary myelofibrosis is a chronic myeloproliferative disorder marked by the clonal expansion of atypical megakaryocytes. These atypical cells produce the cytokine transforming growth factor-beta, which stimulates fibroblasts in the bone marrow to lay down collagen, leading to subsequent **bone marrow fibrosis**. Because fibrotic bone marrow is inhospitable to hematopoietic stem and progenitors cells, these precursor cells migrate out of the bone marrow to the liver and spleen, the primary sites of **extramedullary hematopoiesis**.

The proliferation of erythroid, myeloid, and megakaryocytic **progenitor cells in the spleen** leads to a marked expansion of the splenic red pulp and usually results in **dramatic splenomegaly**. Nucleated red cells and immature granulocytes spill into the circulation and can be identified on peripheral blood smear. Dacrocytes are also common due to erythrocyte membrane damage during red blood cell production in the spleen or fibrotic marrow. Because extramedullary hematopoiesis is less efficient than medullary hematopoiesis, patients typically have one or more **cytopenias**.

The diagnosis of primary myelofibrosis requires bone marrow evaluation. Aspiration of bone marrow is frequently unsuccessful (**dry tap**) due to fibrosis. Therefore, bone marrow biopsy is generally required and usually shows hypocellular marrow with significant fibrosis and atypical megakaryocytes. A minority of primary myelofibrosis cases have been linked to chemical exposure (eg, toluene, benzene).

(Choice A) Gaucher disease is an autosomal recessive lysosomal storage disease associated with hepatosplenomegaly and pancytopenia due to the accumulation of fibrils of glucocerebroside (crumpled-paper appearance) within the cytoplasm of macrophages. However, most cases present in childhood. In addition, a dry tap on bone marrow aspirate and dacryocytes on peripheral smear would be atypical.

(Choice B) Acute infections of the spleen (eg, septic emboli from infective endocarditis) are typically associated with diffuse neutrophilic infiltration. Follicular necrosis is also common if the infection is due to group A *Streptococcus*. A dry tap, dacryocytes, and lack of fever make this less likely.

(Choice C) Congestive splenomegaly due to portal hypertension (eg, from liver cirrhosis) is associated with dilated sinusoids, fibrosis of the red pulp, and hemosiderin-laden macrophages. A dry tap and dacrocytes would be atypical.

(Choice E) Splenic noncaseating granulomas are common in sarcoidosis, some malignancies, and some infectious disorders. However, a dry tap and dacryocytes make primary myelofibrosis far more likely.

Educational objective:
Primary myelofibrosis is a chronic myeloproliferative disorder associated with bone marrow fibrosis. Extramedullary hematopoiesis leads to

out of the bone marrow to the liver and spleen, the primary sites of **extramedullary hematopoiesis**.

The proliferation of erythroid, myeloid, and megakaryocytic **progenitor cells in the spleen** leads to a marked expansion of the splenic red pulp and usually results in **dramatic splenomegaly**. Nucleated red cells and immature granulocytes spill into the circulation and can be identified on peripheral blood smear. Dacrocytes are also common due to erythrocyte membrane damage during red blood cell production in the spleen or fibrotic marrow. Because extramedullary hematopoiesis is less efficient than medullary hematopoiesis, patients typically have one or more **cytopenias**.

The diagnosis of primary myelofibrosis requires bone marrow evaluation. Aspiration of bone marrow is frequently unsuccessful (**dry tap**) due to fibrosis. Therefore, bone marrow biopsy is generally required and usually shows hypocellular marrow with significant fibrosis and atypical megakaryocytes. A minority of primary myelofibrosis cases have been linked to chemical exposure (eg, toluene, benzene).

(Choice A) Gaucher disease is an autosomal recessive lysosomal storage disease associated with hepatosplenomegaly and pancytopenia due to the accumulation of fibrils of glucocerebroside (crumpled-paper appearance) within the cytoplasm of macrophages. However, most cases present in childhood. In addition, a dry tap on bone marrow aspirate and dacryocytes on peripheral smear would be atypical.

(Choice B) Acute infections of the spleen (eg, septic emboli from infective endocarditis) are typically associated with diffuse neutrophilic infiltration. Follicular necrosis is also common if the infection is due to group A *Streptococcus*. A dry tap, dacryocytes, and lack of fever make this less likely.

(Choice C) Congestive splenomegaly due to portal hypertension (eg, from liver cirrhosis) is associated with dilated sinusoids, fibrosis of the red pulp, and hemosiderin-laden macrophages. A dry tap and dacrocytes would be atypical.

(Choice E) Splenic noncaseating granulomas are common in sarcoidosis, some malignancies, and some infectious disorders. However, a dry tap and dacryocytes make primary myelofibrosis far more likely.

Educational objective:
Primary myelofibrosis is a chronic myeloproliferative disorder associated with bone marrow fibrosis. Extramedullary hematopoiesis leads to marked expansion of the splenic red pulp with hematopoietic progenitor cells and results in massive splenomegaly. Patients also usually have hepatomegaly, cytopenias, and peripheral smear abnormalities (eg, dacrocytes, nucleated red cells, immature granulocytes).

References

1
2
3
4
5
6
7
8
9
10
11
12
13
14
15
16
17
18
19
20
21
22
23
24
25
26
27
28
29
30
31

out of the bone marrow to the liver and spleen, the primary sites of **extramedullary hematopoiesis**.

Exhibit Display

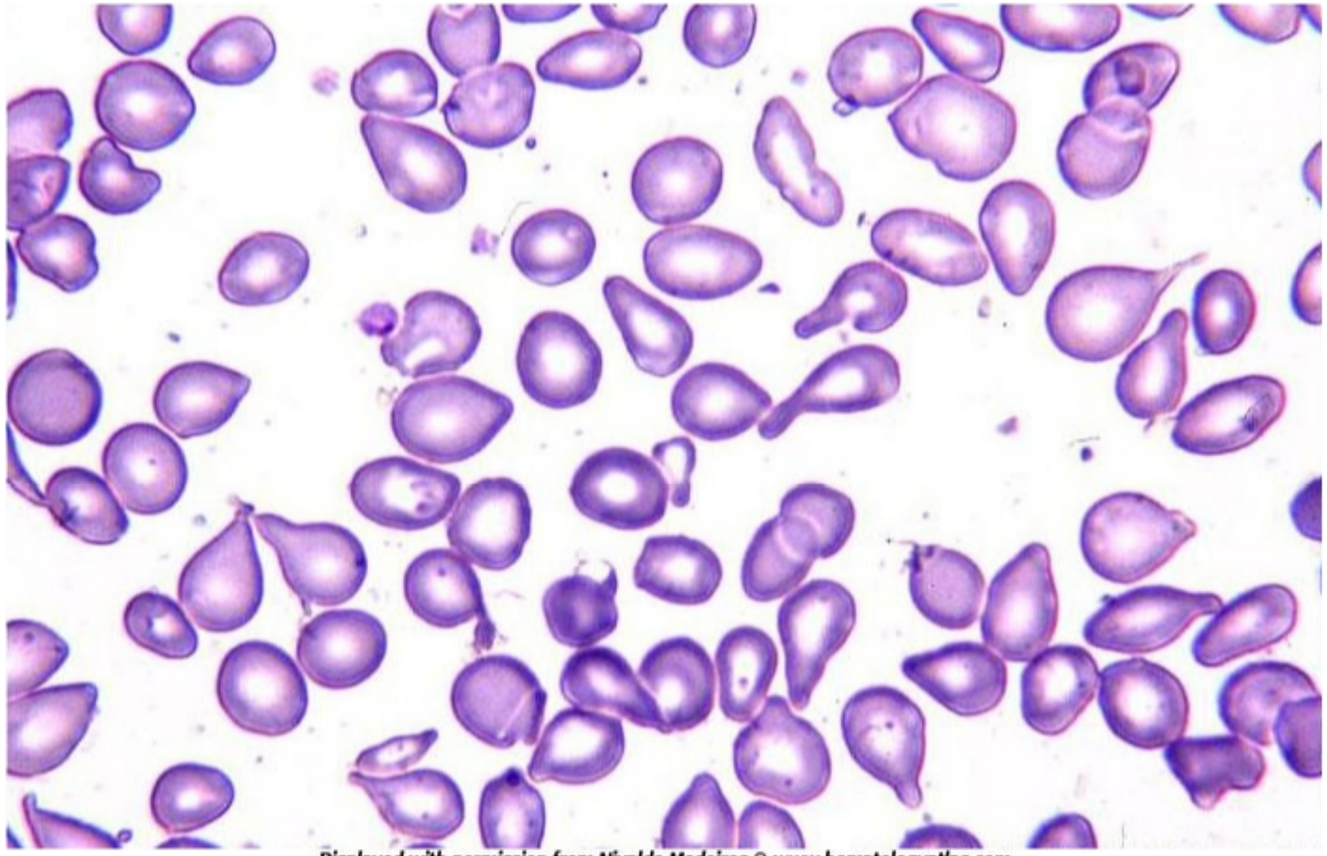

Displayed with permission from Nivaldo Medeiros © www.hematologyatlas.com

Zoom In | Zoom Out | Reset | Add To New Card | Existing Card

References

1
2
3
4
5
6
7
8
9
10
11
12
13
14
15
16
17
18
19
20
21
22
23
24
25
26
27
28
29
30
31

out of the bone marrow to the liver and spleen, the primary sites of **extramedullary hematopoiesis**.

Exhibit Display

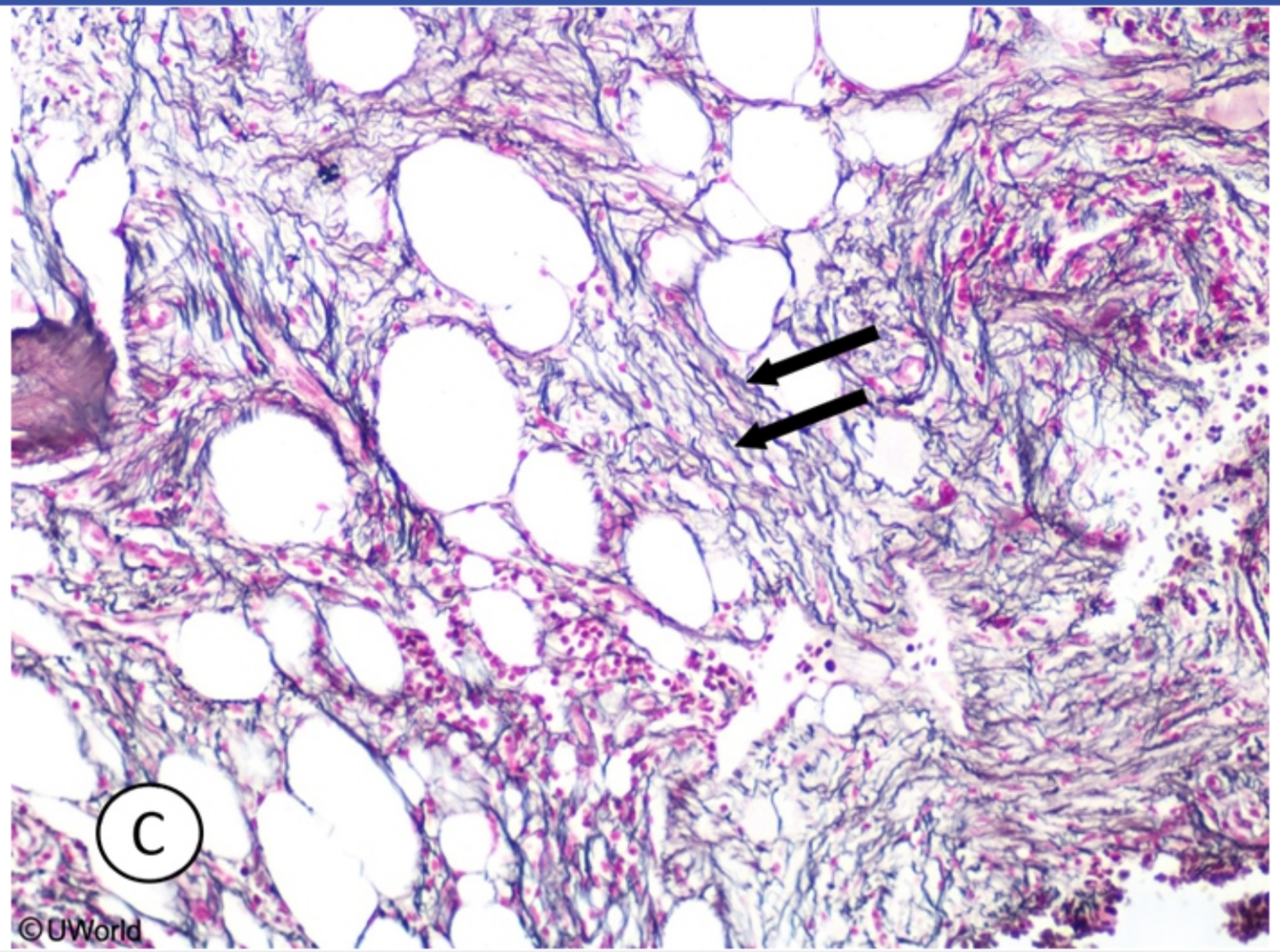

Zoom In | Zoom Out | Reset | Add To New Card | Existing Card

References

out of the bone marrow to the liver and spleen, the primary sites of **extramedullary hematopoiesis**.

Exhibit Display

Zoom In | Zoom Out | Reset | Add To New Card | Existing Card

References

1
2
3
4
5
6
7
8
9
10
11
12
13
14
15
16
17
18
19
20
21
22
23
24
25
26
27
28
29
30
31

out of the bone marrow to the liver and spleen, the primary sites of **extramedullary hematopoiesis**.

Exhibit Display

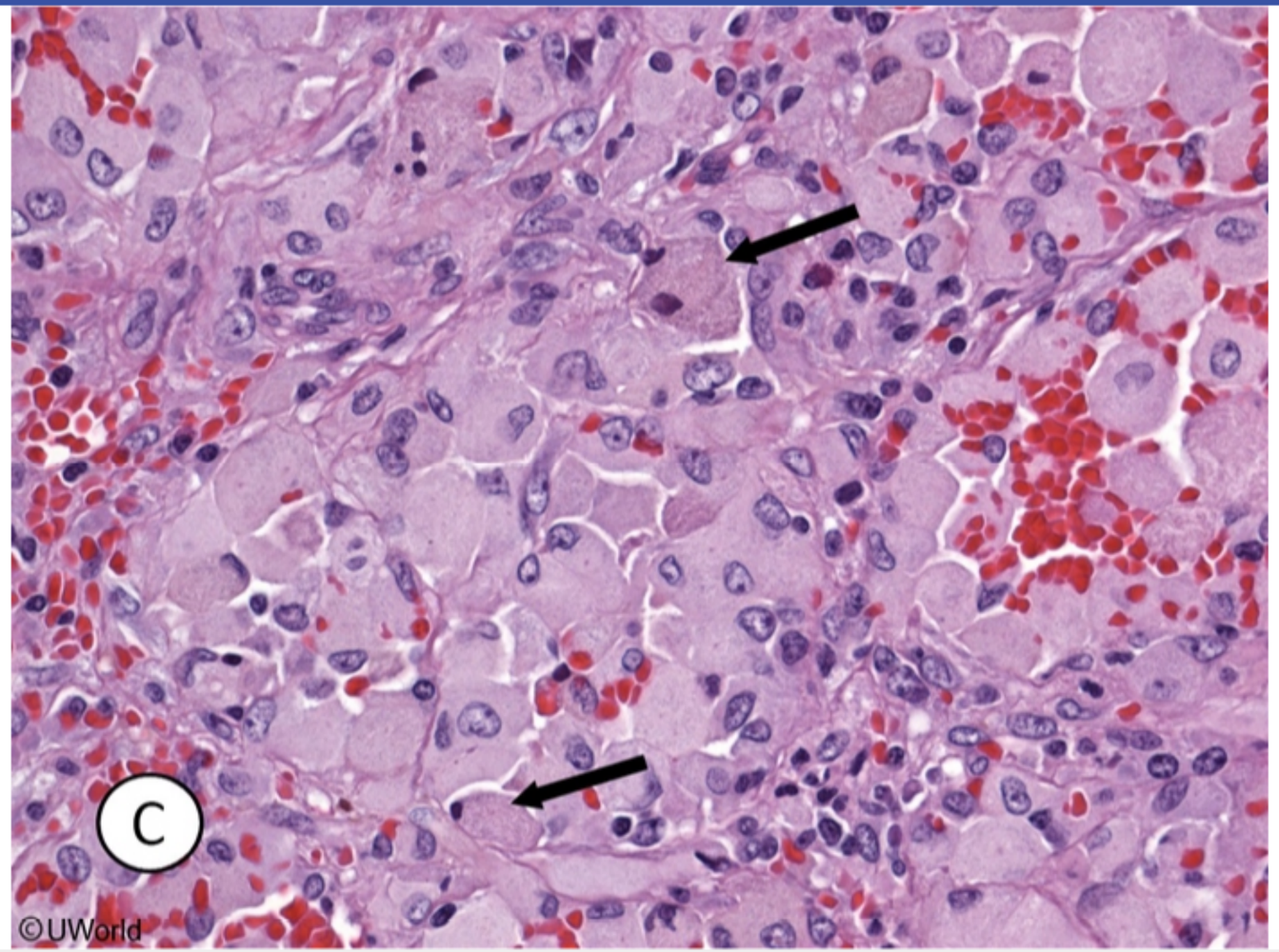

Zoom In | Zoom Out | Reset | Add To New Card | Existing Card

References

1
2
3
4
5
6
7
8
9
10
11
12
13
14
15
16
17
18
19
20
21
22
23
24
25
26
27
28
29
30
31

Exhibit Display

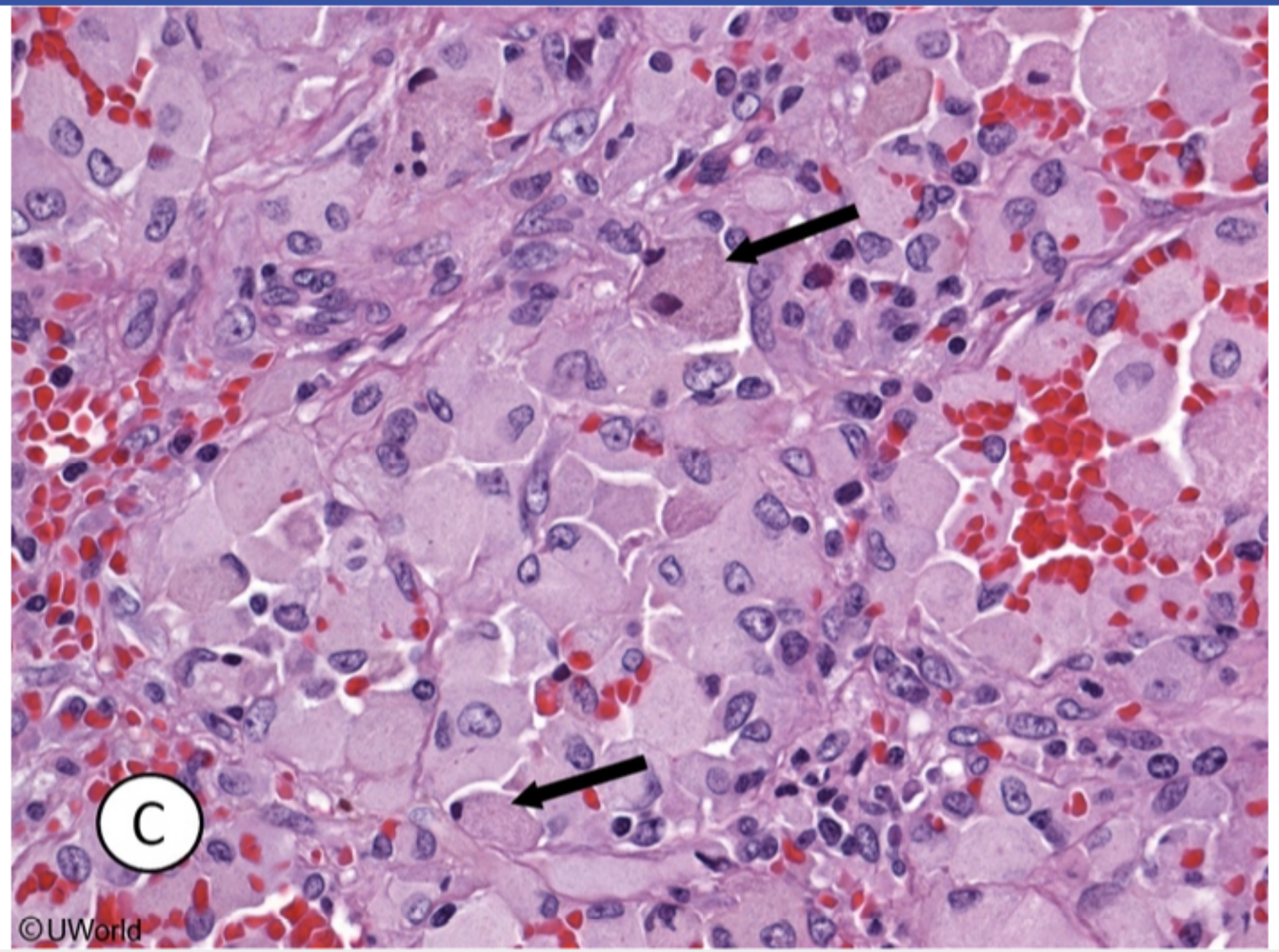

Zoom In | Zoom Out | Reset | Add To New Card | Existing Card

1
2
3
4
5
6
7
8
9
10
11
12
13
14
15
16
17
18
19
20
21
22
23
24
25
26
27
28
29
30
31

Exhibit Display

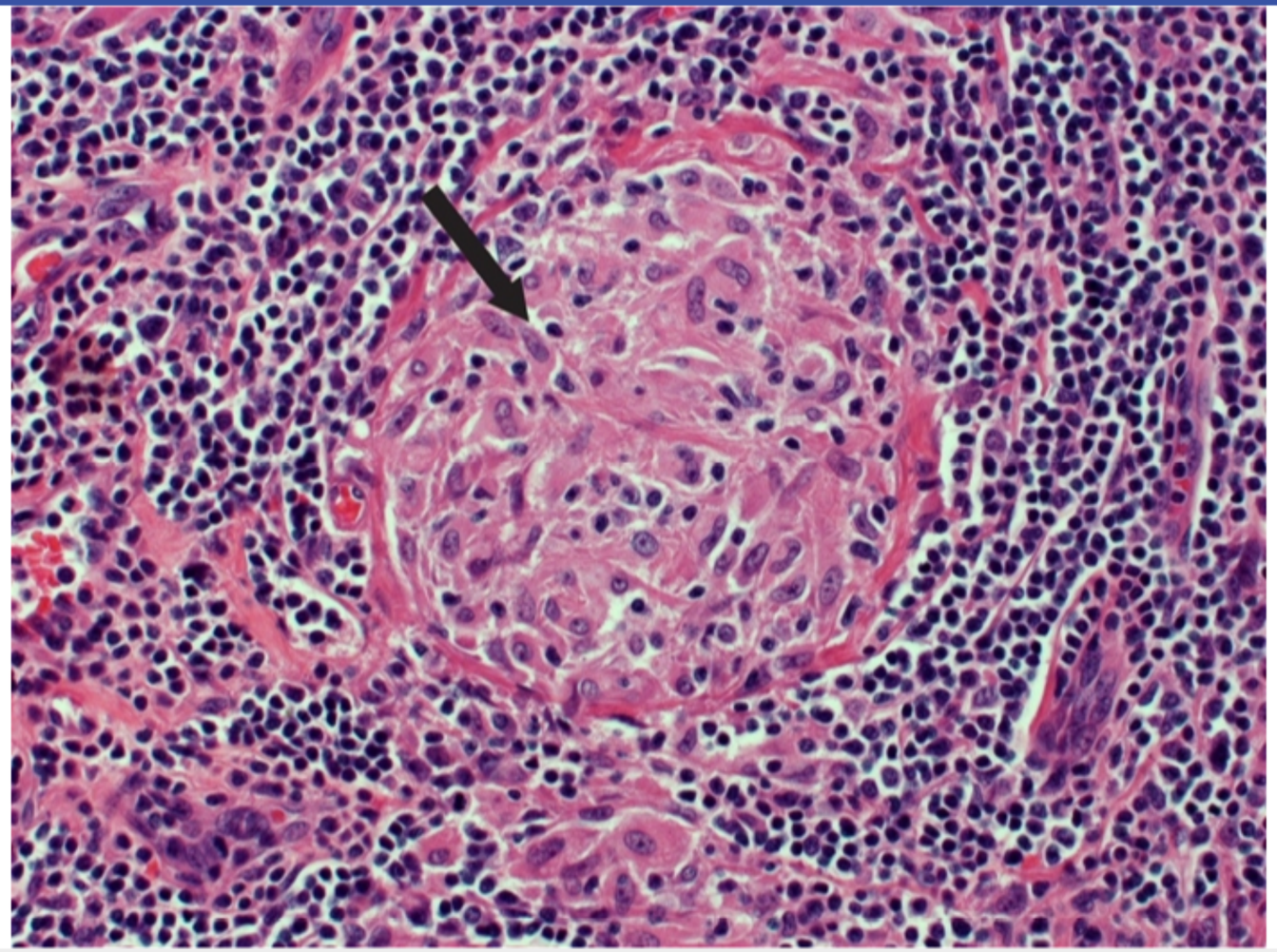

Zoom In | Zoom Out | Reset | Add To New Card | Existing Card

1
2
3
4
5
6
7
8
9
10
11
12
13
14
15
16
17
18
19
20
21
22
23
24
25
26
27
28
29
30
31

A 32-year-old woman reports fatigue and malaise over the last several days. The patient has not had any sick contacts. She does not appear to be in acute distress. After her initial evaluation, thrombotic thrombocytopenic purpura is suspected. Which of the following findings is essential in making the diagnosis?

A. Abnormal neurologic examination
B. Elevated blood pressure
C. Elevated liver enzymes
D. Fever
E. Hemolytic anemia
F. Renal failure

Submit

A 32-year-old woman reports fatigue and malaise over the last several days. The patient has not had any sick contacts. She does not appear to be in acute distress. After her initial evaluation, thrombotic thrombocytopenic purpura is suspected. Which of the following findings is essential in making the diagnosis?

- A. Abnormal neurologic examination (16%)
- B. Elevated blood pressure (0%)
- C. Elevated liver enzymes (5%)
- D. Fever (4%)
- ✓ E. Hemolytic anemia (65%)
- F. Renal failure (6%)

Omitted
Correct answer
E

65%
Answered correctly

02 secs
Time Spent

03/01/2020
Last Updated

Explanation

Thrombotic thrombocytopenic purpura	
Pathophysiology	• ↓ **ADAMTS13 level** → uncleaved vWF multimers → platelet trapping & activation • Acquired (autoantibody) or hereditary
	• Hemolytic **anemia** (↑ LDH, ↓ haptoglobin) with **schistocytes**

Thrombotic thrombocytopenic purpura	
Pathophysiology	• ↓ **ADAMTS13 level** → uncleaved vWF multimers → platelet trapping & activation • Acquired (autoantibody) or hereditary
Clinical features	• Hemolytic **anemia** (↑ LDH, ↓ haptoglobin) with **schistocytes** • **Thrombocytopenia** (↑ bleeding time, normal PT/PTT) Sometimes with: • Renal failure • Neurologic manifestations • Fever
Management	• Plasma exchange • Glucocorticoids • Rituximab

LDH = lactate dehydrogenase; **vWF** = von Willebrand factor.

Thrombotic thrombocytopenic purpura (TTP) is one of the primary thrombotic **microangiopathies**, which are characterized histopathologically by thrombi in arteriolar and capillary microvasculature. Hallmarks of the diagnosis are microangiopathic **hemolytic anemia** (MAHA) (nonimmune hemolytic anemia with schistocytes) and **thrombocytopenia** without any other obvious cause.

TTP was initially described as a pentad of fever, neurologic symptoms, kidney disease, MAHA, and thrombocytopenia (mortality rate ~90%). However, up to one-third of patients do not have neurologic abnormalities, half have normal kidney function, and only one-fifth have fever **(Choices A, D, and F)**. Currently, only MAHA and thrombocytopenia are required to consider the diagnosis, which significantly reduced **ADAMTS13** activity can help confirm. **Plasma exchange** is life-saving and should be considered in patients who have MAHA and thrombocytopenia and in whom TTP is suspected.

(Choice B) Hypertension is not a clinical feature of TTP.

(Choice C) HELLP syndrome is seen in pregnancy, particularly in patients with severe preeclampsia or eclampsia. The acronym and condition are defined hemolysis (MAHA), elevated liver enzymes, and low platelets.

1
2
3
4
5
6
7
8
9
10
11
12
13
14
15
16
17
18
19
20
21
22
23
24
25
26
27
28
29
30
31

	• Rituximab

LDH = lactate dehydrogenase; **vWF** = von Willebrand factor.

Thrombotic thrombocytopenic purpura (TTP) is one of the primary thrombotic **microangiopathies**, which are characterized histopathologically by thrombi in arteriolar and capillary microvasculature. Hallmarks of the diagnosis are microangiopathic **hemolytic anemia** (MAHA) (nonimmune hemolytic anemia with schistocytes) and **thrombocytopenia** without any other obvious cause.

TTP was initially described as a pentad of fever, neurologic symptoms, kidney disease, MAHA, and thrombocytopenia (mortality rate ~90%). However, up to one-third of patients do not have neurologic abnormalities, half have normal kidney function, and only one-fifth have fever **(Choices A, D, and F)**. Currently, only MAHA and thrombocytopenia are required to consider the diagnosis, which significantly reduced **ADAMTS13** activity can help confirm. **Plasma exchange** is life-saving and should be considered in patients who have MAHA and thrombocytopenia and in whom TTP is suspected.

(Choice B) Hypertension is not a clinical feature of TTP.

(Choice C) HELLP syndrome is seen in pregnancy, particularly in patients with severe preeclampsia or eclampsia. The acronym and condition are defined hemolysis (MAHA), elevated liver enzymes, and low platelets.

Educational objective:
Thrombotic thrombocytopenic purpura is one of several primary thrombotic microangiopathies resulting in microangiopathic hemolytic anemia and thrombocytopenia, which are essential to the diagnosis. Plasma exchange therapy has prompted more rapid diagnosis and is life-saving.

References

- How I treat thrombotic thrombocytopenic purpura and atypical haemolytic uraemic syndrome.
- Management of thrombotic thrombocytopenic purpura: current perspectives.

Pathophysiology	Hematology & Oncology	Thrombotic thrombocytopenic purpura
Subject	System	Topic

Copyright © UWorld. All rights reserved.

A 28-year-old woman comes to the emergency department with acute-onset abdominal pain, nausea, and confusion. She has no significant past medical history and does not use tobacco or alcohol as they have made her feel sick in the past. Serum lipase and liver function tests are within normal limits. CT scan of the abdomen shows no abnormalities. A sample of her urine is reddish in color and darkens on standing for 24 hours. Intravenous dextrose is administered and her symptoms improve significantly. Dextrose infusion most likely improved this patient's condition by affecting which of the following pathways?

- A. Gluconeogenesis
- B. Fatty acid synthesis
- C. Ketone body formation
- D. Porphyrin synthesis
- E. Protein catabolism
- F. Purine degradation

Submit

1
2
3
4
5
6
7
8
9
10
11
12
13
14
15
16
17
18
19
20
21
22
23
24
25
26
27
28
29
30
31

A 28-year-old woman comes to the emergency department with acute-onset abdominal pain, nausea, and confusion. She has no significant past medical history and does not use tobacco or alcohol as they have made her feel sick in the past. Serum lipase and liver function tests are within normal limits. CT scan of the abdomen shows no abnormalities. A sample of her urine is reddish in color and darkens on standing for 24 hours. Intravenous dextrose is administered and her symptoms improve significantly. Dextrose infusion most likely improved this patient's condition by affecting which of the following pathways?

A. Gluconeogenesis (11%)
B. Fatty acid synthesis (2%)
C. Ketone body formation (8%)
✓ D. Porphyrin synthesis (61%)
E. Protein catabolism (11%)
F. Purine degradation (4%)

Omitted
Correct answer
D

61%
Answered correctly

02 secs
Time Spent

04/17/2020
Last Updated

Explanation

Acute intermittent porphyria

CYP450 inducers
- Barbiturates
- Antiepileptics
- EtOH & smoking

1
2
3
4
5
6
7
8
9
10
11
12
13
14
15
16
17
18
19
20
21
22
23
24
25
26
27
28
29
30
31

Acute intermittent porphyria

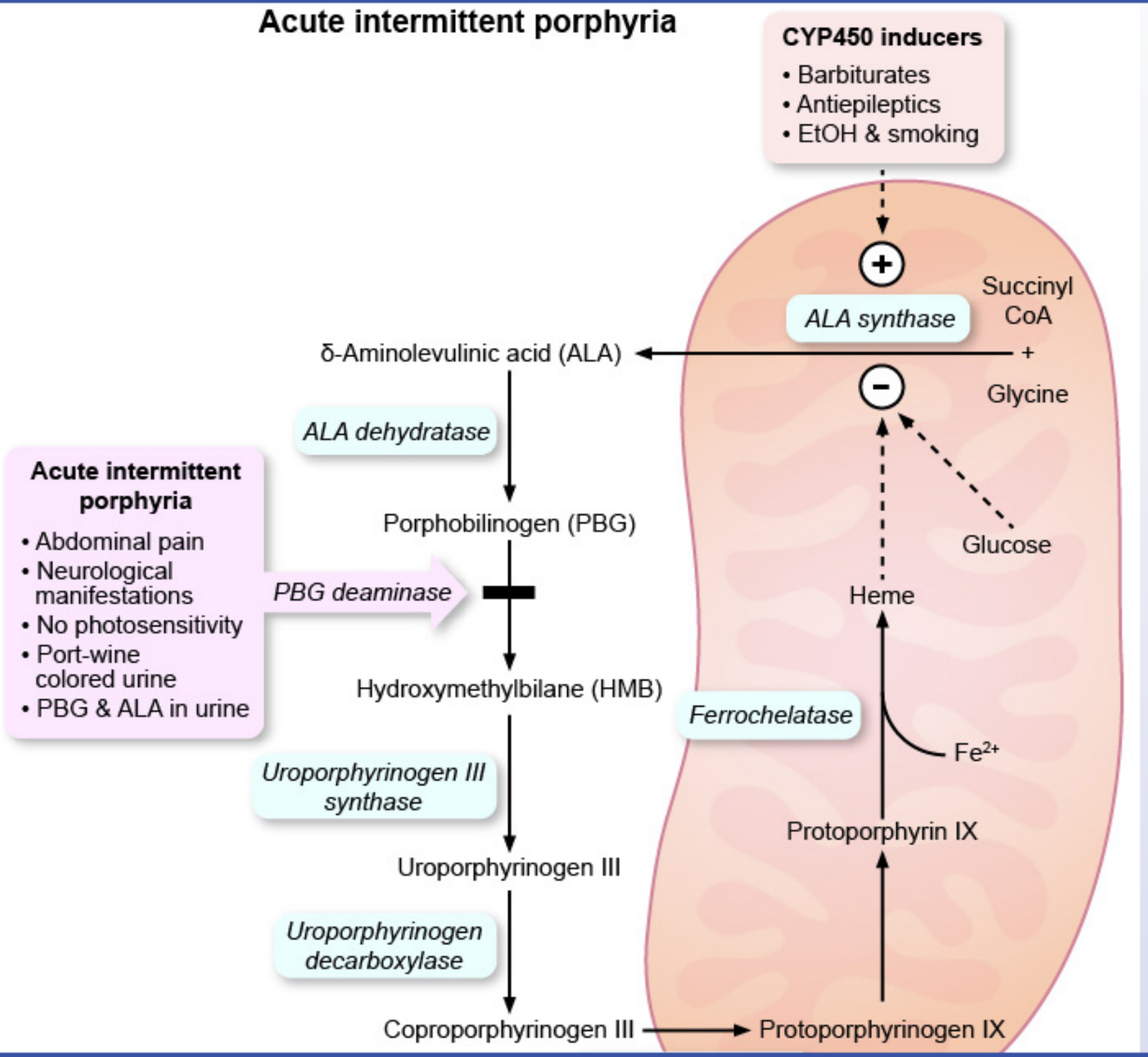

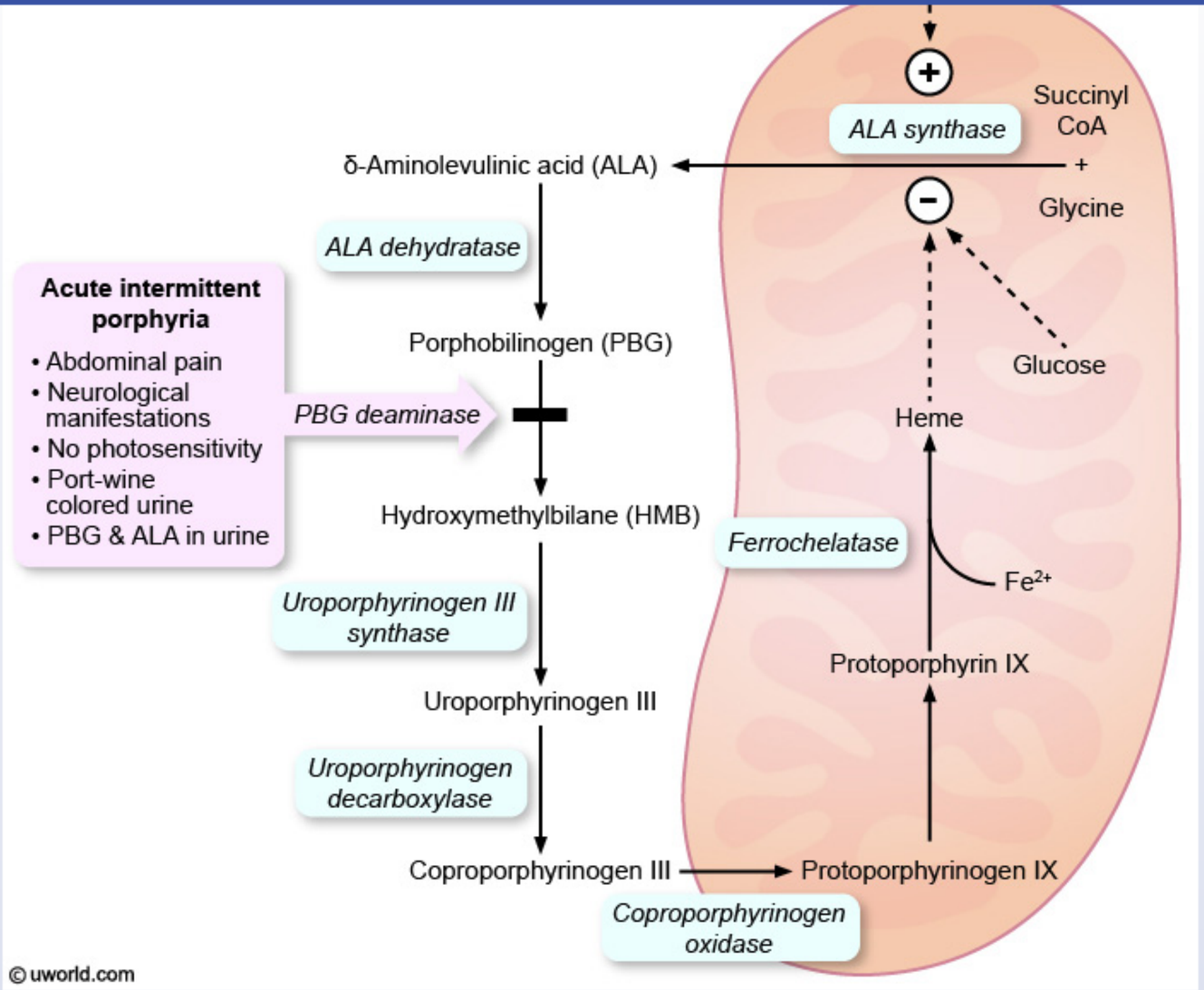

This patient most likely has **acute intermittent porphyria (AIP)**, an autosomal dominant disorder of the heme synthesis pathway caused by **porphobilinogen (PBG) deaminase deficiency**. In general, enzyme deficiencies in the early steps of porphyrin synthesis cause neurovisceral

This patient most likely has **acute intermittent porphyria (AIP)**, an autosomal dominant disorder of the heme synthesis pathway caused by **porphobilinogen (PBG) deaminase deficiency**. In general, enzyme deficiencies in the early steps of porphyrin synthesis cause neurovisceral symptoms (acute porphyrias); deficiencies in the latter steps (after condensation of PBG to HMB) result in photosensitivity (cutaneous porphyrias).

AIP is an acute porphyria that causes nervous system dysfunction due to the accumulation of early heme pathway intermediates (PBG and delta-aminolevulinic acid [ALA]). It presents **acutely** with variable **gastrointestinal and neurologic symptoms**, most commonly abdominal pain, vomiting, peripheral neuropathy, and neuropsychiatric derangements. A key feature of acute porphyrias is reddish urine that darkens on exposure to light and air due to the oxidation of excess PBG.

Treatment and prevention of acute porphyria attacks is directed at **inhibiting ALA synthase** (the rate-limiting enzyme of heme synthesis) to reduce formation of the toxic intermediate metabolites. ALA synthase is upregulated by **CYP450 inducers** (eg, most antiepileptics, griseofulvin, rifampin) and downregulated by **heme** and **glucose**. As such, avoidance of alcohol, smoking, and other CYP450-inducing drugs is important for preventing acute attacks. Likewise, intravenous heme administration and carbohydrate loading (such as with dextrose infusion) are useful for ameliorating acute symptoms.

(Choices A, B, C, E, and F) Administration of intravenous dextrose inhibits peroxisome proliferator-activated receptor-gamma, a transcription factor that induces synthesis of ALA synthase. This improves the symptoms of AIP by reducing the overall activity of the porphyrin synthesis pathway.

Educational objective:
Acute intermittent porphyria is an autosomal dominant condition caused by porphobilinogen deaminase deficiency. Most patients remain asymptomatic, but a minority present with acute attacks characterized by abdominal pain and vomiting, peripheral neuropathy, neuropsychological symptoms, and reddish-brown urine. Treatment consists of intravenous glucose or heme preparations, which downregulate ALA synthase activity.

Pathophysiology	Hematology & Oncology	Acute intermittent porphyria
Subject	System	Topic

Copyright © UWorld. All rights reserved.

© uworld.com

Exhibit Display

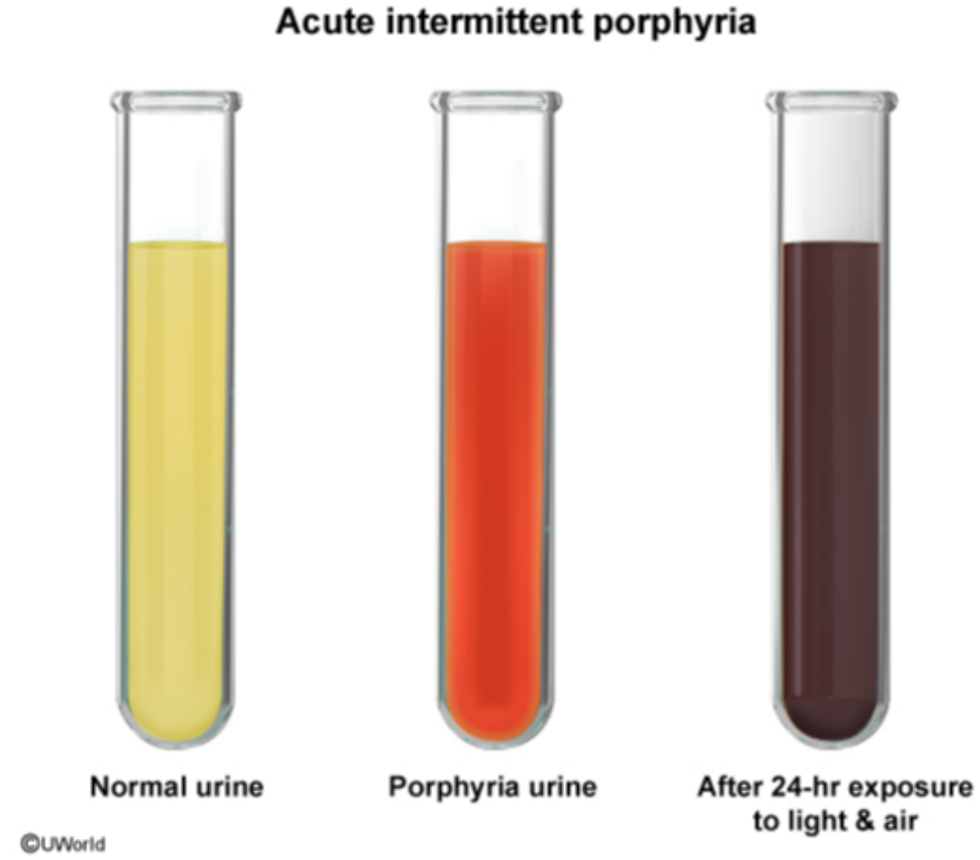

Zoom In | Zoom Out | Reset | Add To New Card | Existing Card

1
2
3
4
5
6
7
8
9
10
11
12
13
14
15
16
17
18
19
20
21
22
23
24
25
26
27
28
29
30
31

A 5-year-old boy is brought to the emergency department due to 2 days of dark, low-volume urine and decreased energy. The parents say that the boy had abdominal pain, fever, and bloody diarrhea for 4 days, which resolved about 3 days ago without treatment. The day before the onset of symptoms, the patient swam in a lake and ate hamburgers at a family picnic. His vital signs are within normal limits. Physical examination shows pallor but is otherwise normal. He has no peripheral edema or rashes. Laboratory evaluation shows anemia, thrombocytopenia, and elevated blood urea nitrogen and serum creatinine. Which of the following findings is most likely to be seen in this patient?

A. Elevated haptoglobin level

B. Elevated serum indirect bilirubin

C. Elevated thrombin and prothrombin time

D. Low fibrinogen and elevated D-dimer level

E. Positive Coombs test

F. Positive Streptozyme test

Submit

A 5-year-old boy is brought to the emergency department due to 2 days of dark, low-volume urine and decreased energy. The parents say that the boy had abdominal pain, fever, and bloody diarrhea for 4 days, which resolved about 3 days ago without treatment. The day before the onset of symptoms, the patient swam in a lake and ate hamburgers at a family picnic. His vital signs are within normal limits. Physical examination shows pallor but is otherwise normal. He has no peripheral edema or rashes. Laboratory evaluation shows anemia, thrombocytopenia, and elevated blood urea nitrogen and serum creatinine. Which of the following findings is most likely to be seen in this patient?

- A. Elevated haptoglobin level (9%)
- ✓ B. Elevated serum indirect bilirubin (53%)
- C. Elevated thrombin and prothrombin time (7%)
- D. Low fibrinogen and elevated D-dimer level (14%)
- E. Positive Coombs test (10%)
- F. Positive Streptozyme test (4%)

Omitted
Correct answer
B

53%
Answered correctly

03 secs
Time Spent

02/19/2020
Last Updated

Explanation

Hemolytic uremic syndrome	
	Shiga toxin-producing bacteria

Hemolytic uremic syndrome	
Etiology	Shiga toxin-producing bacteria • *Escherichia coli* O157:H7 • *Shigella*
Clinical features	• Antecedent diarrheal illness (often bloody) • Hemolytic anemia with schistocytes • Thrombocytopenia • Acute kidney injury

©UWorld

This patient has **hemolytic uremic syndrome (HUS)**, which is most often caused by infection with shiga toxin-producing organisms such as ***Escherichia coli* O157:H7** or *Shigella dysenteriae*. Shiga toxin (verotoxin) enters the circulation from the bowel and induces capillary endothelial damage, resulting in platelet activation with the formation of microthrombi. Platelet consumption causes **thrombocytopenia** whereas the microthrombi lead to erythrocyte damage (forming schistocytes) and the resultant **hemolytic anemia** (eg, pallor, weakness, tachycardia). Damage to glomerular endothelial cells also causes **acute kidney injury** (eg, oliguria/anuria, increased creatinine) in approximately 50% of cases.

The hemolytic anemia in HUS causes decreased hemoglobin and haptoglobin levels as well as increased serum lactate dehydrogenase and unconjugated bilirubin levels **(Choice A)**. The bleeding time may also be increased due to the reduced number of platelets. However, other coagulation studies are normal as there are no clotting factor deficiencies or disseminated intravascular coagulation associated with HUS **(Choices C and D)**.

(Choice E) Coombs test, or direct antiglobulin test, detects autoantibodies against red blood cells if they are present in the serum. The hemolytic anemia of HUS syndrome is mechanical rather than autoimmune; therefore, the Coombs test is negative.

(Choice F) Streptozyme testing detects antibodies against group A *Streptococcus* and can be used to retrospectively diagnose streptococcal infections (eg, when evaluating for post-streptococcal glomerulonephritis [PSGN]). However, children with PSGN have edema and hypertension, but no hemolytic anemia.

	• Acute kidney injury

©UWorld

This patient has **hemolytic uremic syndrome (HUS)**, which is most often caused by infection with shiga toxin-producing organisms such as ***Escherichia coli* O157:H7** or *Shigella dysenteriae*. Shiga toxin (verotoxin) enters the circulation from the bowel and induces capillary endothelial damage, resulting in platelet activation with the formation of microthrombi. Platelet consumption causes **thrombocytopenia** whereas the microthrombi lead to erythrocyte damage (forming schistocytes) and the resultant **hemolytic anemia** (eg, pallor, weakness, tachycardia). Damage to glomerular endothelial cells also causes **acute kidney injury** (eg, oliguria/anuria, increased creatinine) in approximately 50% of cases.

The hemolytic anemia in HUS causes decreased hemoglobin and haptoglobin levels as well as increased serum lactate dehydrogenase and unconjugated bilirubin levels **(Choice A)**. The bleeding time may also be increased due to the reduced number of platelets. However, other coagulation studies are normal as there are no clotting factor deficiencies or disseminated intravascular coagulation associated with HUS **(Choices C and D)**.

(Choice E) Coombs test, or direct antiglobulin test, detects autoantibodies against red blood cells if they are present in the serum. The hemolytic anemia of HUS syndrome is mechanical rather than autoimmune; therefore, the Coombs test is negative.

(Choice F) Streptozyme testing detects antibodies against group A *Streptococcus* and can be used to retrospectively diagnose streptococcal infections (eg, when evaluating for post-streptococcal glomerulonephritis [PSGN]). However, children with PSGN have edema and hypertension, but no hemolytic anemia.

Educational objective:
Hemolytic uremic syndrome (HUS) manifests with acute kidney injury, microangiopathic hemolytic anemia, and thrombocytopenia. Characteristic laboratory abnormalities include decreased hemoglobin and platelet count and increased bleeding time, lactate dehydrogenase, bilirubin, blood urea nitrogen, and creatinine.

Pathophysiology	Hematology & Oncology	Hemolytic uremic syndrome
Subject	System	Topic

Copyright © UWorld. All rights reserved.

- Acute kidney injury

Exhibit Display

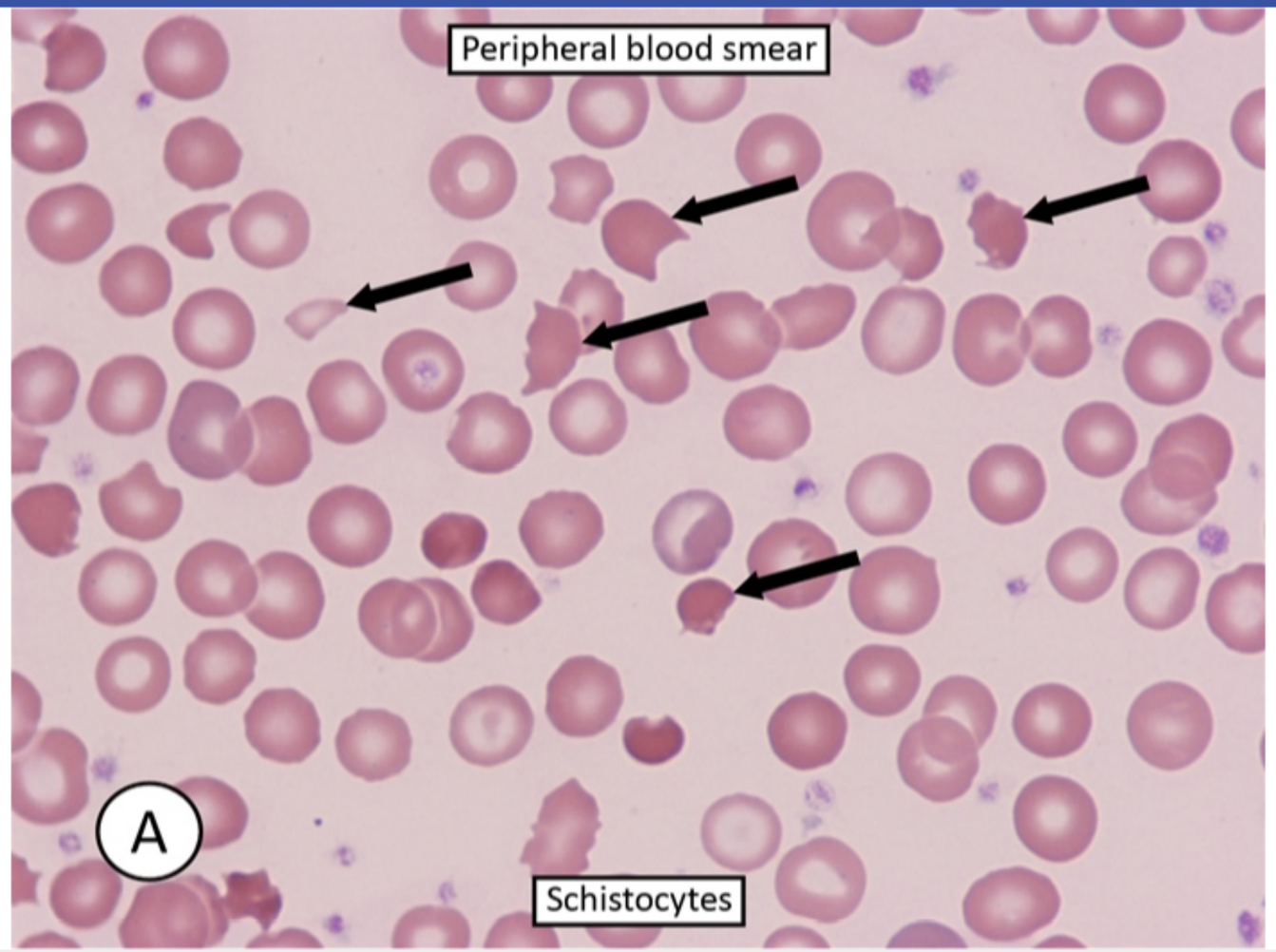

Zoom In | Zoom Out | Reset | Add To New Card | Existing Card

1
2
3
4
5
6
7
8
9
10
11
12
13
14
15
16
17
18
19
20
21
22
23
24
25
26
27
28
29
30
31

A 3-year-old boy is brought to the physician with jaundice and pallor. He was adopted and his family history is unknown. Laboratory studies show anemia, reticulocytosis, and increased indirect bilirubin. A peripheral blood smear shows red blood cells without central pallor. This patient is most likely to have which of the following additional findings?

A. Decreased lactate dehydrogenase

B. Increased haptoglobin

C. Increased mean corpuscular hemoglobin concentration

D. Increased mean corpuscular volume

E. Red blood cell inclusions

Submit

A 3-year-old boy is brought to the physician with jaundice and pallor. He was adopted and his family history is unknown. Laboratory studies show anemia, reticulocytosis, and increased indirect bilirubin. A peripheral blood smear shows red blood cells without central pallor. This patient is most likely to have which of the following additional findings?

A. Decreased lactate dehydrogenase (4%)

B. Increased haptoglobin (12%)

✓ C. Increased mean corpuscular hemoglobin concentration (59%)

D. Increased mean corpuscular volume (13%)

E. Red blood cell inclusions (10%)

Omitted
Correct answer
C

59%
Answered correctly

02 secs
Time Spent

05/22/2020
Last Updated

Explanation

This patient's anemia, reticulocytosis, and increased indirect bilirubin are indicative of hemolytic anemia. His peripheral blood smear shows red blood cells **without central pallor** (ie, spherocytes), which suggests acquired or hereditary **spherocytosis**. Hereditary spherocytosis is caused by defective binding of the red cell cytoskeleton to the plasma membrane due to mutations involving ankyrin, band 3, or spectrin proteins; acquired spherocytosis is most often caused by autoimmune hemolytic anemia. Compared to normal red blood cells, spherocytes are smaller and have a more intensely-staining cytoplasm due to membrane loss and red cell dehydration. The red cell index most specific for spherocytosis is an elevation in **mean corpuscular hemoglobin concentration (MCHC)**.

1
2
3
4
5
6
7
8
9
10
11
12
13
14
15
16
17
18
19
20
21
22
23
24
25
26
27
28
29
30
31

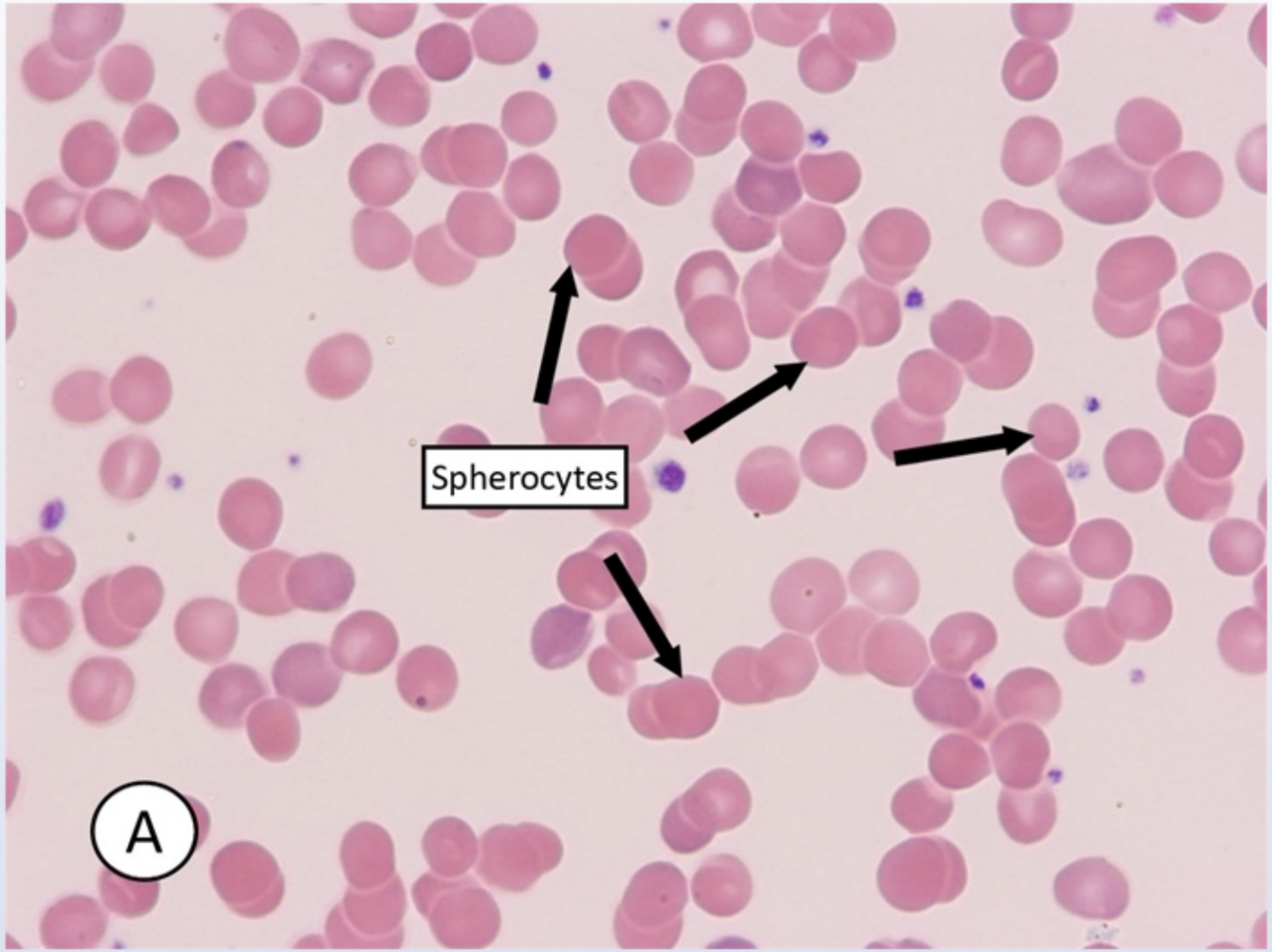

This patient's anemia, reticulocytosis, and increased indirect bilirubin are indicative of hemolytic anemia. His peripheral blood smear shows red blood cells **without central pallor** (ie, spherocytes), which suggests acquired or hereditary **spherocytosis**. Hereditary spherocytosis is caused by defective binding of the red cell cytoskeleton to the plasma membrane due to mutations involving ankyrin, band 3, or spectrin proteins; acquired

This patient's anemia, reticulocytosis, and increased indirect bilirubin are indicative of hemolytic anemia. His peripheral blood smear shows red blood cells **without central pallor** (ie, spherocytes), which suggests acquired or hereditary **spherocytosis**. Hereditary spherocytosis is caused by defective binding of the red cell cytoskeleton to the plasma membrane due to mutations involving ankyrin, band 3, or spectrin proteins; acquired spherocytosis is most often caused by autoimmune hemolytic anemia. Compared to normal red blood cells, spherocytes are smaller and have a more intensely-staining cytoplasm due to membrane loss and red cell dehydration. The red cell index most specific for spherocytosis is an elevation in **mean corpuscular hemoglobin concentration (MCHC)**.

(Choice A) Lactate dehydrogenase (LDH) is an enzyme present in red blood cells. LDH will be elevated in any cause of hemolytic anemia.

(Choice B) Haptoglobin is an acute phase reactant that combines with free hemoglobin in the circulation to preserve body iron stores and prevent tissue damage. Haptoglobin levels decrease in any form of hemolytic anemia (even with extravascular hemolysis, as some free hemoglobin will spill into the blood stream).

(Choice D) The mean corpuscular volume (MCV) is generally normal to low in hereditary spherocytosis.

(Choice E) Red blood cell inclusions, such as Howell-Jolly bodies (DNA) and Pappenheimer bodies (iron), are occasionally associated with hemolytic anemia but are more commonly associated with splenectomy and sideroblastic anemia, respectively.

Educational objective:
In spherocytosis, mean corpuscular hemoglobin concentration (MCHC) is increased due to mild dehydration of the red blood cell. Markers of hemolysis are often evident and include elevated lactate dehydrogenase, reticulocytosis, and decreased haptoglobin.

Pathophysiology	Hematology & Oncology	Hereditary spherocytosis
Subject	System	Topic

Copyright © UWorld. All rights reserved.

1
2
3
4
5
6
7
8
9
10
11
12
13
14
15
16
17
18
19
20
21
22
23
24
25
26
27
28
29
30
31

Exhibit Display

Hereditary spherocytosis	
Epidemiology	• Autosomal dominant inheritance (~75%) • Northern European descent
Clinical presentation	• Hemolytic anemia • Jaundice • Splenomegaly
Laboratory findings	• ↑ **Mean corpuscular hemoglobin concentration** • **Spherocytes** on peripheral smear • Negative Coombs test • ↑ Osmotic fragility on **acidified glycerol lysis test** • Abnormal **eosin-5-maleimide binding test**
Treatment	• Folic acid supplementation • Blood transfusions • Splenectomy
Complications	• Pigment gallstones • Aplastic crises from parvovirus B19 infection

©USMLEWorld, LLC

Zoom In | Zoom Out | Reset | Add To New Card | Existing Card

Exhibit Display

Causes of hemolysis	
Intravascular hemolysis	• Microangiopathic hemolytic anemia (eg, disseminated intravascular coagulation) • Transfusion reactions • Infections (eg, clostridial sepsis) • Paroxysmal nocturnal hemoglobinuria • Intravenous Rho(D) immune globulin infusion
Extravascular hemolysis	• Intrinsic RBC enzyme deficiencies (eg, G6PD) • Hemoglobinopathies (eg, sickle cell, thalassemia) • Membrane defects (eg, hereditary spherocytosis) • Hypersplenism, intravenous immunoglobulin infusion • Warm- or cold-agglutinin autoimmune hemolytic anemia (most cases) • Infections (eg, *Bartonella*, malaria)

© USMLEWorld, LLC

Zoom In | Zoom Out | Reset | Add To New Card | Existing Card

1
2
3
4
5
6
7
8
9
10
11
12
13
14
15
16
17
18
19
20
21
22
23
24
25
26
27
28
29
30
31

Exhibit Display

Patient with splenectomy

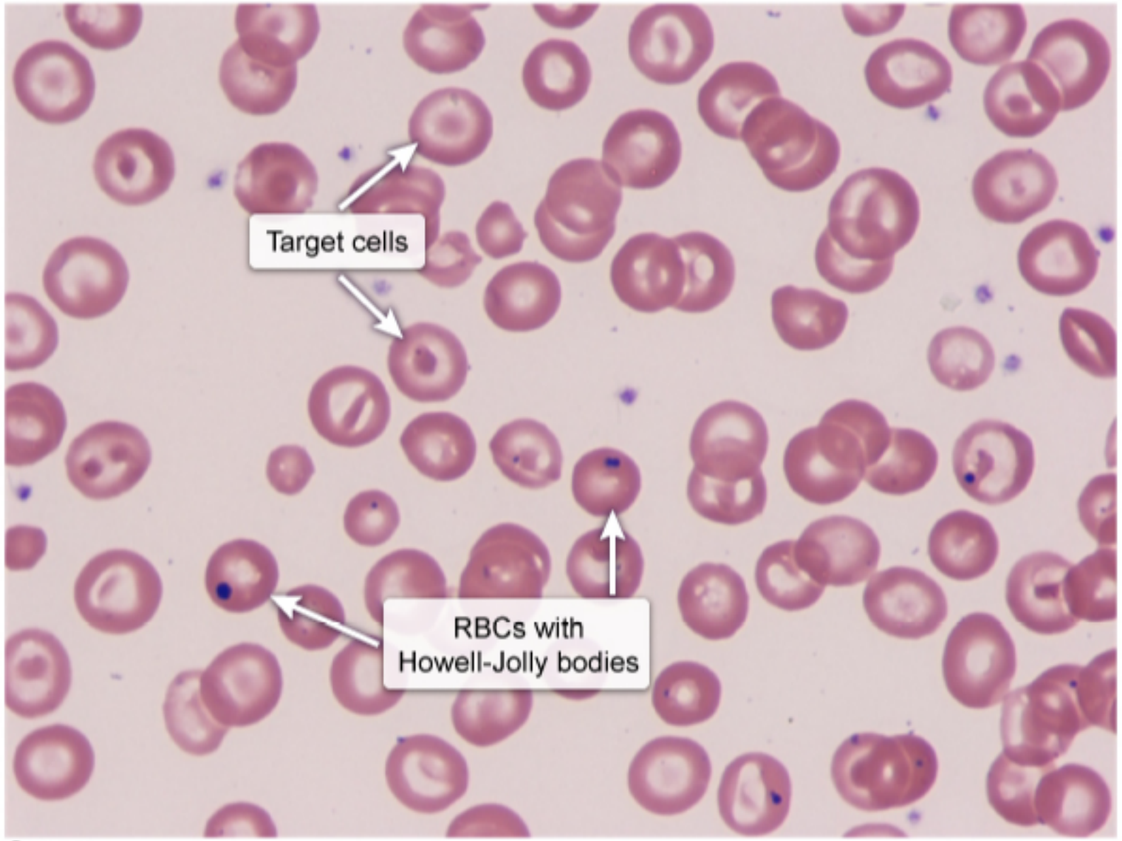

©UWorld

Zoom In | Zoom Out | Reset | Add To New Card | Existing Card

1
2
3
4
5
6
7
8
9
10
11
12
13
14
15
16
17
18
19
20
21
22
23
24
25
26
27
28
29
30
31

Exhibit Display

Patient with splenectomy

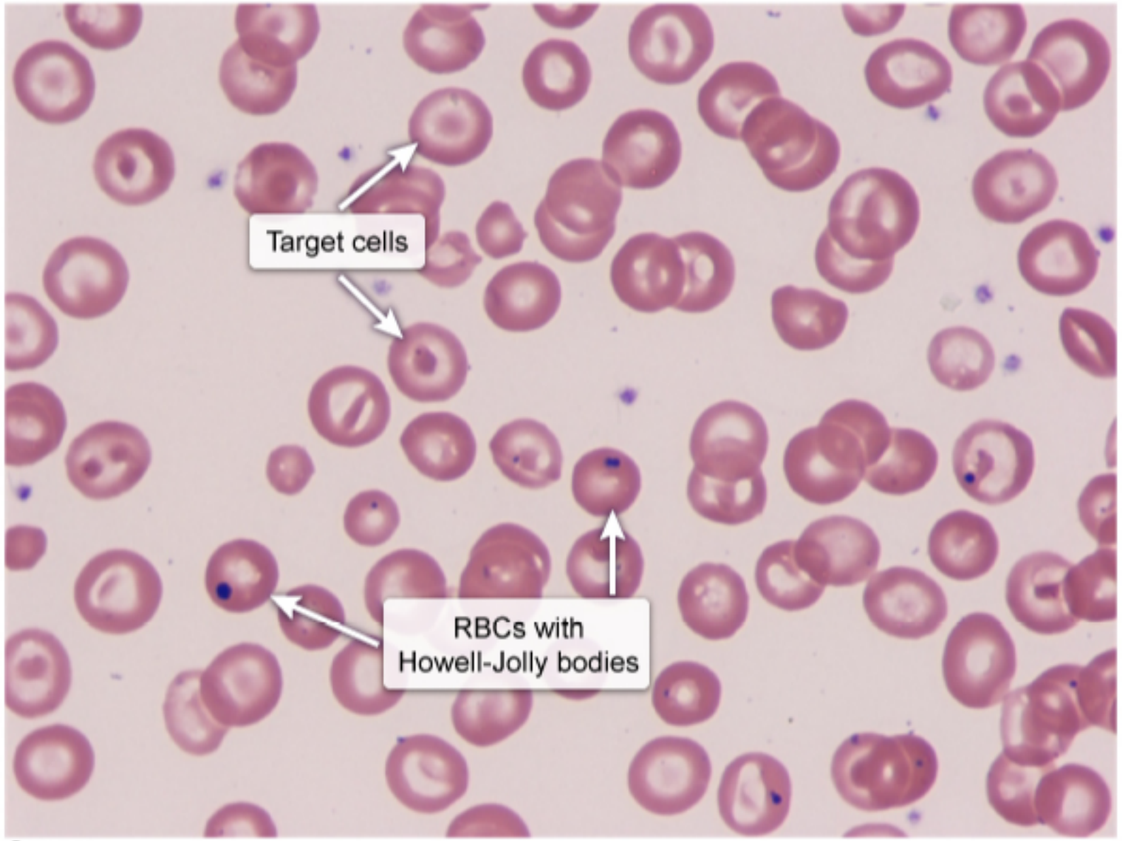

©UWorld

Zoom In | Zoom Out | Reset | Add To New Card | Existing Card

1
2
3
4
5
6
7
8
9
10
11
12
13
14
15
16
17
18
19
20
21
22
23
24
25
26
27
28
29
30
31

Exhibit Display

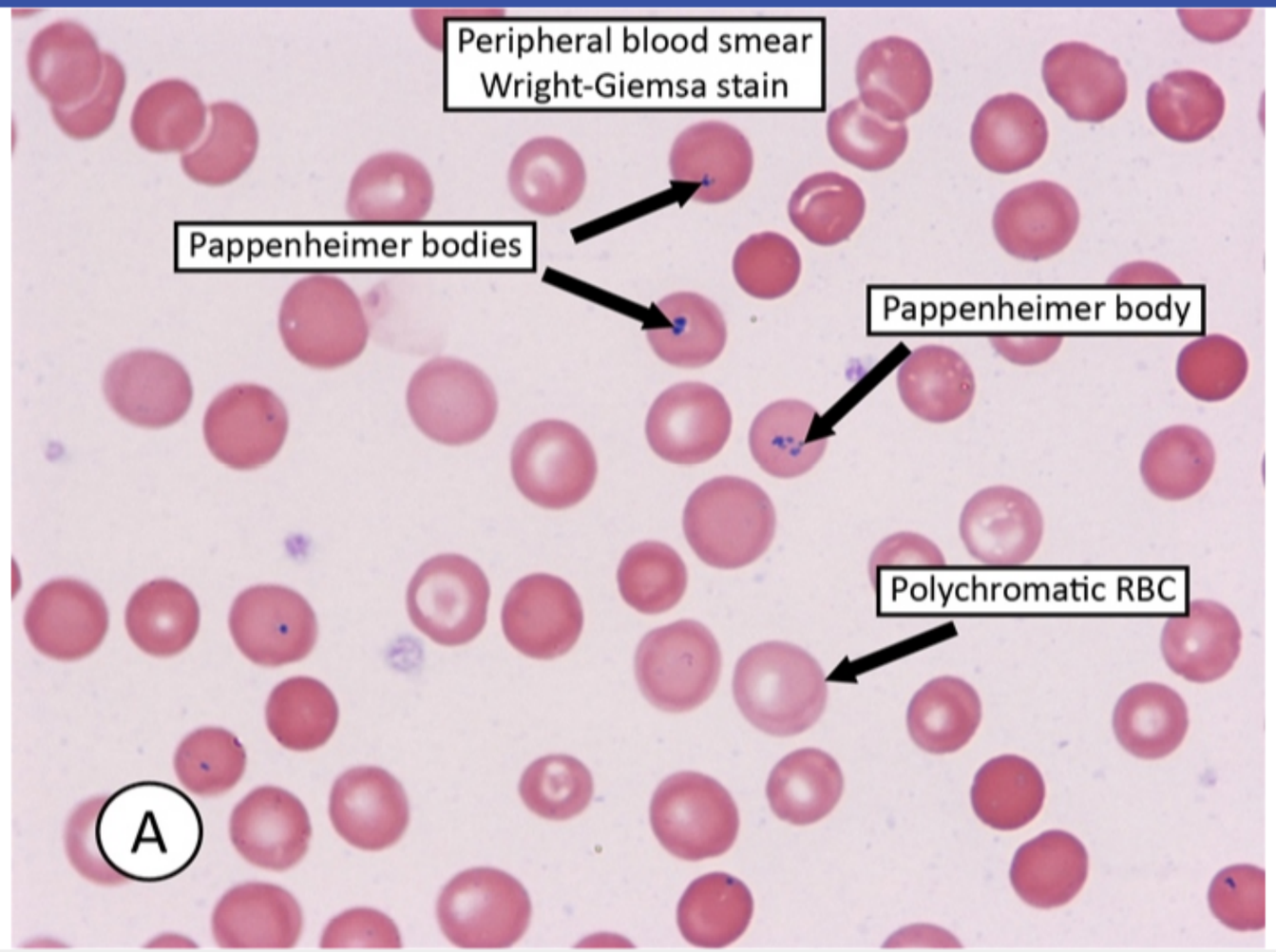

Zoom In | Zoom Out | Reset | Add To New Card | Existing Card

A 12-month-old boy is brought to the office by his father due to prolonged bleeding from mouth after slipping and hitting his face on a coffee table. He was born at term, and his mother died shortly after his birth due to bleeding complications following a home delivery. Vital signs are normal. He is awake and alert. There is blood oozing from his gums and marked bruises along his trunk and thighs. The remainder of the physical examination is normal. Laboratory evaluation shows decreased von Willebrand Factor antigen levels and activity, measured via the ristocetin cofactor assay. Which of the following sets of laboratory values is most likely present in this patient?

	Platelets	PT	PTT
A.	Decreased	Normal	Normal
B.	Decreased	Prolonged	Prolonged
C.	Normal	Normal	Prolonged
D.	Normal	Prolonged	Normal
E.	Normal	Prolonged	Prolonged

Submit

A 12-month-old boy is brought to the office by his father due to prolonged bleeding from mouth after slipping and hitting his face on a coffee table. He was born at term, and his mother died shortly after his birth due to bleeding complications following a home delivery. Vital signs are normal. He is awake and alert. There is blood oozing from his gums and marked bruises along his trunk and thighs. The remainder of the physical examination is normal. Laboratory evaluation shows decreased von Willebrand Factor antigen levels and activity, measured via the ristocetin cofactor assay. Which of the following sets of laboratory values is most likely present in this patient?

	Platelets	PT	PTT
A.	Decreased (8%)	Normal	Normal
B.	Decreased (3%)	Prolonged	Prolonged
✓ C.	Normal (72%)	Normal	Prolonged
D.	Normal (7%)	Prolonged	Normal
E.	Normal (7%)	Prolonged	Prolonged

Omitted
Correct answer
C

72%
Answered correctly

03 secs
Time Spent

06/30/2020
Last Updated

Explanation

Laboratory characteristics of coagulopathies				
	PT	**aPTT**	**Platelet count**	**Bleeding time**
Hemophilia A & B	Normal	↑	Normal	Normal
von Willebrand factor deficiency	Normal	Normal or ↑	Normal	↑
Disseminated intravascular coagulation	↑	↑	↓	↑
Uremic platelet dysfunction	Normal	Normal	Normal	↑
Heparin administration	Normal	↑	Normal (except in heparin-induced thrombocytopenia)	Normal
Warfarin use	↑	↑ (weak effect)	Normal	Normal
Immune thrombocytopenia	Normal	Normal	↓	↑

aPTT = activated partial thromboplastin time; PT = prothrombin time.

Von Willebrand disease (vWD) is caused by genetic mutations that lead to decreased quantity or impaired function of **von Willebrand factor** (vWF), a multimeric glycoprotein produced by platelets and endothelial cells. VWF has 2 important hemostatic functions:

1. It binds platelets to vascular subendothelial components at sites of injury (and platelets to each other), which results in the formation of hemostatic platelet plugs. Therefore, patients with VWD have impaired platelet aggregation but **normal platelet count** (as platelet consumption/production is unaffected).
2. VWF acts as a **carrier protein for factor VIII** and protects it from degradation. Because factor VIII is part of the intrinsic (contact activation)

Von Willebrand disease (vWD) is caused by genetic mutations that lead to decreased quantity or impaired function of **von Willebrand factor** (vWF), a multimeric glycoprotein produced by platelets and endothelial cells. VWF has 2 important hemostatic functions:

1. It binds platelets to vascular subendothelial components at sites of injury (and platelets to each other), which results in the formation of hemostatic platelet plugs. Therefore, patients with VWD have impaired platelet aggregation but **normal platelet count** (as platelet consumption/production is unaffected).
2. VWF acts as a **carrier protein for factor VIII** and protects it from degradation. Because factor VIII is part of the intrinsic (contact activation) coagulation pathway, patients with VWD sometimes have **prolonged PTT** (due to increased destruction of factor VIII), but **PT will be normal**.

VWD is typically transmitted in an autosomal dominant fashion so a **family history** of bleeding is often an important diagnostic clue. Most cases are asymptomatic, but a minority (~1%) have easy bruising, skin bleeding, and bleeding from mucous membranes (eg, oropharyngeal, gastrointestinal, uterine). Testing for vWF level and activity (eg, ristocetin cofactor assay) can help confirm the diagnosis.

(Choice A) Primary immune thrombocytopenia (ITP) is an autoimmune disease associated with immune-mediated platelet destruction. Although patients with ITP often have easy bleeding, VWF levels and activity are normal, and a family history of bleeding is uncommon (as ITP is an acquired disorder). ITP is marked by thrombocytopenia and normal PT/PTT.

(Choice B) Disseminated intravascular coagulation is caused by widespread activation of coagulation and fibrinolysis due to sepsis, malignancy, trauma, or obstetric complication. It is an acquired disorder, so a family history of bleeding is uncommon. Disseminated intravascular coagulation is associated with low platelets and elevated PT and PTT.

(Choice D) Vitamin K deficiency and warfarin use impair synthesis of vitamin K–dependent clotting factors (II, VII, IX, and X), which leads to prolonged PT and normal platelet count and PTT (PTT can sometimes be mildly elevated). Although vitamin K deficiency is common in newborns, it is very uncommon in otherwise healthy children and adults. In addition, the family history of bleeding disorder makes this much less likely than vWD.

(Choice E) Patients with severe liver disease often have impaired hepatic synthetic function and are unable to generate sufficient quantities of clotting factors. Therefore, they often have elevated PT and PTT (with normal or low platelets). This otherwise healthy boy is unlikely to have significant liver disease.

Von Willebrand disease (vWD) is caused by genetic mutations that lead to decreased quantity or impaired function of **von Willebrand factor**

Exhibit Display

Platelet adhesion & activation via vWF

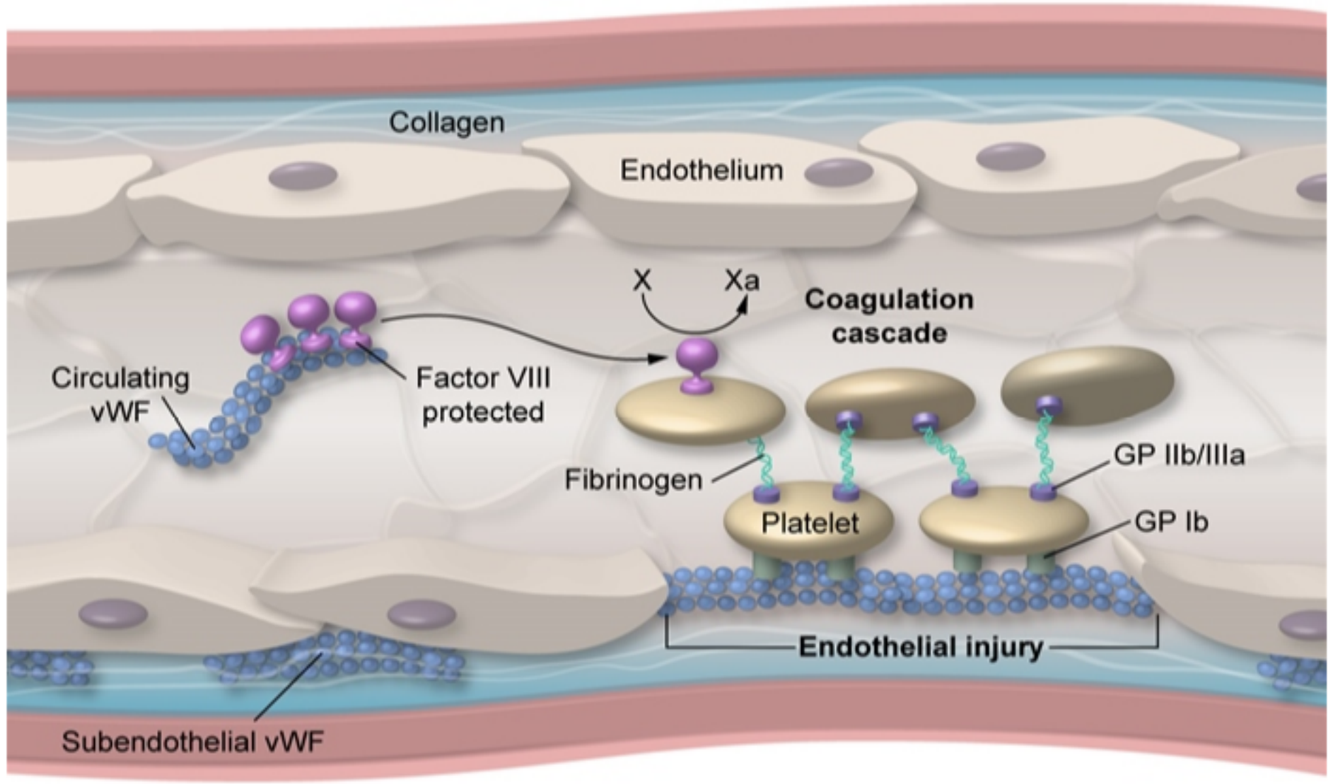

GP = glycoprotein; **vWF** = von Willebrand factor.

©UWorld

Zoom In | Zoom Out | Reset | Add To New Card | Existing Card

Von Willebrand disease (vWD) is caused by genetic mutations that lead to decreased quantity or impaired function of **von Willebrand factor**

Exhibit Display

Platelet adhesion & activation via vWF

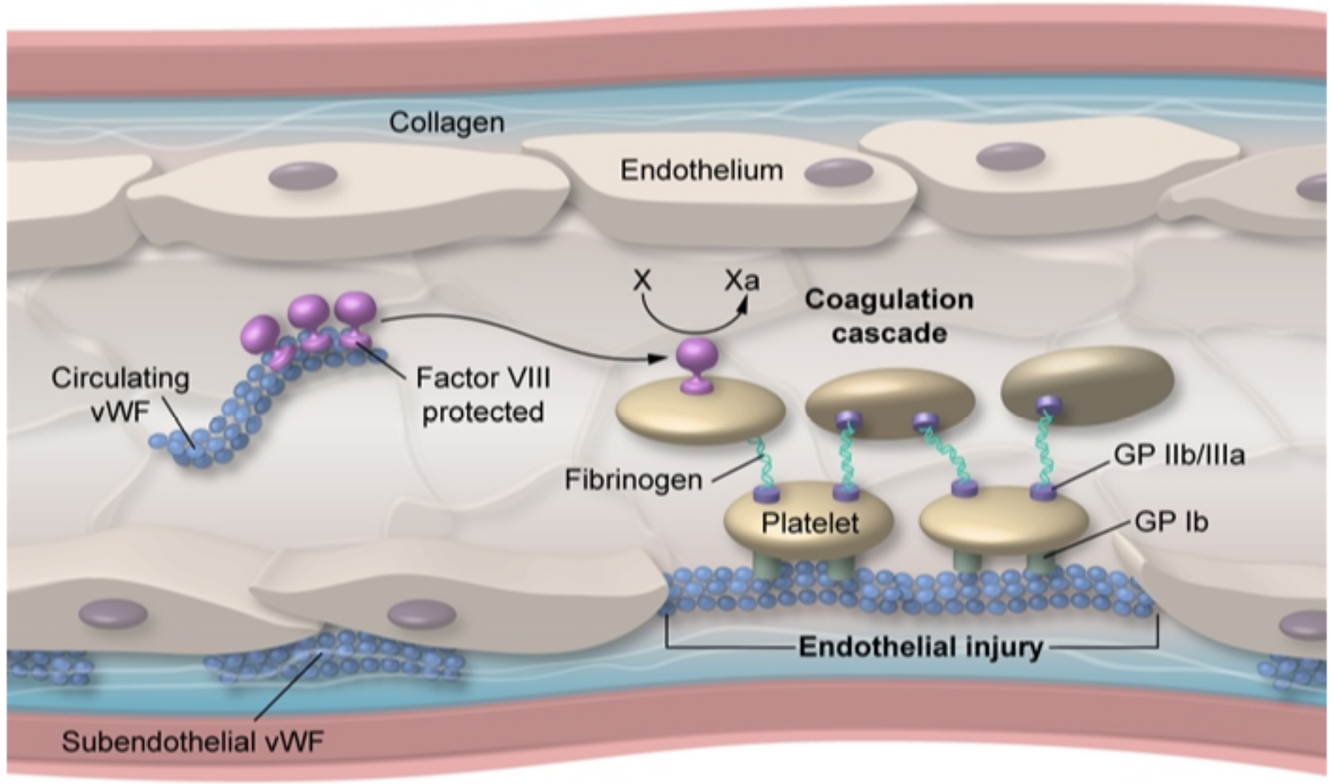

GP = glycoprotein; **vWF** = von Willebrand factor.

©UWorld

Zoom In | Zoom Out | Reset | Add To New Card | Existing Card

1 2 3 4 5 6 7 8 9 10 11 12 13 14 15 16 17 18 19 20 21 22 23 24 25 26 27 28 29 30 31

VWD is typically transmitted in an autosomal dominant fashion so a **family history** of bleeding is often an important diagnostic clue. Most cases are asymptomatic, but a minority (~1%) have easy bruising, skin bleeding, and bleeding from mucous membranes (eg, oropharyngeal, gastrointestinal, uterine). Testing for vWF level and activity (eg, ristocetin cofactor assay) can help confirm the diagnosis.

(Choice A) Primary immune thrombocytopenia (ITP) is an autoimmune disease associated with immune-mediated platelet destruction. Although patients with ITP often have easy bleeding, VWF levels and activity are normal, and a family history of bleeding is uncommon (as ITP is an acquired disorder). ITP is marked by thrombocytopenia and normal PT/PTT.

(Choice B) Disseminated intravascular coagulation is caused by widespread activation of coagulation and fibrinolysis due to sepsis, malignancy, trauma, or obstetric complication. It is an acquired disorder, so a family history of bleeding is uncommon. Disseminated intravascular coagulation is associated with low platelets and elevated PT and PTT.

(Choice D) Vitamin K deficiency and warfarin use impair synthesis of vitamin K–dependent clotting factors (II, VII, IX, and X), which leads to prolonged PT and normal platelet count and PTT (PTT can sometimes be mildly elevated). Although vitamin K deficiency is common in newborns, it is very uncommon in otherwise healthy children and adults. In addition, the family history of bleeding disorder makes this much less likely than vWD.

(Choice E) Patients with severe liver disease often have impaired hepatic synthetic function and are unable to generate sufficient quantities of clotting factors. Therefore, they often have elevated PT and PTT (with normal or low platelets). This otherwise healthy boy is unlikely to have significant liver disease.

Educational objective:
Von Willebrand disease is the most common inherited bleeding disorder and is usually transmitted in an autosomal dominant fashion. Symptomatic patients typically present with easy bruising and mucosal bleeding. Laboratory evaluation will show normal platelets, normal PT, and either normal or prolonged PTT due to low levels of factor VIII.

Pathophysiology	Hematology & Oncology	Von willebrand disease
Subject	System	Topic

Copyright © UWorld. All rights reserved.

1
2
3
4
5
6
7
8
9
10
11
12
13
14
15
16
17
18
19
20
21
22
23
24
25
26
27
28
29
30
31

A 64-year-old man is evaluated for a 1-month history of worsening fatigue and low back pain exacerbated by movement. He has no prior medical history and takes no medications. Vital signs are normal. Physical examination shows mucosal pallor and bony tenderness. Radiographs reveal lytic bone lesions. Laboratory studies show that hemoglobin is 8.8 g/dL, serum creatinine is 3.0 g/dL, and serum calcium is 10.8 g/dL. Urine dipstick is negative for protein, but quantitative measurement reveals elevated 24-hour urinary protein excretion. Urine electrophoresis is most likely to detect which of the following?

A. Gamma heavy chains

B. Immunoglobulin A

C. Immunoglobulin G

D. Immunoglobulin M

E. Lambda light chains

Submit

A 64-year-old man is evaluated for a 1-month history of worsening fatigue and low back pain exacerbated by movement. He has no prior medical history and takes no medications. Vital signs are normal. Physical examination shows mucosal pallor and bony tenderness. Radiographs reveal lytic bone lesions. Laboratory studies show that hemoglobin is 8.8 g/dL, serum creatinine is 3.0 g/dL, and serum calcium is 10.8 g/dL. Urine dipstick is negative for protein, but quantitative measurement reveals elevated 24-hour urinary protein excretion. Urine electrophoresis is most likely to detect which of the following?

A. Gamma heavy chains (8%)
B. Immunoglobulin A (1%)
C. Immunoglobulin G (19%)
D. Immunoglobulin M (13%)
✓ E. Lambda light chains (58%)

Omitted
Correct answer
E

58%
Answered correctly

01 sec
Time Spent

06/01/2020
Last Updated

Explanation

Multiple myeloma (MM) is a lymphoproliferative malignancy characterized by monoclonal plasma cell proliferation and production of monoclonal paraproteins (eg, immunoglobulins, chain fragments). MM should be suspected in elderly patients who have any combination of osteolytic lesions, hypercalcemia, anemia, or acute kidney injury (such as this patient). Other common symptoms include weight loss, constipation (due to hypercalcemia), fatigue, and recurrent infection.

Kidney disease in MM is largely due to **light chain cast nephropathy** (myeloma kidney). Intact immunoglobulins (eg, IgA, IgG, IgM) are too large

Multiple myeloma (MM) is a lymphoproliferative malignancy characterized by monoclonal plasma cell proliferation and production of monoclonal paraproteins (eg, immunoglobulins, chain fragments). MM should be suspected in elderly patients who have any combination of osteolytic lesions, hypercalcemia, anemia, or acute kidney injury (such as this patient). Other common symptoms include weight loss, constipation (due to hypercalcemia), fatigue, and recurrent infection.

Kidney disease in MM is largely due to **light chain cast nephropathy** (myeloma kidney). Intact immunoglobulins (eg, IgA, IgG, IgM) are too large to pass through the glomerulus, but a small amount of free light chains (eg, kappa, lambda) are freely filtered and resorbed in the proximal tubules. However in MM, the excessive quantities of free light chains exceed the resorptive capacity of the kidney. The filtered light chains then combine with Tamm-Horsfall proteins to form **obstructive casts** that cause tubular rupture and kidney injury.

Monoclonal paraproteins are **not detected by urine dipstick** (which detects only albumin), but **quantitative protein concentrations** (spot or 24-hour turbidimetric assay) will be elevated. Urine protein electrophoresis, immunofixation, or free light chain immunoassays can be used for diagnosis.

(Choices A, B, C, and D) MM can occasionally cause monoclonal immunoglobulin deposition disease, in which intact immunoglobulins or heavy and/or light chains deposit on the kidney basement membranes, resulting in glomerular disease and nephrotic syndrome. In this case, large intact immunoglobulins (and heavy chains) can enter the urine; however, albumin (which also passes through the injured glomerulus) would be detected on urine dipstick.

Educational objective:
Multiple myeloma should be suspected in elderly patients who have any combination of osteolytic lesions, hypercalcemia, anemia, or acute kidney injury. Renal disease is most commonly caused by light chain cast nephropathy, in which free light chains form obstructive casts in the renal tubules. Monoclonal paraproteins are not detected by urine dipstick (which detects only albumin), but both spot and 24-hour protein concentrations will be elevated.

Pathophysiology	Hematology & Oncology	Multiple myeloma
Subject	System	Topic

Copyright © UWorld. All rights reserved.

1
2
3
4
5
6
7
8
9
10
11
12
13
14
15
16
17
18
19
20
21
22
23
24
25
26
27
28
29
30
31

A 32-year-old woman comes to the office due to worsening fatigue and exercise intolerance. She has no history of blood disorders. Physical examination shows mild mucosal pallor. Hemoglobin is 7.8 g/dL. Peripheral blood smear is shown in the image below.

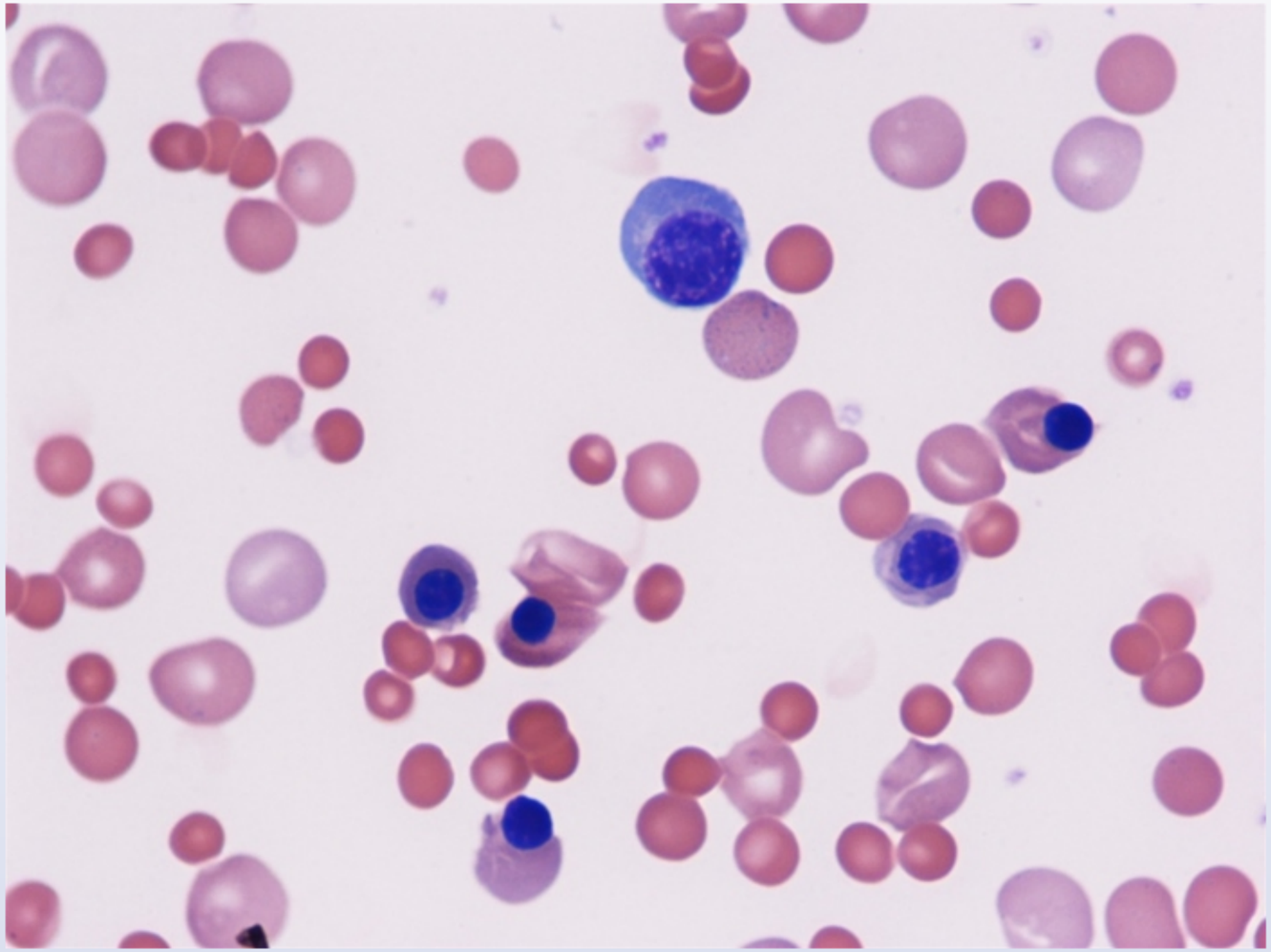

Which of the following is the most likely cause of this patient's anemia?

1
2
3
4
5
6
7
8
9
10
11
12
13
14
15
16
17
18
19
20
21
22
23
24
25
26
27
28
29
30
31

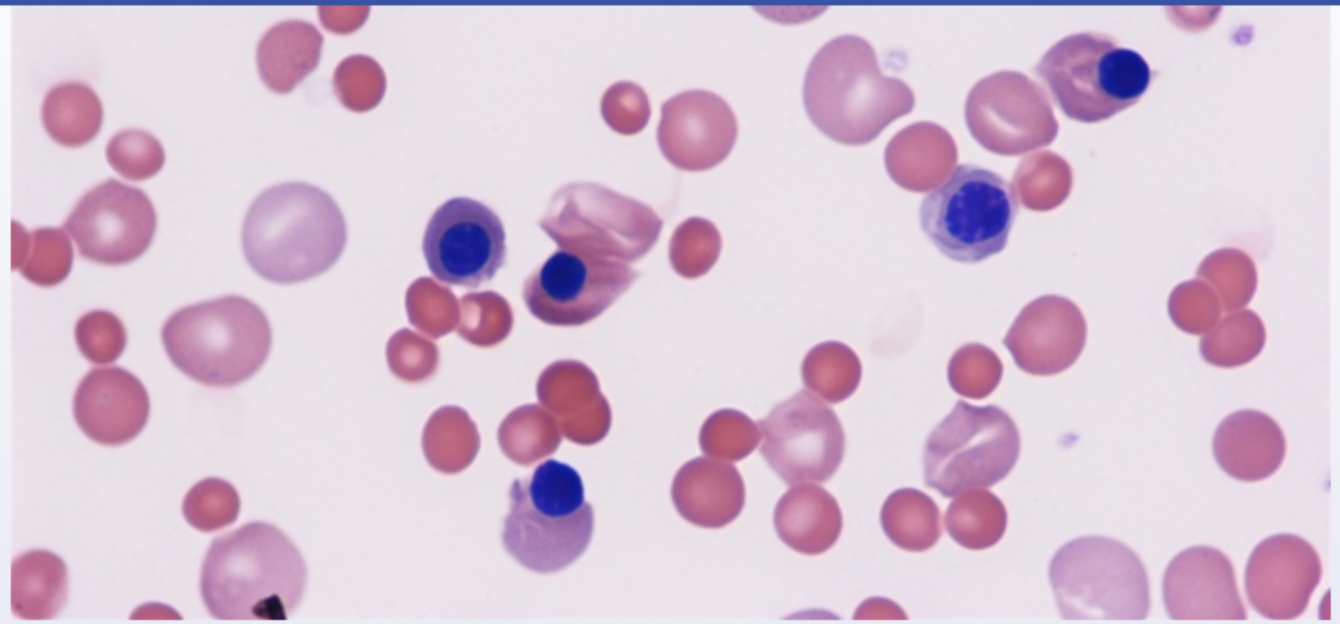

Which of the following is the most likely cause of this patient's anemia?

A. Erythropoietin deficiency

B. Hemolytic anemia

C. Iron deficiency anemia

D. Thrombotic microangiopathy

E. Vitamin B_{12} deficiency

Submit

1
2
3
4
5
6
7
8
9
10
11
12
13
14
15
16
17
18
19
20
21
22
23
24
25
26
27
28
29
30
31

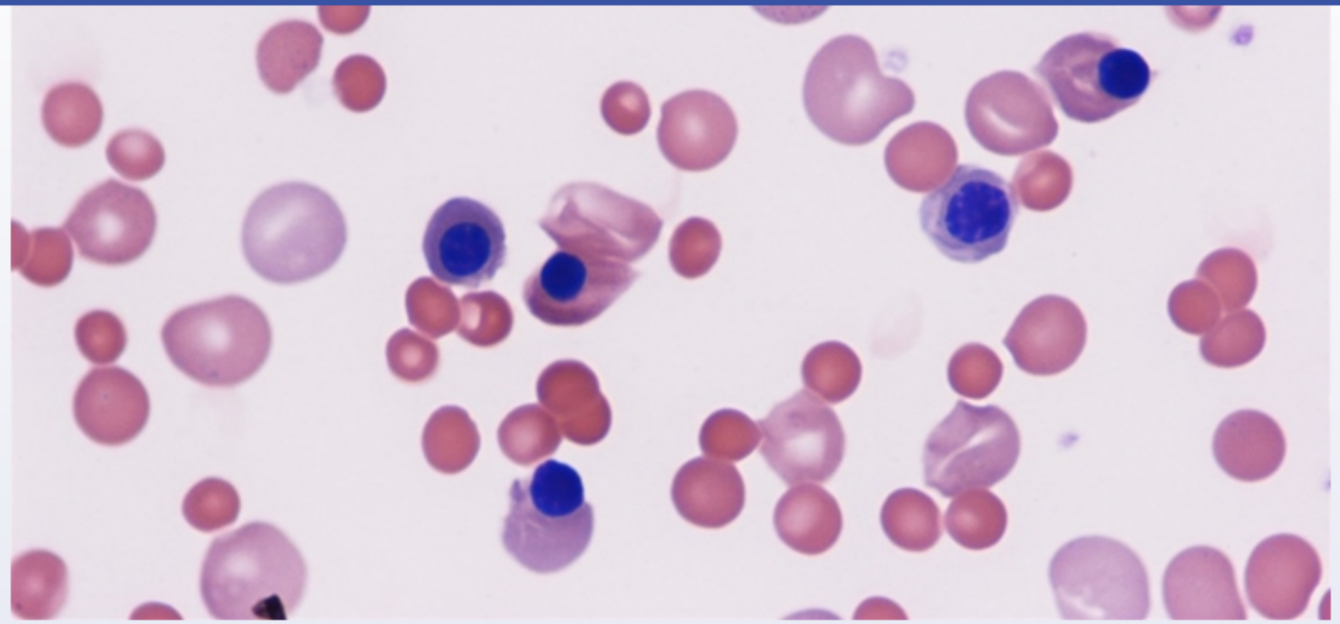

Which of the following is the most likely cause of this patient's anemia?

A. Erythropoietin deficiency (8%)

✓ B. Hemolytic anemia (40%)

C. Iron deficiency anemia (33%)

D. Thrombotic microangiopathy (5%)

E. Vitamin B_{12} deficiency (13%)

Omitted
Correct answer

40%
Answered correctly

06 secs
Time Spent

05/14/2020
Last Updated

1
2
3
4
5
6
7
8
9
10
11
12
13
14
15
16
17
18
19
20
21
22
23
24
25
26
27
28
29
30
31

Peripheral blood smear

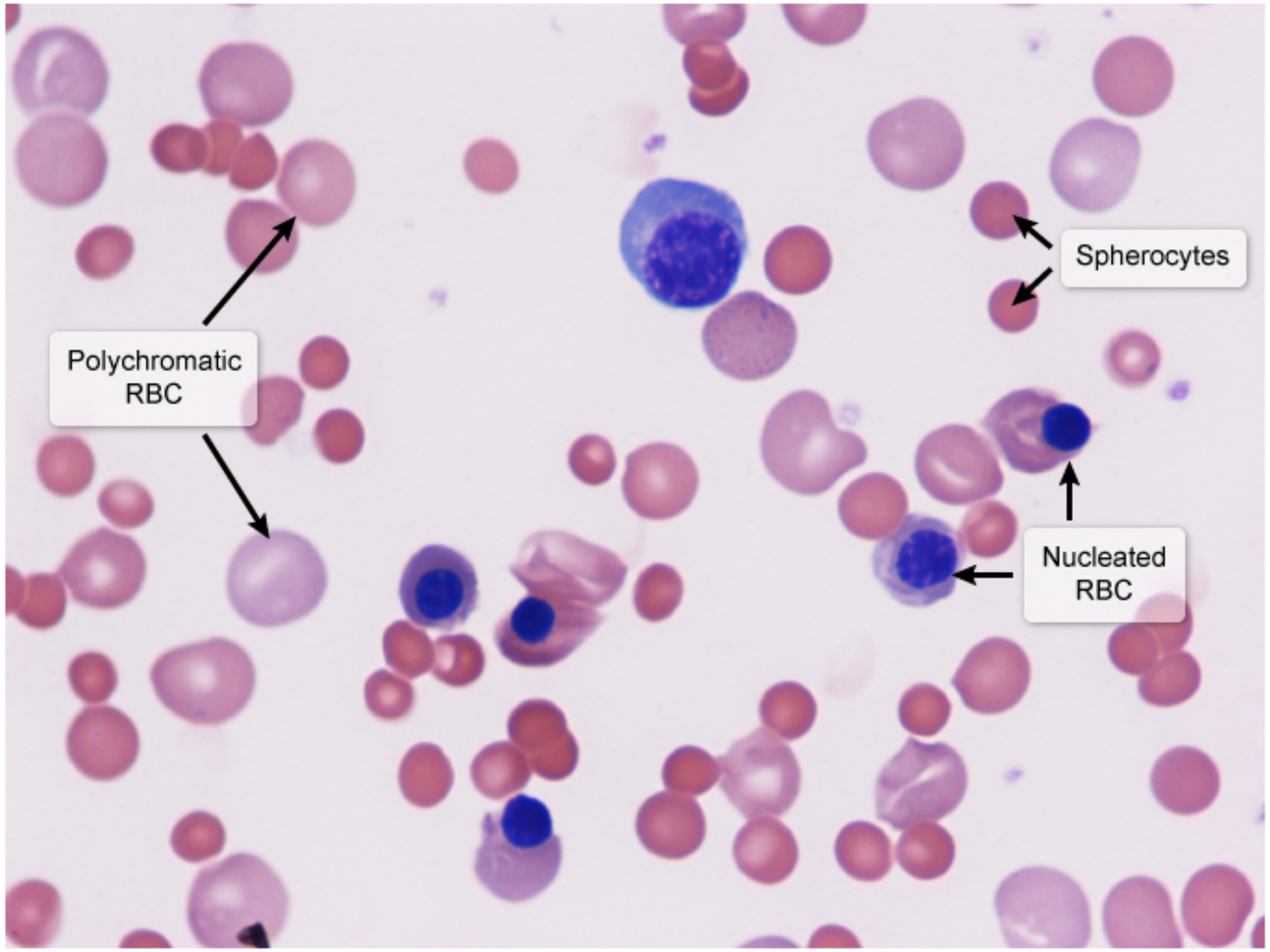

©UWorld

This patient with **symptomatic anemia** (eg, fatigue, exercise intolerance) has peripheral blood smear findings that indicate **hemolytic anemia**, including the following:

This patient with **symptomatic anemia** (eg, fatigue, exercise intolerance) has peripheral blood smear findings that indicate **hemolytic anemia**, including the following:

- **Increased reticulocytes:** Reticulocytes are larger than mature red blood cells (RBCs), lack central pallor, and have a bluish coloration (**polychromatic RBCs**) due to the presence of ribosomes, which are not found in mature RBCs. Increased reticulocytes in the peripheral blood is a nonspecific finding that indicates the bone marrow is responding appropriately to anemia by increasing production of new erythrocytes.
- **Spherocytes:** Spherocytes are erythrocytes with reduced cell membrane, which makes the cell spherical rather than biconcave. In otherwise healthy individuals, spherocytes generally arise in the setting of **immune-mediated** hemolytic anemia; in this condition, IgG-coated erythrocytes are partially phagocytized by splenic macrophages, which reduces the surface area of the erythrocyte cell membrane, thereby causing the erythrocyte to assume a spherical shape.
- **Nucleated erythrocytes:** Nucleated erythrocytes are very immature RBCs. The presence of nucleated RBCs in the peripheral blood indicates a strong bone marrow response to compensate for the anemia.

(Choice A) Anemia due to erythropoietin deficiency is often seen in patients with end-stage renal disease because erythropoietin production by the kidneys is impaired. Individuals with erythropoietin deficiency are not able to sufficiently increase erythrocytosis in response to anemia; therefore, peripheral blood smear does not typically show increased reticulocytes or nucleated RBCs.

(Choice C) Iron deficiency anemia can be seen in young women with heavy menstruation or gastrointestinal bleeding. However, peripheral blood smear typically shows hypochromatic RBCs and microcytosis.

(Choice D) Thrombotic microangiopathy is associated with microvascular clot formation, which causes anemia via RBC shearing. In this condition, peripheral blood smear typically shows schistocytes, not spherocytes.

(Choice E) Vitamin B_{12} deficiency is common in patients with atrophic gastritis and alcoholism. It commonly causes macrocytic anemia with hypersegmented neutrophils on peripheral blood smear.

Educational objective:
In patients with hemolytic anemia, peripheral blood smear usually reveals evidence of reticulocytosis, spherocytes, and nucleated red blood cells.

blood is a nonspecific finding that indicates the bone marrow is responding appropriately to anemia by increasing production of new erythrocytes.

- **Spherocytes:** Spherocytes are erythrocytes with reduced cell membrane, which makes the cell spherical rather than biconcave. In otherwise healthy individuals, spherocytes generally arise in the setting of **immune-mediated** hemolytic anemia; in this condition, IgG-coated erythrocytes are partially phagocytized by splenic macrophages, which reduces the surface area of the erythrocyte cell membrane, thereby causing the erythrocyte to assume a spherical shape.
- **Nucleated erythrocytes:** Nucleated erythrocytes are very immature RBCs. The presence of nucleated RBCs in the peripheral blood indicates a strong bone marrow response to compensate for the anemia.

(Choice A) Anemia due to erythropoietin deficiency is often seen in patients with end-stage renal disease because erythropoietin production by the kidneys is impaired. Individuals with erythropoietin deficiency are not able to sufficiently increase erythrocytosis in response to anemia; therefore, peripheral blood smear does not typically show increased reticulocytes or nucleated RBCs.

(Choice C) Iron deficiency anemia can be seen in young women with heavy menstruation or gastrointestinal bleeding. However, peripheral blood smear typically shows hypochromatic RBCs and microcytosis.

(Choice D) Thrombotic microangiopathy is associated with microvascular clot formation, which causes anemia via RBC shearing. In this condition, peripheral blood smear typically shows schistocytes, not spherocytes.

(Choice E) Vitamin B_{12} deficiency is common in patients with atrophic gastritis and alcoholism. It commonly causes macrocytic anemia with hypersegmented neutrophils on peripheral blood smear.

Educational objective:
In patients with hemolytic anemia, peripheral blood smear usually reveals evidence of reticulocytosis, spherocytes, and nucleated red blood cells.

Pathophysiology	Hematology & Oncology	Hemolytic anemia
Subject	System	Topic

Copyright © UWorld. All rights reserved.

blood is a nonspecific finding that indicates the bone marrow is responding appropriately to anemia by increasing production of new

Exhibit Display

Iron deficiency anemia

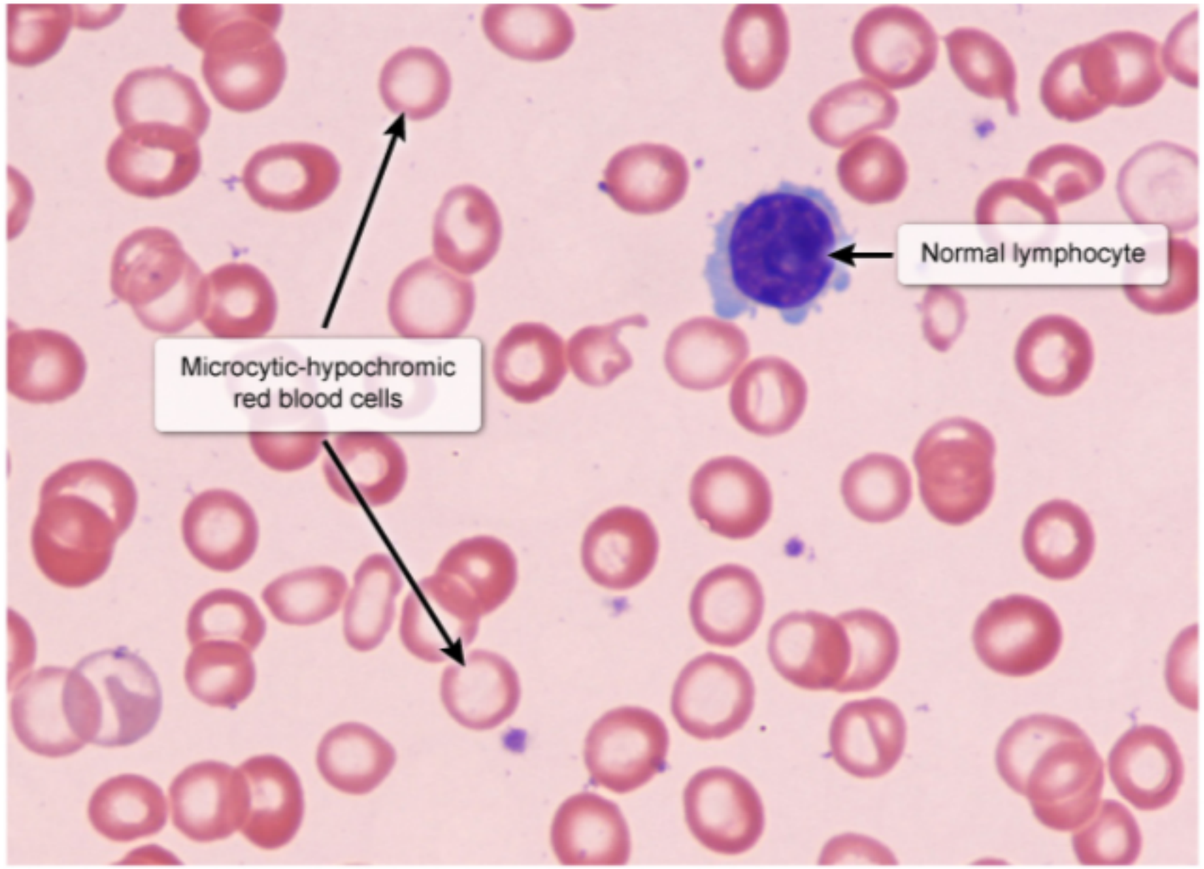

Zoom In
Zoom Out
Reset
Add To Flash Card

blood is a nonspecific finding that indicates the bone marrow is responding appropriately to anemia by increasing production of new

Exhibit Display

Zoom In
Zoom Out
Reset
Add To Flash Card

blood is a nonspecific finding that indicates the bone marrow is responding appropriately to anemia by increasing production of new

Exhibit Display

Microangiopathic hemolytic anemia

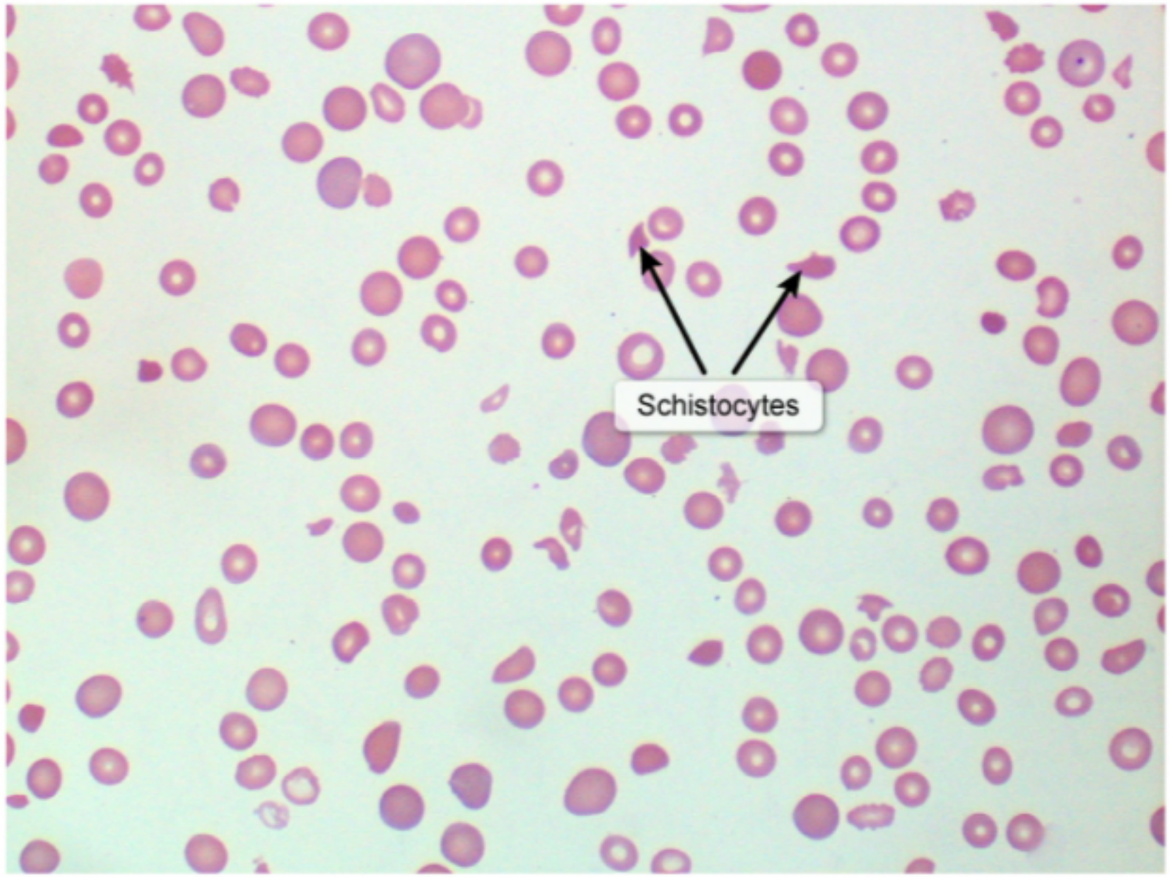

©UWorld

Zoom In Zoom Out Reset Add To Flash Card

blood is a nonspecific finding that indicates the bone marrow is responding appropriately to anemia by increasing production of new

Exhibit Display

Megaloblastic anemia

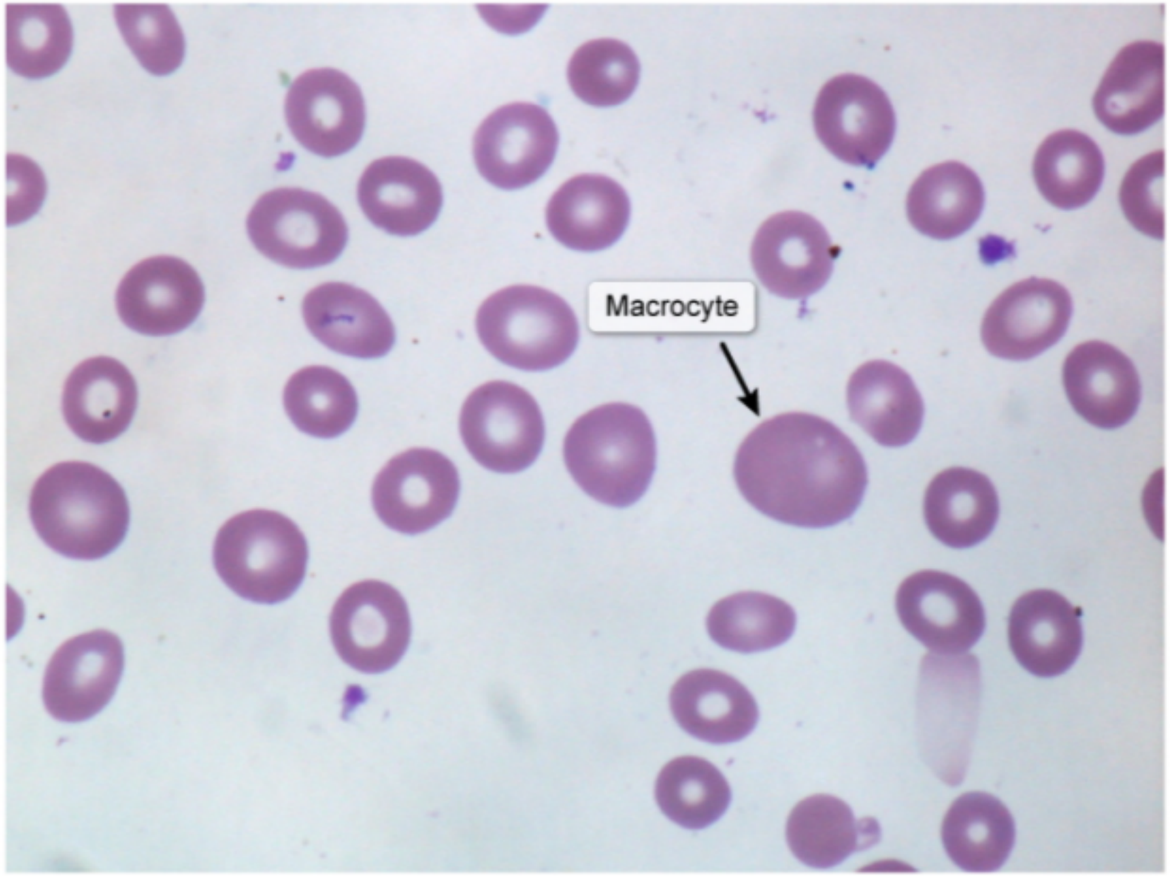

©UWorld

Zoom In Zoom Out Reset Add To Flash Card

1
2
3
4
5
6
7
8
9
10
11
12
13
14
15
16
17
18
19
20
21
22
23
24
25
26
27
28
29
30
31

A 12-year-old boy experiences excessive bleeding following a tooth extraction. His past medical history includes episodes of painful joint swelling from minor trauma. Physical examination shows a soft and nontender abdomen with a liver span of 10 cm. The spleen is not palpable. Laboratory results are as follows:

Bleeding time	5 min
Activated partial thromboplastin time	25 sec
Prothrombin time	23 sec

This patient most likely has a deficiency involving which of the following factors?

A. Factor VII
B. Factor VIII
C. Factor XI
D. Hageman factor
E. von Willebrand factor

Submit

A 12-year-old boy experiences excessive bleeding following a tooth extraction. His past medical history includes episodes of painful joint swelling from minor trauma. Physical examination shows a soft and nontender abdomen with a liver span of 10 cm. The spleen is not palpable. Laboratory results are as follows:

Bleeding time	5 min
Activated partial thromboplastin time	25 sec
Prothrombin time	23 sec

This patient most likely has a deficiency involving which of the following factors?

- ✓ A. Factor VII (59%)
- B. Factor VIII (22%)
- C. Factor XI (2%)
- D. Hageman factor (2%)
- E. von Willebrand factor (13%)

Omitted
Correct answer
A

59%
Answered correctly

03 secs
Time Spent

03/05/2020
Last Updated

Explanation

1
2
3
4
5
6
7
8
9
10
11
12
13
14
15
16
17
18
19
20
21
22
23
24
25
26
27
28
29
30
31

Coagulation cascade pathway

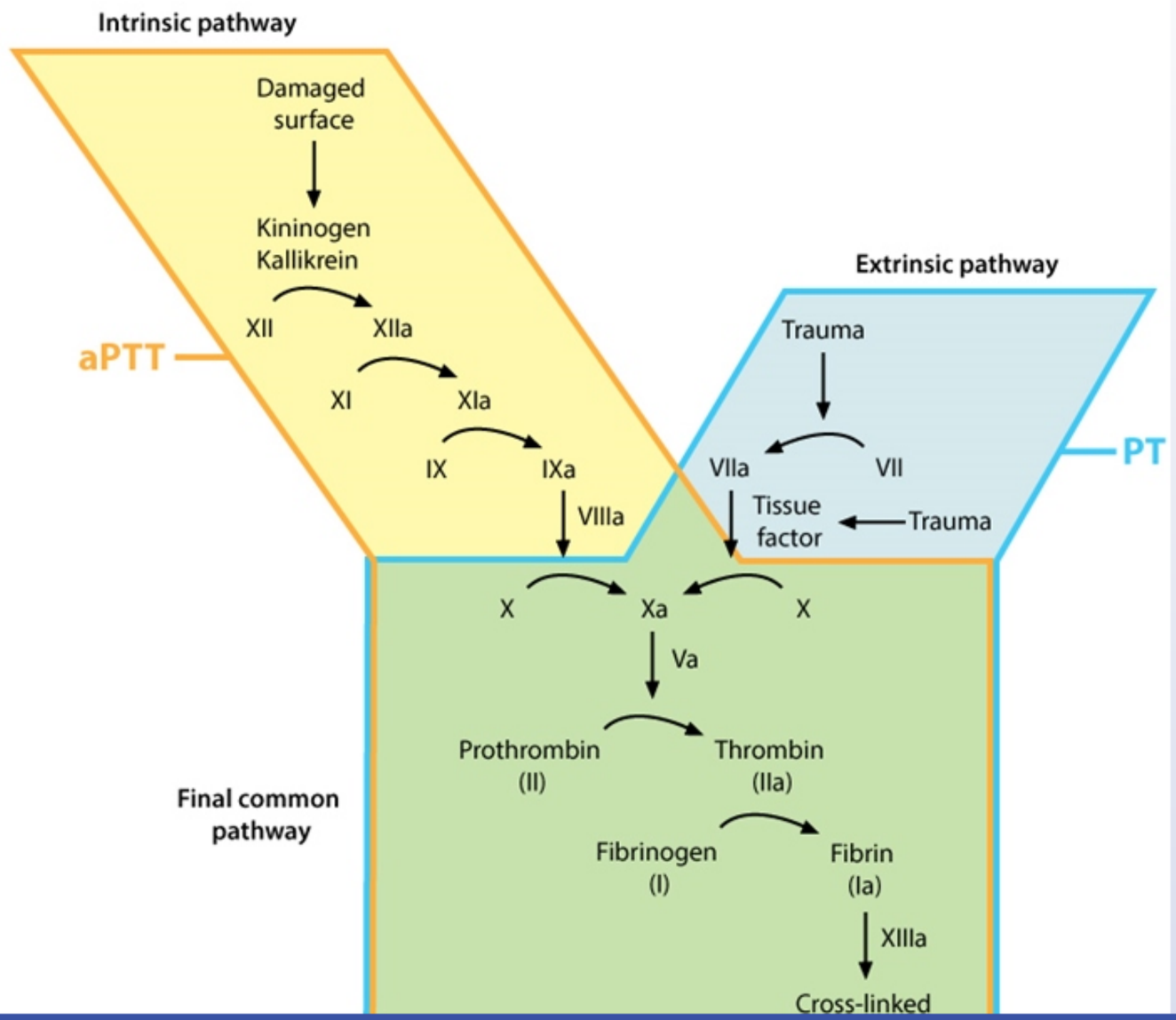

aPTT = activated partial thromboplastin time; **PT** = prothrombin time.

This patient's hemarthroses and excessive bleeding following tooth extraction are suggestive of a coagulopathy (ie, clotting factor deficiency). **Coagulopathies** generally present with **deep-tissue bleeding** into joints, muscles, and subcutaneous tissue. In contrast, **platelet defects** typically manifest with **mucocutaneous bleeding** (eg, epistaxis, petechiae). The patient's laboratory results show a normal bleeding time, normal activated partial thromboplastin time (aPTT), and a prolonged prothrombin time (PT). The normal bleeding time indicates adequate platelet function, and the normal aPTT indicates an intact intrinsic coagulation system. However, the **prolonged PT** indicates a defect in the **extrinsic** coagulation pathway. Therefore, the patient is most likely deficient in factor VII.

(Choice B) Factor VIII deficiency results in classic X-linked hemophilia A. Coagulation studies will show a normal bleeding time, normal PT, and prolonged aPTT.

(Choice C) Factor XI deficiency results in a rare autosomal recessive disorder called hemophilia C. Spontaneous bleeding is rare in this condition, but affected patients are at increased risk for bleeding following surgery or trauma. Coagulation studies will show a prolonged aPTT and normal PT.

(Choice D) Hageman factor (factor XII) deficiency is an autosomal recessive disorder that does not typically cause clinically significant bleeding despite aPTT prolongation.

(Choice E) von Willebrand factor (vWF) functions as both a carrier molecule for factor VIII (protecting it from being degraded) and as a mediator of platelet adhesion to the endothelium. It presents with prolonged bleeding time and normal/prolonged aPTT.

Educational objective:
A normal bleeding time indicates adequate platelet hemostatic function. A normal activated partial thromboplastin time (aPTT) indicates an intact intrinsic coagulation system. Prolonged prothrombin time in the setting of normal aPTT indicates a defect in the extrinsic coagulation system at a step that is not shared with the intrinsic system.

Pathophysiology	Hematology & Oncology	Coagulopathy
Subject	System	Topic

Copyright © UWorld. All rights reserved.

1
2
3
4
5
6
7
8
9
10
11
12
13
14
15
16
17
18
19
20
21
22
23
24
25
26
27
28
29
30
31

A 50-year-old man comes to the emergency department due to a large, painful skin lesion. He does not remember sustaining any trauma. He was recently diagnosed with atrial fibrillation, for which warfarin was begun. The patient noticed the lesion about 36 hours after starting the medication. Temperature is 36.7 C (98 F), blood pressure is 130/82 mm Hg, and pulse is 88/min and irregularly irregular. Physical examination findings are shown in the image below.

1
2
3
4
5
6
7
8
9
10
11
12
13
14
15
16
17
18
19
20
21
22
23
24
25
26
27
28
29
30
31

The remainder of the skin examination is normal. Which of the following is the most likely cause of this patient's skin lesion?

A. Allergic drug reaction

B. Antithrombin deficiency

C. Autoimmune phenomena

D. Protein C deficiency

E. Vitamin K deficiency

Submit

1
2
3
4
5
6
7
8
9
10
11
12
13
14
15
16
17
18
19
20
21
22
23
24
25
26
27
28
29
30
31

The remainder of the skin examination is normal. Which of the following is the most likely cause of this patient's skin lesion?

A. Allergic drug reaction (7%)

B. Antithrombin deficiency (3%)

C. Autoimmune phenomena (4%)

✓ D. Protein C deficiency (73%)

E. Vitamin K deficiency (10%)

Omitted
Correct answer

73%
Answered correctly

07 secs
Time Spent

02/27/2020
Last Updated

This patient was started on warfarin to prevent thromboembolism secondary to atrial fibrillation. The sharply demarcated purpuric lesion likely represents **warfarin-induced skin necrosis**, a rare complication that can occur in individuals with underlying **protein C or S deficiency** shortly after starting warfarin.

Protein C and S are innate anticoagulants that are vitamin K dependent, as are coagulation factors II, VII, IX, and X. Warfarin inhibits epoxide reductase (responsible for regenerating vitamin K), which leads to decreased levels of these proteins. Factor VII and protein C are depleted first due to their shorter half-life. The early loss of protein C leads to a **transient hypercoagulable state** that persists until the other coagulant factors are sufficiently inhibited. In patients with protein C or S deficiency, this prothrombotic state is exaggerated, promoting **microvasculature occlusion** and hemorrhagic skin necrosis.

Treatment of warfarin-induced skin necrosis includes discontinuing warfarin and administering fresh frozen plasma or protein C concentrate.

(Choice A) Allergic drug reactions are immune-mediated hypersensitivity reactions that can have variable cutaneous findings ranging from diffuse erythematous eruptions to extensive blistering and exfoliation (eg, Stevens-Johnson syndrome/toxic epidermal necrolysis). However, this patient's recent warfarin use and localized skin findings are more suggestive of warfarin-induced skin necrosis.

(Choice B) Antithrombin deficiency can be inherited (autosomal dominant) or acquired (eg, cirrhosis, nephrotic syndrome) and presents with venous thromboembolism (eg, deep vein thrombosis, pulmonary embolism) and resistance to heparin.

(Choice C) Heparin-induced thrombocytopenia is an autoimmune phenomenon that causes arterial and venous thrombosis. It can produce skin findings similar to this patient's but would generally be associated with thrombocytopenia and recent heparin use.

(Choice E) Vitamin K deficiency is usually associated with easy bruising and bleeding, although thrombosis could potentially occur in patients with concomitant protein C deficiency. However, vitamin K deficiency most often occurs in patients who have fat malabsorption or those who are taking broad-spectrum antibiotics.

Education objective:
Patients started on warfarin develop a transient hypercoagulable state due to the short half-life of protein C. This hypercoagulability is further exaggerated by preexisting protein C deficiency and can result in thrombotic occlusion of the microvasculature with skin necrosis.

References

- Warfarin-induced skin necrosis

A 54-year-old man comes to the emergency department with pain and swelling in the right leg. The patient has no other medical problems and takes no medications. He has smoked a pack of cigarettes daily for the past 30 years. He is a business executive and just returned from an overseas trip. Physical examination shows pitting edema of the right leg and tenderness on deep palpation of the calf muscles. Peripheral pulses are symmetric and full. He is started on a medication that prolongs activated partial thromboplastin time and prothrombin time in a dose-dependent manner but has no effect on thrombin time. Which of the following agents was this patient most likely administered?

A. Cyclooxygenase inhibitor

B. Direct factor VIIa inhibitor

C. Direct factor Xa inhibitor

D. Direct thrombin inhibitor

E. Unfractionated heparin

Submit

A 54-year-old man comes to the emergency department with pain and swelling in the right leg. The patient has no other medical problems and takes no medications. He has smoked a pack of cigarettes daily for the past 30 years. He is a business executive and just returned from an overseas trip. Physical examination shows pitting edema of the right leg and tenderness on deep palpation of the calf muscles. Peripheral pulses are symmetric and full. He is started on a medication that prolongs activated partial thromboplastin time and prothrombin time in a dose-dependent manner but has no effect on thrombin time. Which of the following agents was this patient most likely administered?

A. Cyclooxygenase inhibitor (4%)
B. Direct factor VIIa inhibitor (5%)
✓ C. Direct factor Xa inhibitor (62%)
D. Direct thrombin inhibitor (5%)
E. Unfractionated heparin (22%)

Omitted
Correct answer
C

62%
Answered correctly

02 secs
Time Spent

04/25/2020
Last Updated

Explanation

Anticoagulants & their mechanism of action

Intrinsic pathway

Extrinsic pathway

Tissue factor

1
2
3
4
5
6
7
8
9
10
11
12
13
14
15
16
17
18
19
20
21
22
23
24
25
26
27
28
29
30
31

Anticoagulants & their mechanism of action

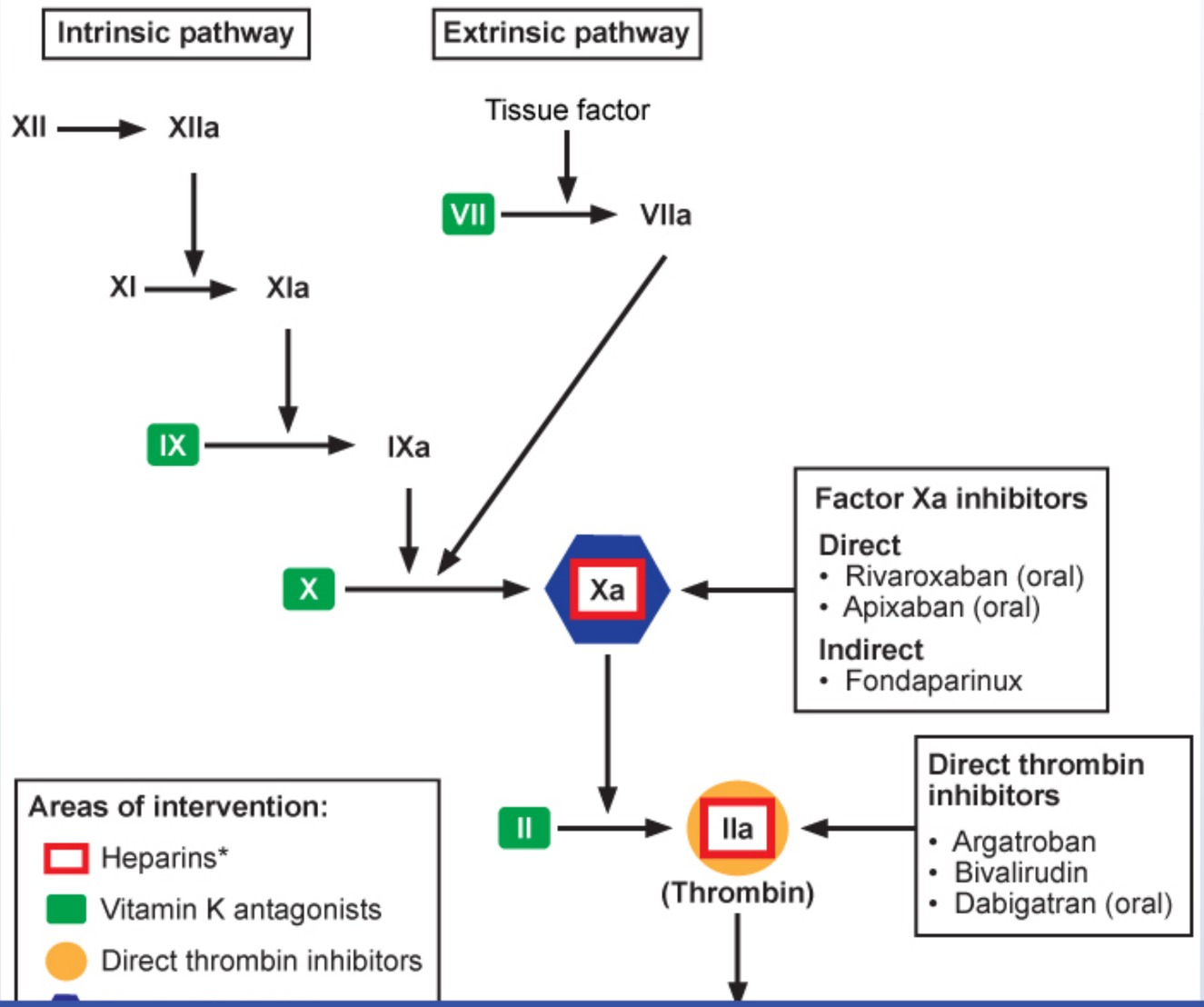

*Major mechanism of action; antithrombin III has some inhibition on all activated coagulation factors.
©UWorld

This patient has **deep venous thrombosis**, which is typically treated with **anticoagulation therapy for ≥3 months** to prevent recurrent thrombosis. Initial treatment is often with **heparin agents** (eg, unfractionated heparin, low-molecular-weight heparin, fondaparinux), followed by bridging to an **oral anticoagulant** (most commonly warfarin). Additional treatment options include direct factor Xa inhibitors (eg, apixaban, rivaroxaban) and direct thrombin inhibitors (eg, dabigatran).

In general, medications that affect the extrinsic pathway prolong the prothrombin time (PT), whereas inhibition of the intrinsic pathway mainly prolongs the activated partial thromboplastin time (aPTT). The thrombin time (TT) is prolonged with medications that directly or indirectly inhibit thrombin. Because factor Xa is located at the junction of the intrinsic and extrinsic pathways, **direct factor Xa inhibitors** prolong both **aPTT and PT** with no effect on TT.

(Choice A) Cyclooxygenase inhibitors (eg, aspirin) directly inhibit platelet activity and have little overall effect on aPTT, PT, or TT.

(Choice B) Direct factor VIIa inhibitors are currently in development and work by inhibiting the extrinsic pathway of the coagulation cascade. Therefore, they would prolong PT with no effect on aPTT or TT.

(Choice D) Direct thrombin inhibitors (eg, dabigatran) prevent the formation of thrombin (factor IIa), resulting in prolongation of aPTT, PT, and TT.

(Choice E) Unfractionated heparin binds to antithrombin and causes inactivation of several coagulation factors, most significantly thrombin and factor Xa. As a result, aPTT and TT will be prolonged. Although the PT should theoretically be prolonged by the action of heparin on the final common pathway, in practice, the PT reagent contains heparin neutralizers that minimize this effect.

Educational objective:
Direct factor Xa inhibitors (eg, apixaban, rivaroxaban) increase the prothrombin and activated partial thromboplastin times but do not affect the thrombin time. Unfractionated heparin and direct thrombin inhibitors (eg, dabigatran) prolong the thrombin time.

References

- Developments in factor Xa inhibitors for the treatment of thromboembolic disorders

Pathophysiology	Hematology & Oncology	Anticoagulants
Subject	System	Topic

*Major mechanism of action; antithrombin III has some inhibition on all activated coagulation factors.

Exhibit Display

Coagulation cascade pathway

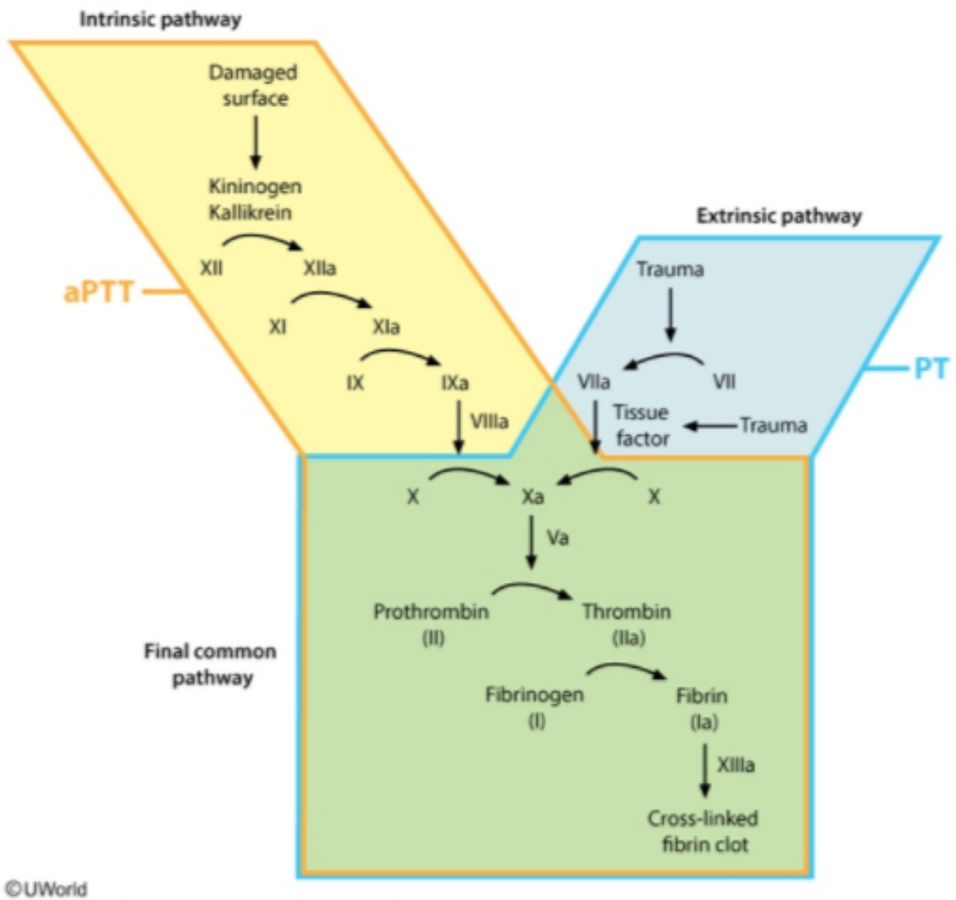

aPTT = activated partial thromboplastin time; PT = prothrombin time.

Zoom In | Zoom Out | Reset | Add To New Card | Existing Card

*Major mechanism of action; antithrombin III has some inhibition on all activated coagulation factors.

Exhibit Display

Heparin's mechanism of action

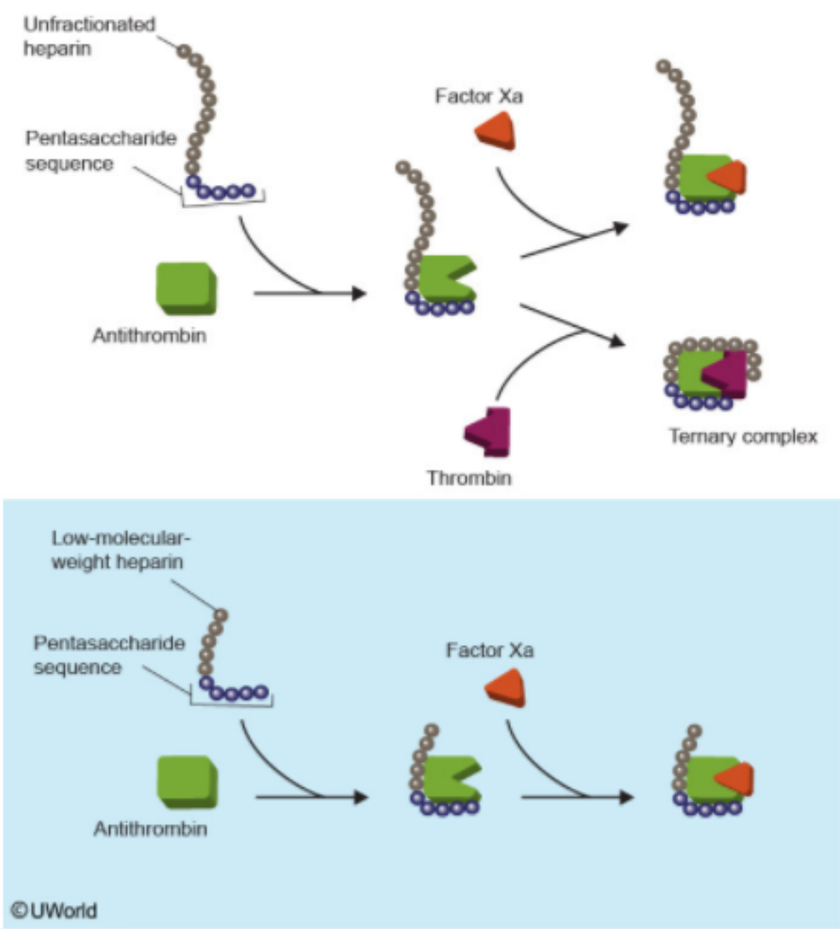

Zoom In | Zoom Out | Reset | Add To New Card | Existing Card

1
2
3
4
5
6
7
8
9
10
11
12
13
14
15
16
17
18
19
20
21
22
23
24
25
26
27
28
29
30
31

A 45-year-old man comes to the office for evaluation of fatigue that has been gradually increasing over the past 4 months. The patient has had difficulty keeping up with the labor involved with his job as a construction worker. Over the past 2 weeks, he has been unable to climb past the second floor of the building his company is renovating. The patient also has increasing shortness of breath with minor activities, such as lifting his toolbox out of the car. Review of systems reveals constipation and decreased concentration. Physical examination shows an overweight male with conjunctival pallor who has difficulty getting onto the examination table due to shortness of breath. Laboratory test results are as follows:

Complete blood count	
Hematocrit	26%
Mean corpuscular volume	72 fL
Ferritin	50 ng/mL (normal: 15-200 ng/mL)
Iron studies	
Iron	120 µg/dL (normal: 60-160 µg/dL)
Iron binding capacity	320 µg/dL (normal: 250-460 µg/dL)

Which of the following findings would most likely be seen on this patient's peripheral blood smear?

A. Basophilic stippling
B. Heinz bodies
C. Howell-Jolly bodies
D. Ring sideroblasts
E. Schistocytes

second floor of the building his company is renovating. The patient also has increasing shortness of breath with minor activities, such as lifting his toolbox out of the car. Review of systems reveals constipation and decreased concentration. Physical examination shows an overweight male with conjunctival pallor who has difficulty getting onto the examination table due to shortness of breath. Laboratory test results are as follows:

Complete blood count	
Hematocrit	26%
Mean corpuscular volume	72 fL
Ferritin	50 ng/mL (normal: 15-200 ng/mL)
Iron studies	
Iron	120 µg/dL (normal: 60-160 µg/dL)
Iron binding capacity	320 µg/dL (normal: 250-460 µg/dL)

Which of the following findings would most likely be seen on this patient's peripheral blood smear?

A. Basophilic stippling
B. Heinz bodies
C. Howell-Jolly bodies
D. Ring sideroblasts
E. Schistocytes

Submit

second floor of the building his company is renovating. The patient also has increasing shortness of breath with minor activities, such as lifting his toolbox out of the car. Review of systems reveals constipation and decreased concentration. Physical examination shows an overweight male with conjunctival pallor who has difficulty getting onto the examination table due to shortness of breath. Laboratory test results are as follows:

Complete blood count	
Hematocrit	26%
Mean corpuscular volume	72 fL
Ferritin	50 ng/mL (normal: 15-200 ng/mL)
Iron studies	
Iron	120 µg/dL (normal: 60-160 µg/dL)
Iron binding capacity	320 µg/dL (normal: 250-460 µg/dL)

Which of the following findings would most likely be seen on this patient's peripheral blood smear?

- ✓ A. Basophilic stippling (54%)
- B. Heinz bodies (5%)
- C. Howell-Jolly bodies (6%)
- D. Ring sideroblasts (22%)
- E. Schistocytes (10%)

Omitted
Correct answer

54%
Answered correctly

04 secs
Time Spent

01/30/2020
Last Updated

Lead poisoning in adults	
Risk factors	• Occupational exposure (eg, lead paint, batteries, ammunition, construction)
Clinical features	• Gastrointestinal (abdominal pain, constipation, anorexia) • Neurologic (cognitive deficits, peripheral neuropathy) • Hematologic (anemia)
Laboratory findings	• Anemia • Elevated venous lead level • Elevated serum zinc protoporphyrin level • Basophilic stippling on peripheral smear

This patient has **microcytic anemia**, **constipation**, and **mental status changes** in the setting of **construction work**. The most likely diagnosis is **lead poisoning**. Lead is a soft, heavy metal used for manufacturing a wide range of items, including batteries, alloys, and ammunition. Individuals working in these industries and others (eg, construction, mining, smelting, chemical processing, recycling, spray painting, radiator repair) can be regularly exposed to lead.

Lead inhibits the heme synthesis pathway (δ-aminolevulinate dehydratase and ferrochelatase), causing a microcytic, hypochromic anemia. Shortness of breath, particularly with exertion, occurs due to decreased oxygen delivery to peripheral tissues. Iron studies are normal unless co-existing iron deficiency is present as well. Basophilic stippling is frequently seen on peripheral blood smear. Inhibition of erythrocyte 5' nucleotidase by lead results in ribosome aggregation due to inability to degrade RNA, which is represented by coarse blue punctate dots in the cytoplasm of red blood cells (RBCs). Basophilic stippling is nonspecific and also seen in the thalassemias and myelodysplastic syndrome.

Adult lead poisoning can also have the following manifestations:

1. Bluish pigmentation ("lead line") at the gum-tooth line.
2. Wrist drop or foot drop due to peripheral neuropathy.

(Choice B) Heinz bodies are inclusions of denatured hemoglobin most commonly seen after oxidant stress in patients with glucose-6-phosphate

1
2
3
4
5
6
7
8
9
10
11
12
13
14
15
16
17
18
19
20
21
22
23
24
25
26
27
28
29
30
31

Lead inhibits the heme synthesis pathway (δ-aminolevulinate dehydratase and ferrochelatase), causing a microcytic, hypochromic anemia. Shortness of breath, particularly with exertion, occurs due to decreased oxygen delivery to peripheral tissues. Iron studies are normal unless co-existing iron deficiency is present as well. Basophilic stippling is frequently seen on peripheral blood smear. Inhibition of erythrocyte 5' nucleotidase by lead results in ribosome aggregation due to inability to degrade RNA, which is represented by coarse blue punctate dots in the cytoplasm of red blood cells (RBCs). Basophilic stippling is nonspecific and also seen in the thalassemias and myelodysplastic syndrome.

Adult lead poisoning can also have the following manifestations:

1. Bluish pigmentation ("lead line") at the gum-tooth line.
2. Wrist drop or foot drop due to peripheral neuropathy.

(Choice B) Heinz bodies are inclusions of denatured hemoglobin most commonly seen after oxidant stress in patients with glucose-6-phosphate dehydrogenase deficiency.

(Choice C) Howell-Jolly bodies are nuclear DNA remnant inclusions in peripheral RBCs that are normally removed by the spleen during circulation. The presence of Howell-Jolly bodies indicates decreased or absent splenic function (eg, post-splenectomy).

(Choice D) Ring sideroblasts are formed from precipitation of iron granules in developing erythrocytes due to defects in the heme synthesis pathway, including enzymatic inhibition induced by lead poisoning. Ring sideroblasts are seen in the bone marrow but not in the peripheral blood smear.

(Choice E) Schistocytes are fragmented parts of RBCs formed from mechanical hemolysis via sheer force of blood flow. Hemolytic uremic syndrome, thrombotic thrombocytopenic purpura, and disseminated intravascular coagulation all present with schistocytes.

Educational objective:
Lead poisoning in adults typically occurs through occupational exposure. Symptoms include colicky abdominal pain, constipation, lead lines on the gum, peripheral neuropathy, and anemia. Laboratory testing shows microcytic anemia with normal iron studies, and peripheral blood smear may reveal basophilic stippling.

References

- Lead toxicity.

Exhibit Display

Lead toxicity

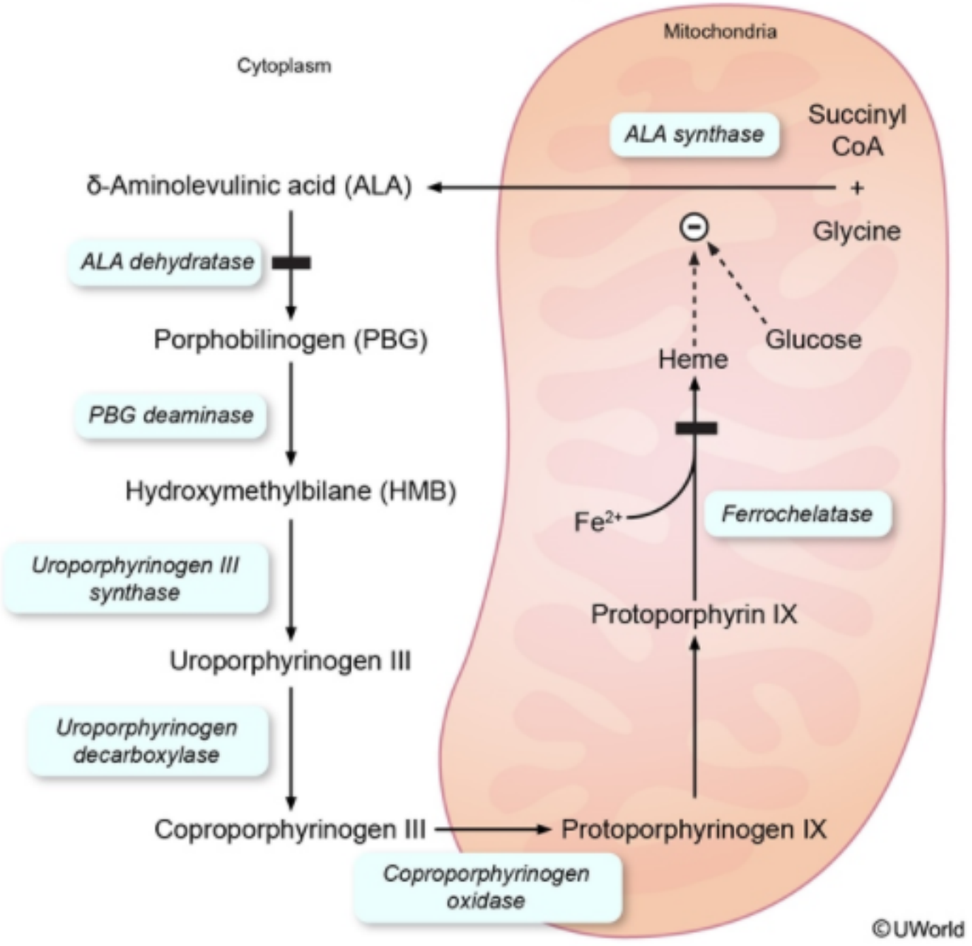

Zoom In | Zoom Out | Reset | Add To New Card | Existing Card

1
2
3
4
5
6
7
8
9
10
11
12
13
14
15
16
17
18
19
20
21
22
23
24
25
26
27
28
29
30
31

Exhibit Display

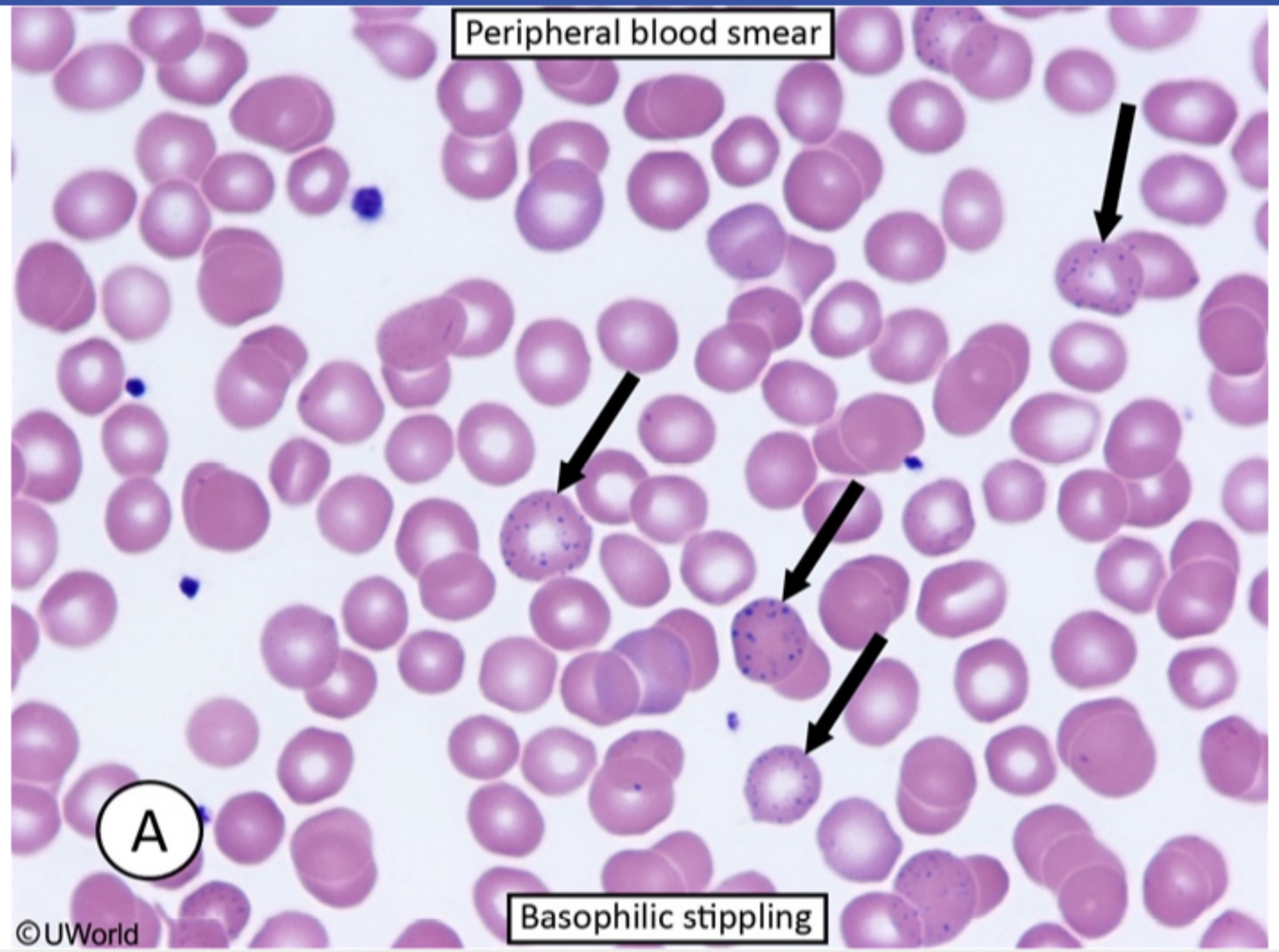

Zoom In | Zoom Out | Reset | Add To New Card | Existing Card

1
2
3
4
5
6
7
8
9
10
11
12
13
14
15
16
17
18
19
20
21
22
23
24
25
26
27
28
29
30
31

Exhibit Display

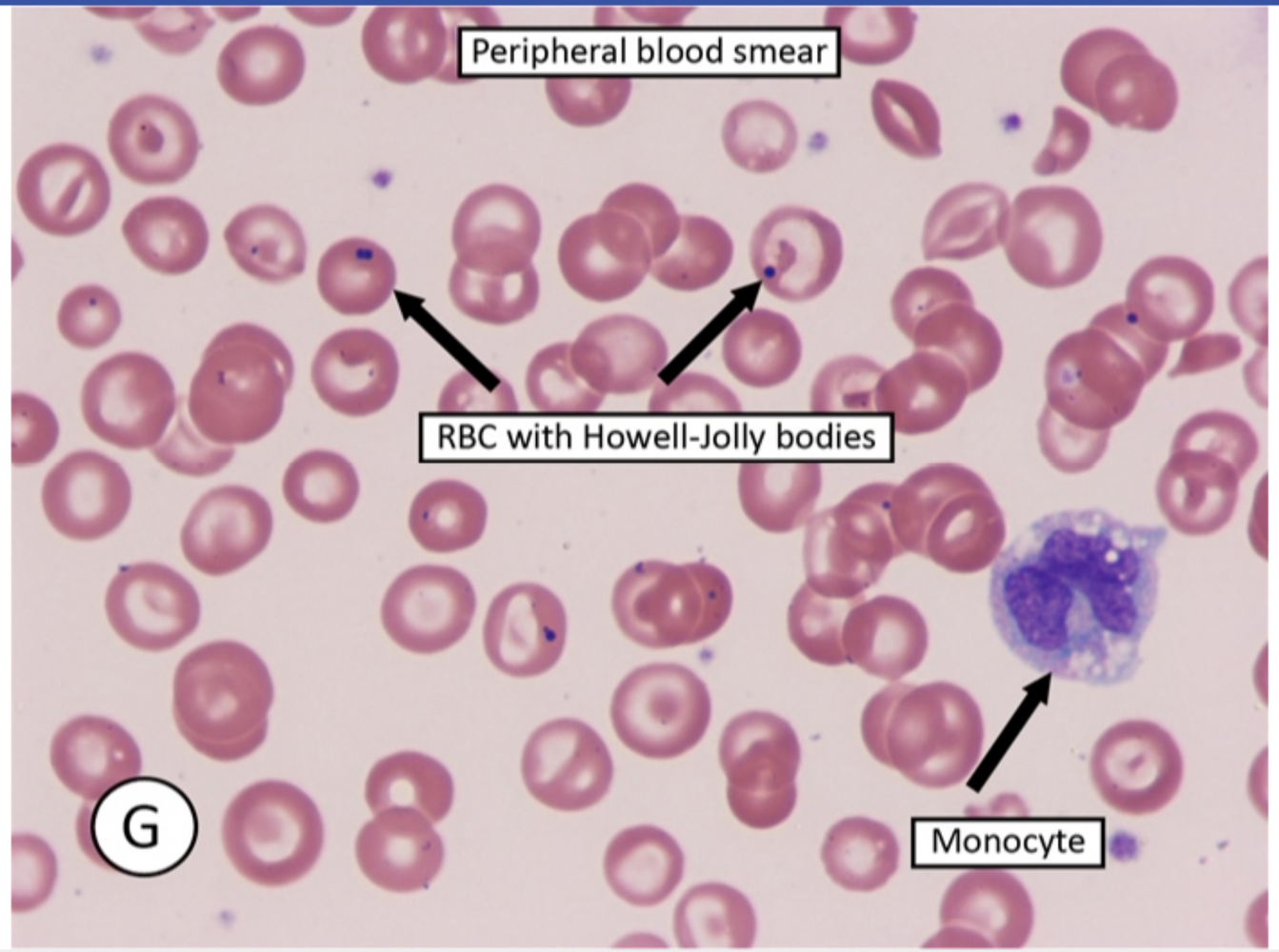

Zoom In | Zoom Out | Reset | Add To New Card | Existing Card

1
2
3
4
5
6
7
8
9
10
11
12
13
14
15
16
17
18
19
20
21
22
23
24
25
26
27
28
29
30
31

Exhibit Display

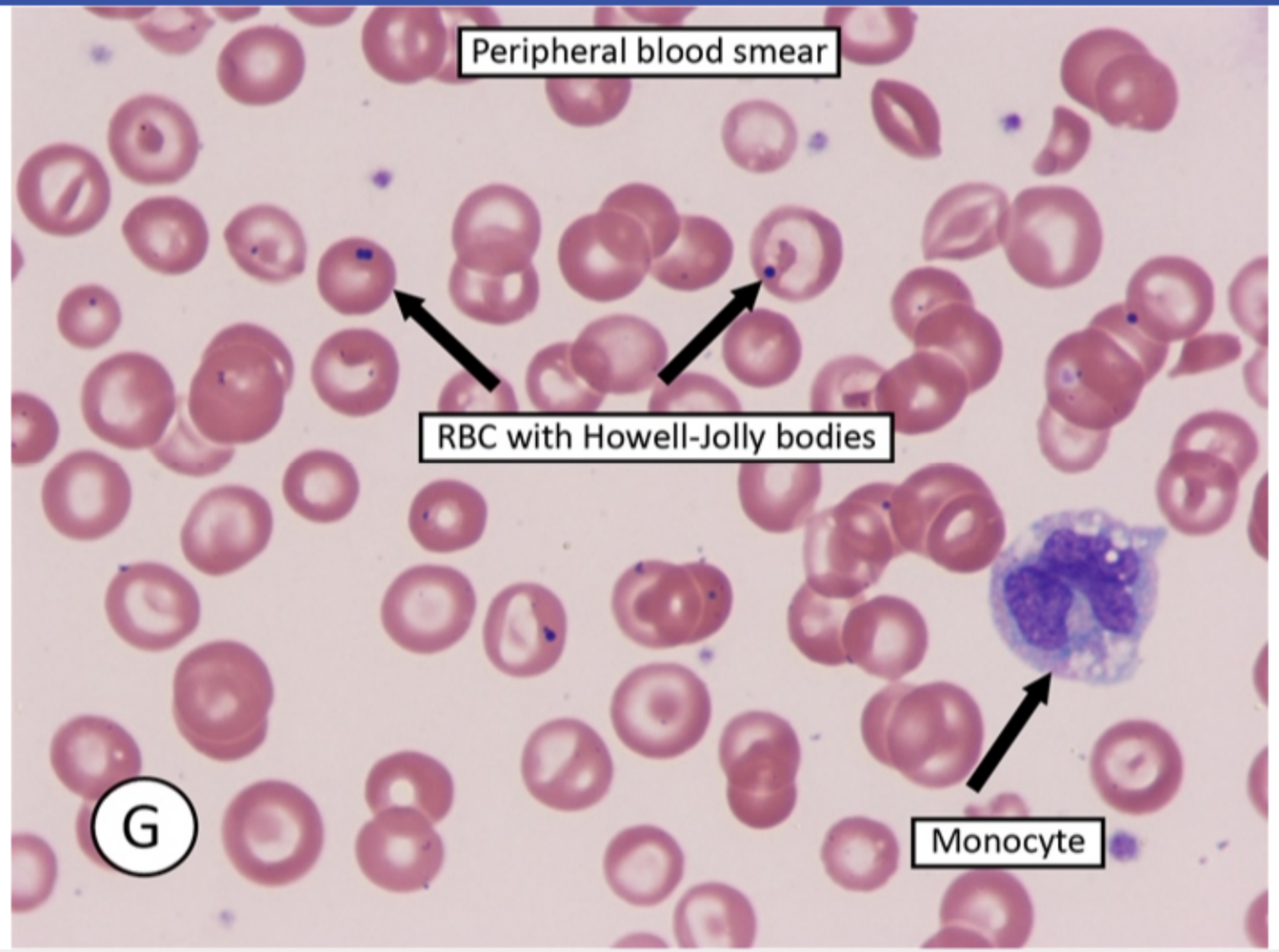

Zoom In | Zoom Out | Reset | Add To New Card | Existing Card

1
2
3
4
5
6
7
8
9
10
11
12
13
14
15
16
17
18
19
20
21
22
23
24
25
26
27
28
29
30
31

Exhibit Display

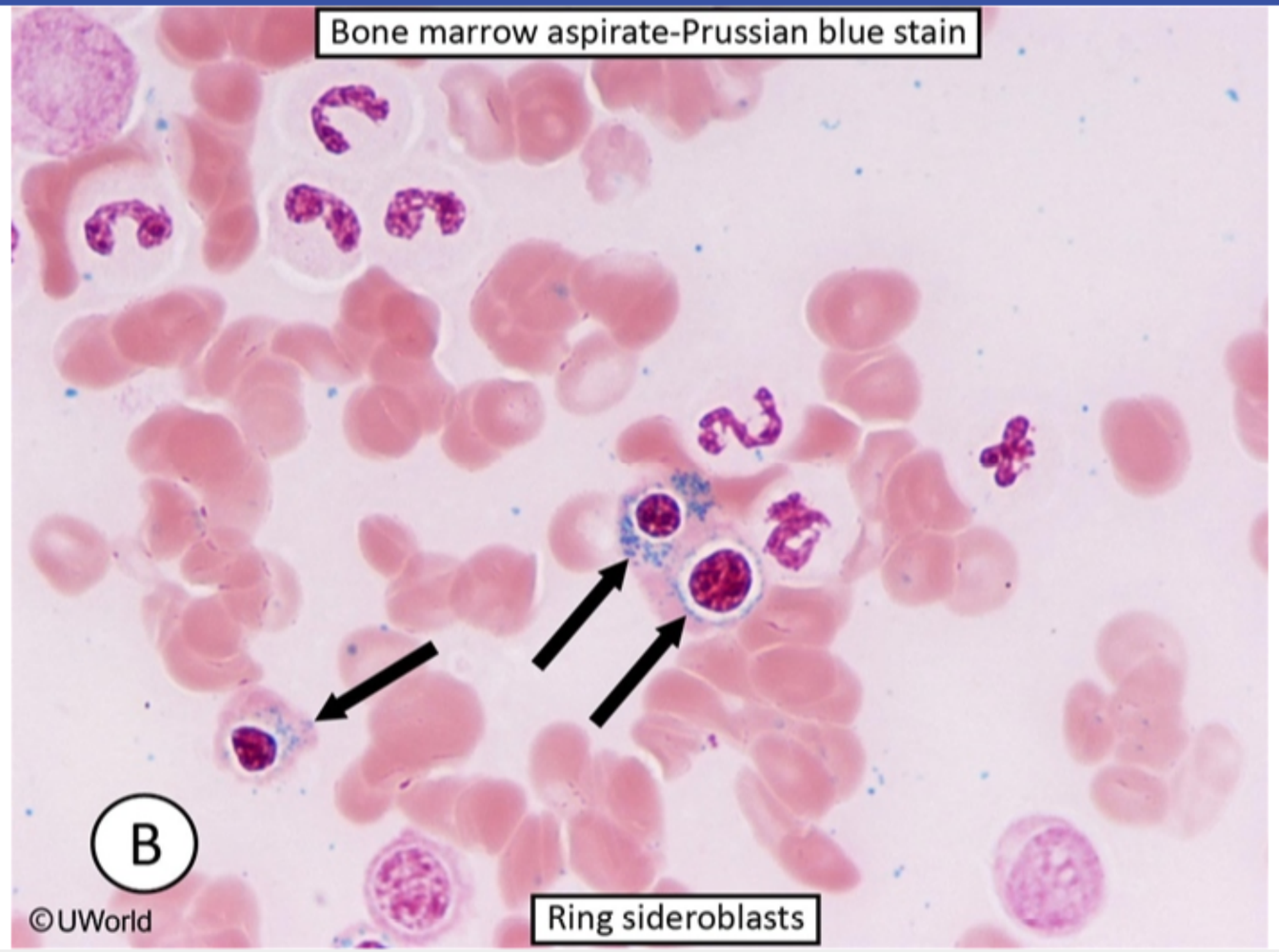

Zoom In | Zoom Out | Reset | Add To New Card | Existing Card

1
2
3
4
5
6
7
8
9
10
11
12
13
14
15
16
17
18
19
20
21
22
23
24
25
26
27
28
29
30
31

Exhibit Display

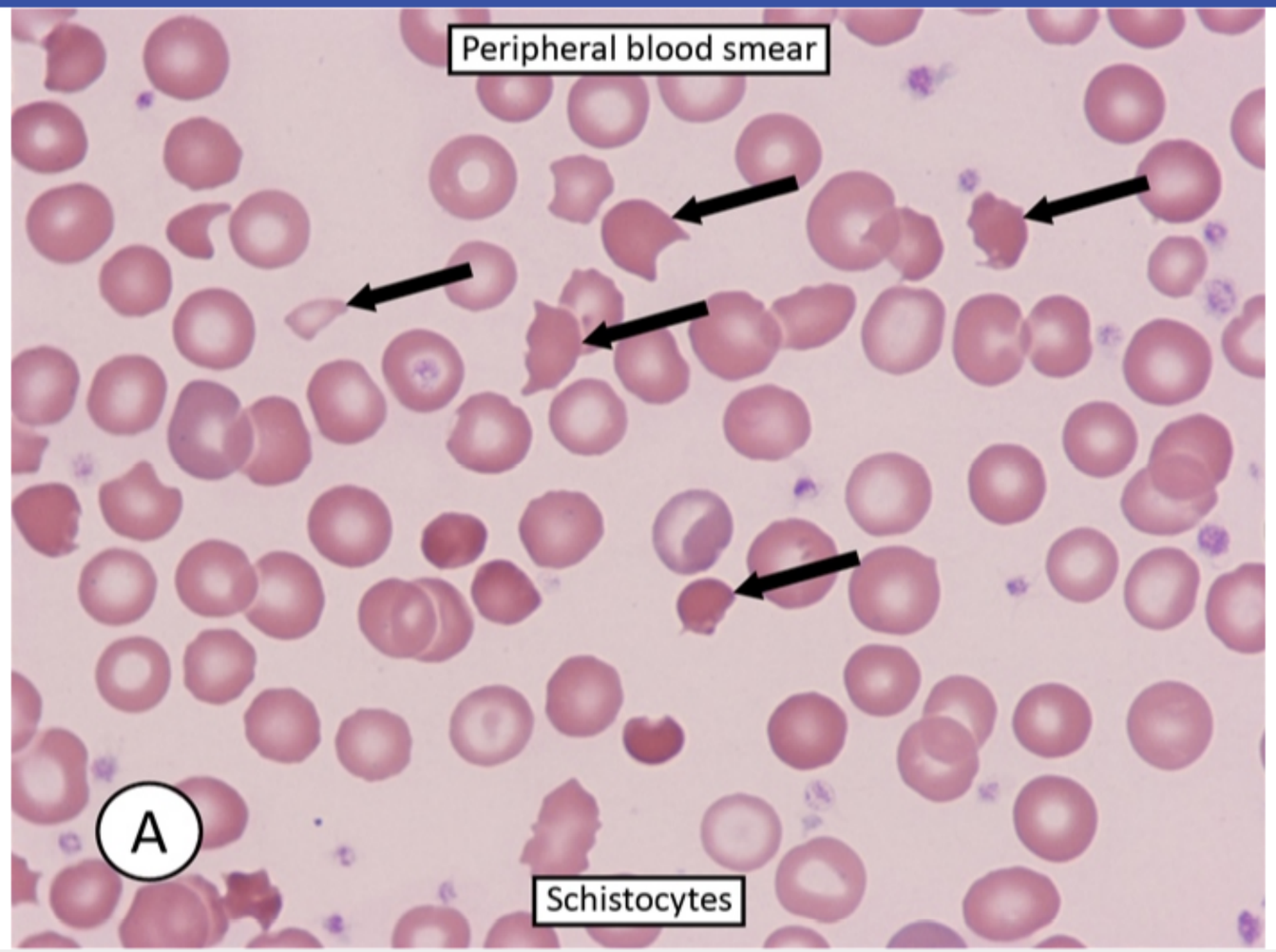

Zoom In | Zoom Out | Reset | Add To New Card | Existing Card

A 35-year-old woman comes to the office for evaluation of fatigue and exertional dyspnea. She has a history of systemic lupus erythematosus and is noncompliant with therapy. The patient takes naproxen as needed for joint pains. Vital signs are within normal limits. Examination shows mild pallor. The remainder of the examination shows no abnormalities. Laboratory results are as follows:

Hemoglobin	8.6 g/dL	
Mean corpuscular volume	80 mm^3	
Creatinine	0.8 mg/dL	
Iron, serum	40 µg/dL	
Total iron-binding capacity	180 µg/dL	(normal: 250-460 µg/dL)
Lactate dehydrogenase	72 U/L	

Which of the following is the most likely underlying cause of her current condition?

A. Immune hemolysis of erythrocytes
B. Increased cellular use of folic acid
C. Intrinsic factor antibodies
D. Iron sequestration in macrophages
E. Occult gastrointestinal blood loss

Submit

A 35-year-old woman comes to the office for evaluation of fatigue and exertional dyspnea. She has a history of systemic lupus erythematosus and is noncompliant with therapy. The patient takes naproxen as needed for joint pains. Vital signs are within normal limits. Examination shows mild pallor. The remainder of the examination shows no abnormalities. Laboratory results are as follows:

Hemoglobin	8.6 g/dL	
Mean corpuscular volume	80 mm^3	
Creatinine	0.8 mg/dL	
Iron, serum	40 µg/dL	
Total iron-binding capacity	180 µg/dL	(normal: 250-460 µg/dL)
Lactate dehydrogenase	72 U/L	

Which of the following is the most likely underlying cause of her current condition?

A. Immune hemolysis of erythrocytes (17%)
B. Increased cellular use of folic acid (0%)
C. Intrinsic factor antibodies (1%)
✓ D. Iron sequestration in macrophages (70%)
E. Occult gastrointestinal blood loss (10%)

Omitted
Correct answer
D

70%
Answered correctly

03 secs
Time Spent

05/16/2020
Last Updated

	Iron deficiency anemia	Anemia of chronic disease
Serum ferritin	↓	Normal or ↑
Serum iron	↓	↓
Mean corpuscular volume	↓	Normal or ↓
Transferrin (total iron-binding capacity)	↑	Normal or ↓
Transferrin saturation	↓	↓
Erythropoietin	↑	Normal or ↑
Hepcidin	↓	↑
C-reactive protein	Normal	↑
Serum cytokines	Normal	↑

This patient with untreated systemic lupus erythematosus (SLE) has normocytic anemia with low serum iron and low total iron-binding capacity, raising strong suspicion for **anemia of chronic disease** (ACD). Most cases arise in those with **chronic elevation of inflammatory cytokines** due to underlying rheumatologic disease (eg, SLE), chronic infection, or malignancy. Although a number of inflammatory cytokines contribute to the development of ACD, the primary mediator is **hepcidin**, a small peptide released by the liver in response to inflammation.

Hepcidin binds to and inactivates iron channels (ferroportin) on enterocytes and reticuloendothelial macrophages, which results in reduced iron absorption in the gut and **increased iron sequestration** in the reticuloendothelial system. Because **reticuloendothelial macrophages** recycle senescent erythrocytes and provide >95% of daily iron for erythrocytosis, sequestration of iron in the reticuloendothelial system dramatically **reduces serum iron concentration**. This limits the amount of iron available for the generation of new erythrocytes and typically results in a

due to underlying rheumatologic disease (eg, SLE), chronic infection, or malignancy. Although a number of inflammatory cytokines contribute to the development of ACD, the primary mediator is **hepcidin**, a small peptide released by the liver in response to inflammation.

Hepcidin binds to and inactivates iron channels (ferroportin) on enterocytes and reticuloendothelial macrophages, which results in reduced iron absorption in the gut and **increased iron sequestration** in the reticuloendothelial system. Because **reticuloendothelial macrophages** recycle senescent erythrocytes and provide >95% of daily iron for erythrocytosis, sequestration of iron in the reticuloendothelial system dramatically **reduces serum iron concentration**. This limits the amount of iron available for the generation of new erythrocytes and typically results in a normocytic (or slightly microcytic) anemia with a low reticulocyte response. In ACD, **total iron-binding capacity** is generally **normal or slightly reduced** due to cytokine-mediated suppression of transferrin.

(Choices A and E) Patients with SLE can develop immune-mediated hemolysis due to the generation of autoantibodies against the erythrocyte membrane; however, this typically results in extravascular hemolysis, which increases the intracellular enzyme lactate dehydrogenase. The presence of *normal lactate dehydrogenase* in this case makes hemolysis less likely. Patients with SLE also sometimes develop gastrointestinal bleeding from serositis (or chronic NSAID use), which can lead to iron deficiency anemia. However, iron deficiency anemia is typically associated with *microcytic anemia* and a *high total iron-binding capacity* (because transferrin levels are markedly increased).

(Choices B and C) Conditions associated with rapid cell turnover can result in folate deficiency due to increased folate use during the generation of new cells. Intrinsic factor antibodies are a common cause of vitamin B_{12} deficiency. However, folate and vitamin B_{12} deficiency are generally marked by macrocytic anemia with a normal or *high serum iron level*.

Educational objective:
Anemia of chronic disease is a consequence of chronically elevated inflammatory cytokines, most importantly hepcidin. This peptide inactivates iron channels on enterocytes and reticuloendothelial macrophages, leading to reduced iron absorption and reduced iron release from the reticuloendothelial system. The net result is normocytic or slightly microcytic anemia with low reticulocyte response, low serum iron level, and normal or low total iron-binding capacity.

Pathophysiology	Hematology & Oncology	Anemia of inflammation
Subject	System	Topic

Copyright © UWorld. All rights reserved.

1
2
3
4
5
6
7
8
9
10
11
12
13
14
15
16
17
18
19
20
21
22
23
24
25
26
27
28
29
30
31

A 26-year-old woman comes to the office for follow-up. She has a history of immune thrombocytopenia that failed to improve with glucocorticoid therapy. The patient underwent splenectomy 6 months ago, which resulted in improved platelet counts. She received recommended vaccinations after the surgery and currently feels well. Physical examination shows no abnormalities. A peripheral blood smear reveals many red blood cells of a specific morphology as indicated by the arrow below.

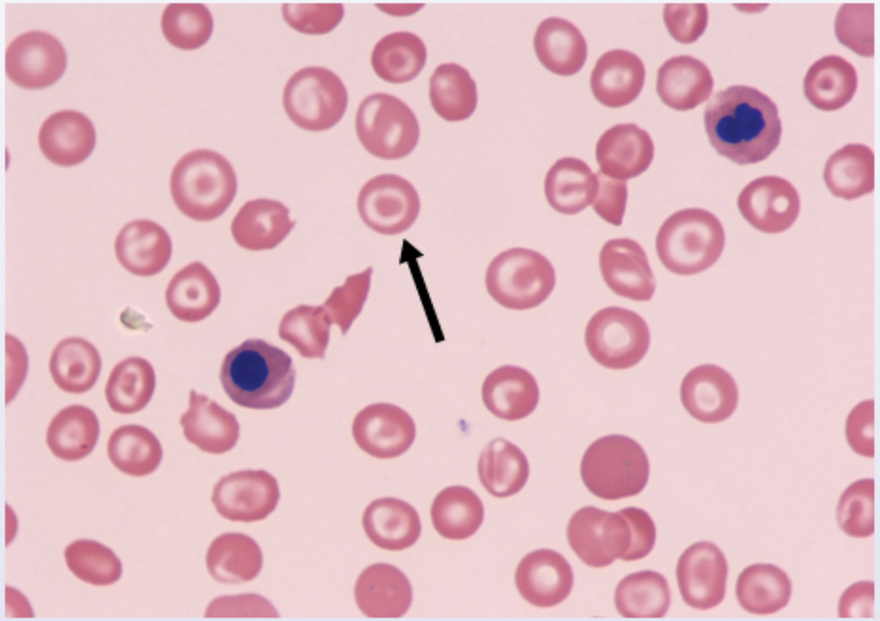

An increase in which of the following features best explains the presence of these abnormal cells?

A. Aggregated iron deposits

B. Clusters of remnant DNA

C. Denatured hemoglobin

D. Fragility to osmotic stress

1
2
3
4
5
6
7
8
9
10
11
12
13
14
15
16
17
18
19
20
21
22
23
24
25
26
27
28
29
30
31

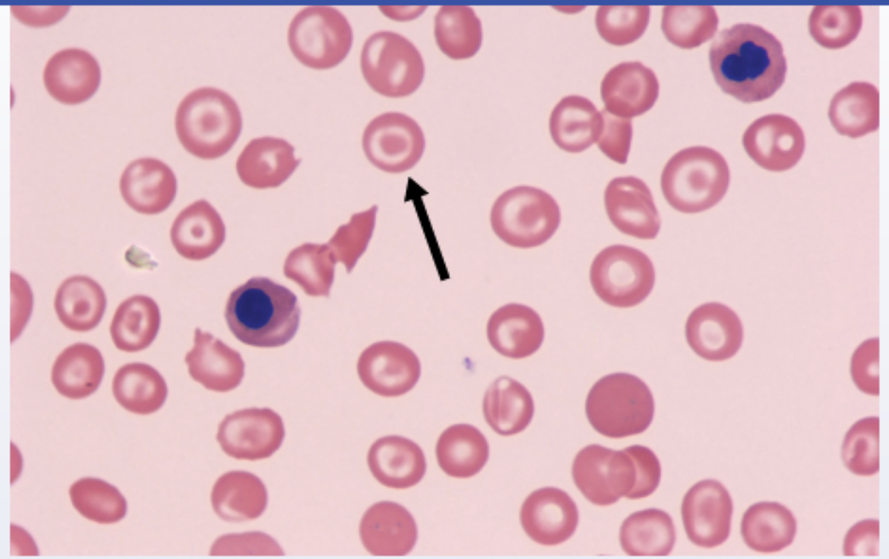

An increase in which of the following features best explains the presence of these abnormal cells?

- A. Aggregated iron deposits
- B. Clusters of remnant DNA
- C. Denatured hemoglobin
- D. Fragility to osmotic stress
- E. Precipitated ribosomes
- F. Surface area-to-volume ratio

Submit

1
2
3
4
5
6
7
8
9
10
11
12
13
14
15
16
17
18
19
20
21
22
23
24
25
26
27
28
29
30
31

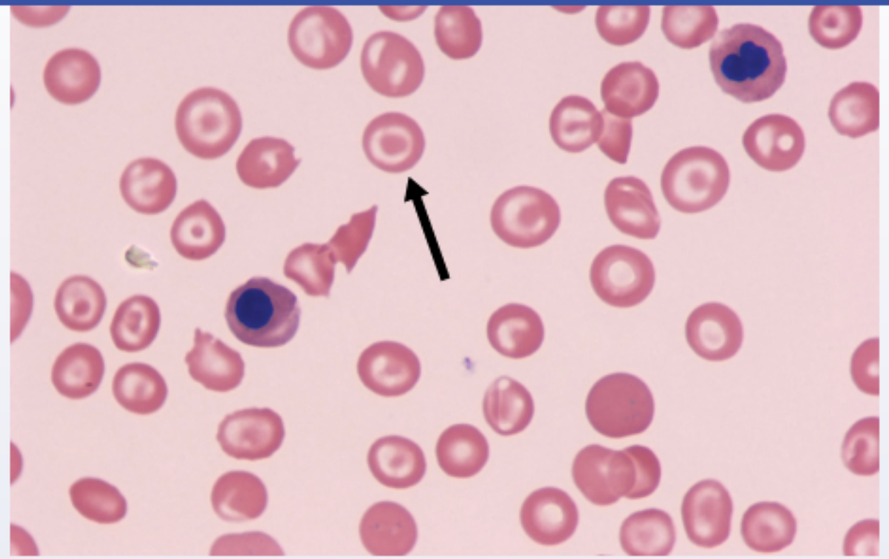

An increase in which of the following features best explains the presence of these abnormal cells?

A. Aggregated iron deposits (2%)

B. Clusters of remnant DNA (7%)

C. Denatured hemoglobin (18%)

D. Fragility to osmotic stress (8%)

E. Precipitated ribosomes (2%)

✓ F. Surface area-to-volume ratio (58%)

Omitted
Correct answer

58%
Answered correctly

05 secs
Time Spent

02/03/2020
Last Updated

Target cells are red blood cells with a dark center, a surrounding halo of pallor, and a dark peripheral ring. They form in erythrocytes with an **excessive surface area-to-volume ratio**, which results in redundant erythrocyte cell membrane folding upon itself (thereby creating the appearance of a target). Target cells occur in patients with the following:

- Reduced erythrocyte cell volume from deficient hemoglobin synthesis (eg, thalassemia, iron deficiency) or structural mutations to hemoglobin (eg, sickle cell)
- **Excessive erythrocyte cellular membrane** due to greater cholesterol-to-phospholipid ratios (eg, obstructive liver disease) or **splenectomy**

Macrophages in the red pulp of the spleen remove excess membrane from red cells, a process called "**splenic conditioning**." Patients who undergo splenectomy are **unable to prune** erythrocytes and generally develop target cells a few weeks following the procedure. However, over time, macrophages in nonsplenic tissue (eg, liver) take up the task of pruning erythrocytes, which typically eliminates (or diminishes) the presence of target cells in the circulation.

(Choice A) Pappenheimer bodies are aggregated iron deposits in erythrocytes that are often seen in patients with sideroblastic anemia. They appear as dark blue inclusions.

(Choice B) Howell-Jolly bodies are clusters of DNA remnants in erythrocytes due to hyposplenism or asplenism (the spleen usually removes the DNA remnants). They appear as peripheral, round, dark purple, blue, or red inclusions.

(Choice C) Heinz bodies are aggregates of denatured hemoglobin that may be present in erythrocytes when patients have glucose-6-phosphate deficiency or thalassemia. They cannot be seen on routine staining.

(Choice D) Spherocytes have low surface area-to-volume ratios and are more susceptible to osmotic stress. They are seen most commonly in hemolytic anemia and hereditary spherocytosis and appear as dense, round red blood cells. Target cells are less susceptible to osmotic stress than normal red blood cells or spherocytes due to their excess membrane.

(Choice E) Basophilic stippling is blue granules dispersed within the cytosol of erythrocytes due to precipitated ribosomes. It is seen most commonly in thalassemias, alcohol abuse, and lead/heavy metal poisoning.

Educational objective:
Target cells form when erythrocytes have reduced cell volume (eg, thalassemia, iron deficiency) or excessive membrane (eg, obstructive liver

1 2 3 4 5 6 7 8 9 10 11 12 13 14 15 16 17 18 19 20 21 22 23 24 25 26 27 28 29 30 31

Exhibit Display

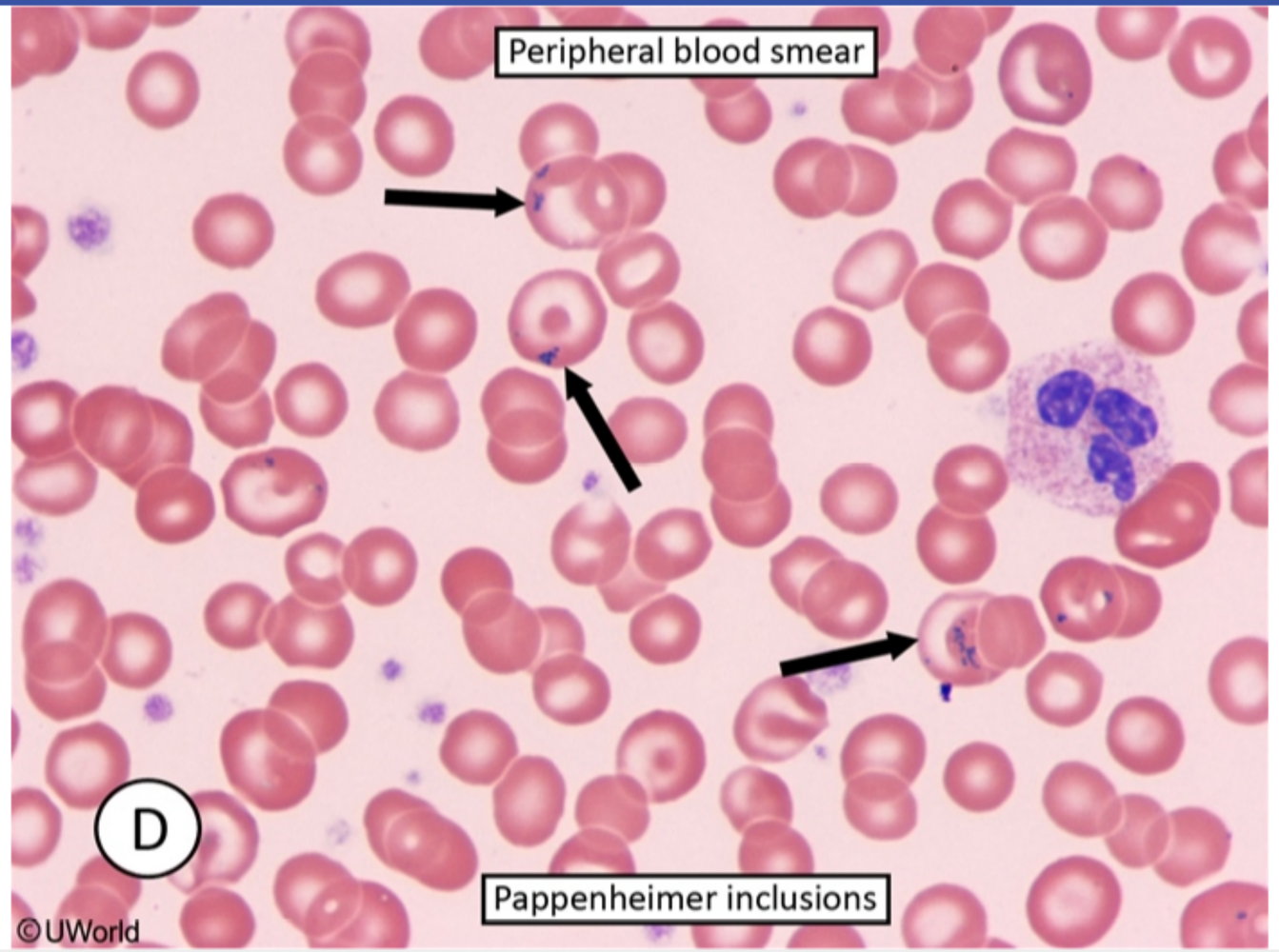

Zoom In | Zoom Out | Reset | Add To New Card | Existing Card

Target cells form when erythrocytes have reduced cell volume (eg, thalassemia, iron deficiency) or excessive membrane (eg, obstructive liver

1
2
3
4
5
6
7
8
9
10
11
12
13
14
15
16
17
18
19
20
21
22
23
24
25
26
27
28
29
30
31

Exhibit Display

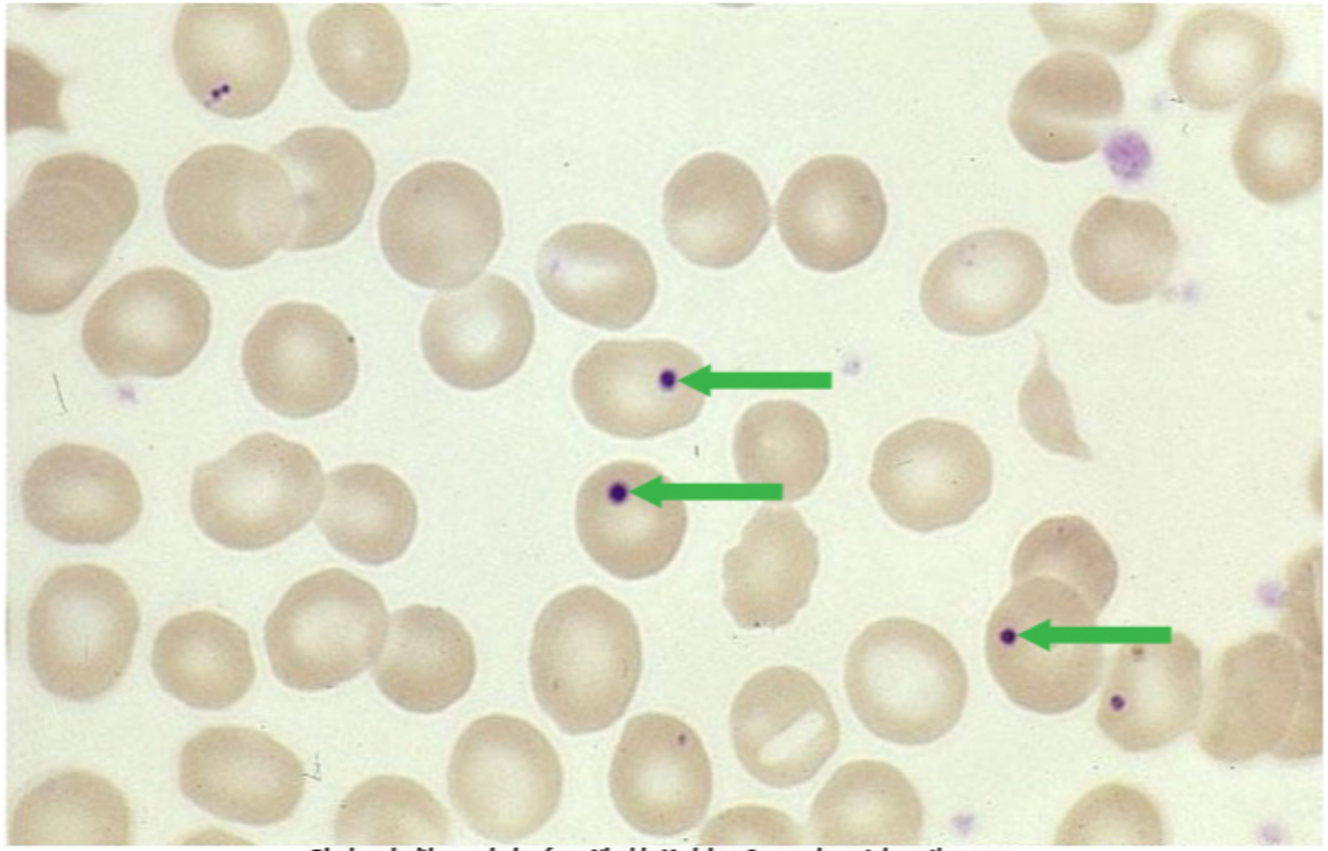

Displayed with permission from Nivaldo Medeiros © www.hematologyatlas.com

Zoom In | Zoom Out | Reset | Add To New Card | Existing Card

Target cells form when erythrocytes have reduced cell volume (eg, thalassemia, iron deficiency) or excessive membrane (eg, obstructive liver

1
2
3
4
5
6
7
8
9
10
11
12
13
14
15
16
17
18
19
20
21
22
23
24
25
26
27
28
29
30
31

Exhibit Display

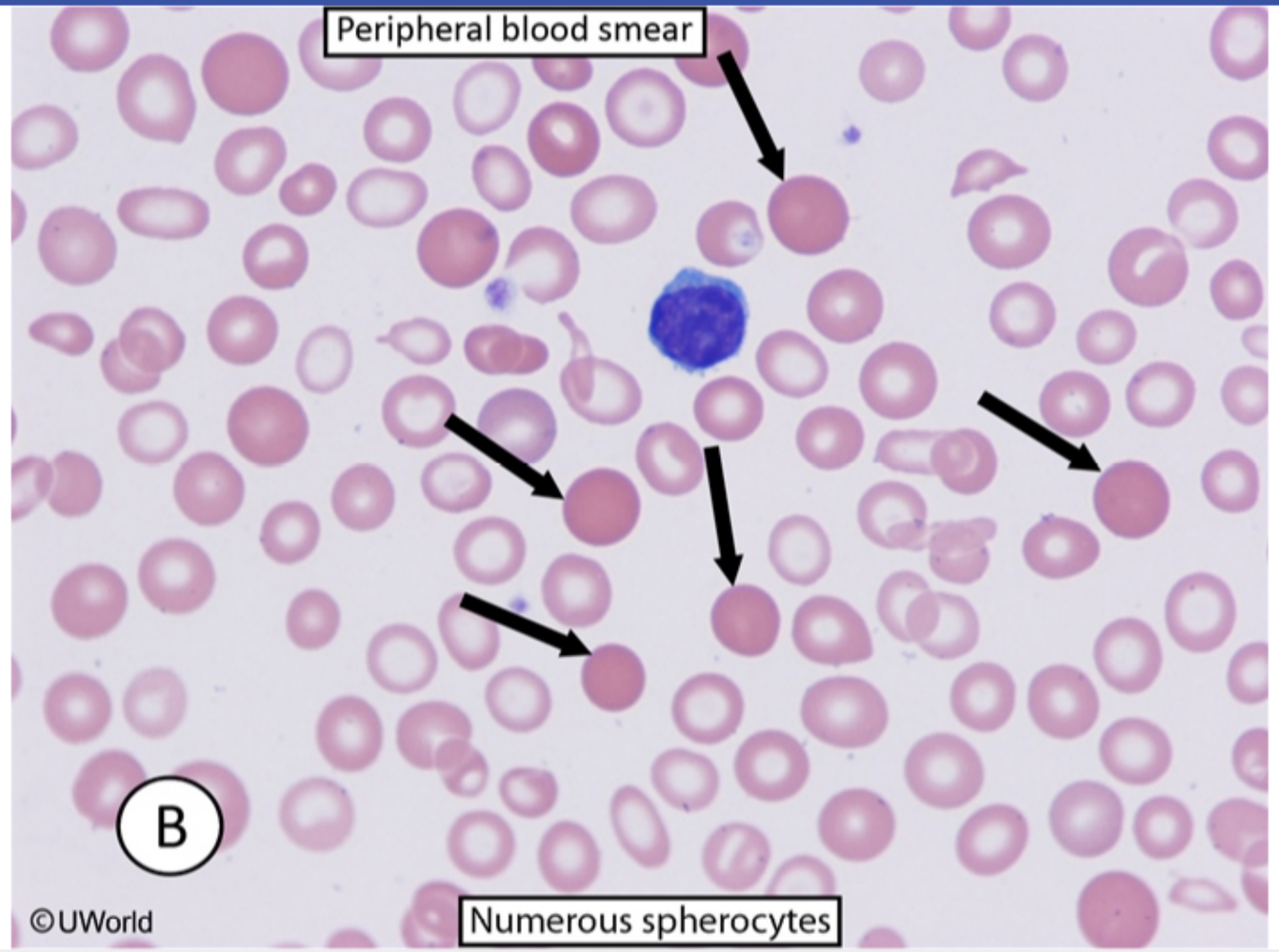

Zoom In | Zoom Out | Reset | Add To New Card | Existing Card

Target cells form when erythrocytes have reduced cell volume (eg, thalassemia, iron deficiency) or excessive membrane (eg, obstructive liver

1
2
3
4
5
6
7
8
9
10
11
12
13
14
15
16
17
18
19
20
21
22
23
24
25
26
27
28
29
30
31

Exhibit Display

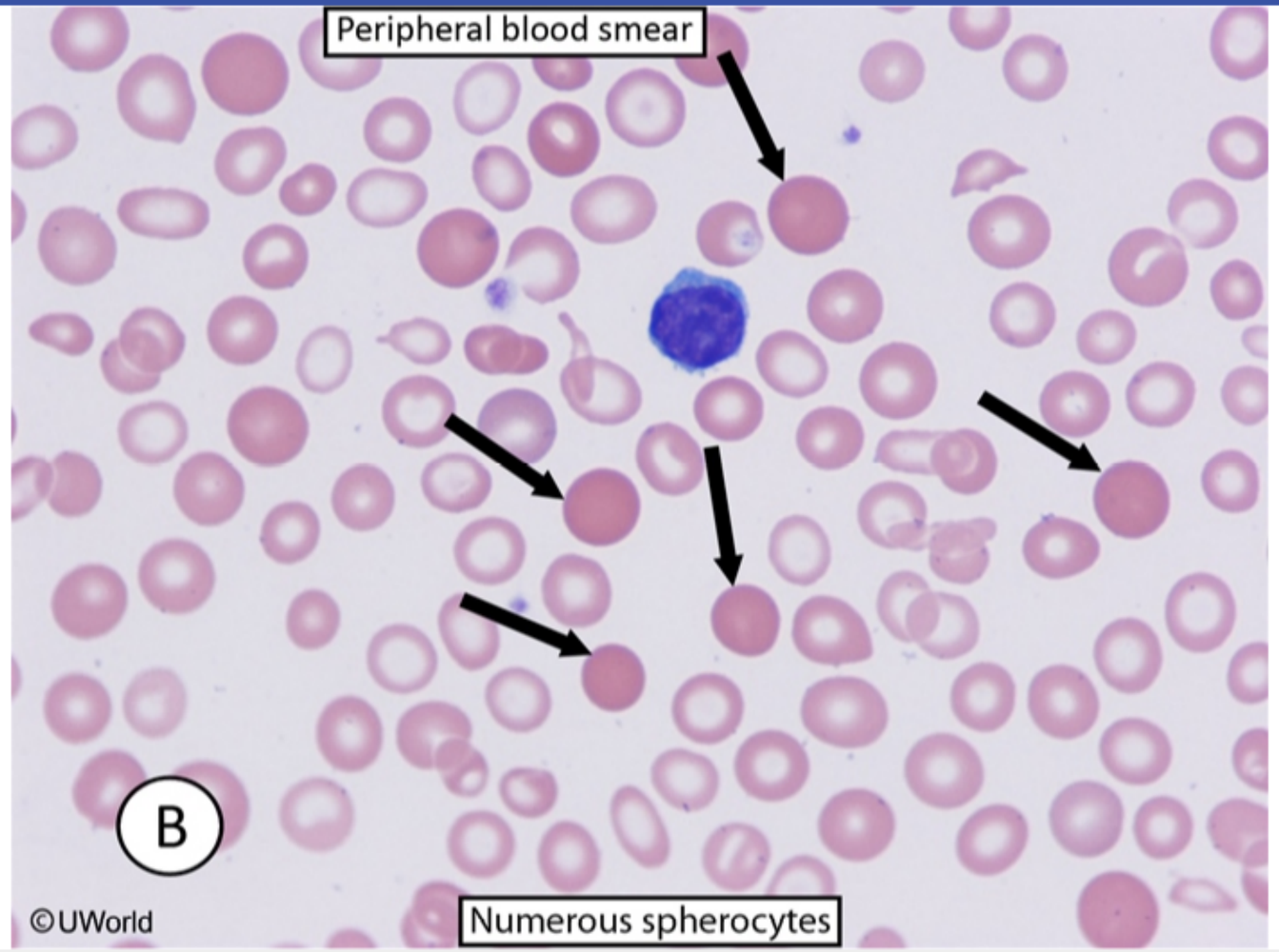

Zoom In | Zoom Out | Reset | Add To New Card | Existing Card

Target cells form when erythrocytes have reduced cell volume (eg, thalassemia, iron deficiency) or excessive membrane (eg, obstructive liver

1
2
3
4
5
6
7
8
9
10
11
12
13
14
15
16
17
18
19
20
21
22
23
24
25
26
27
28
29
30
31

Exhibit Display

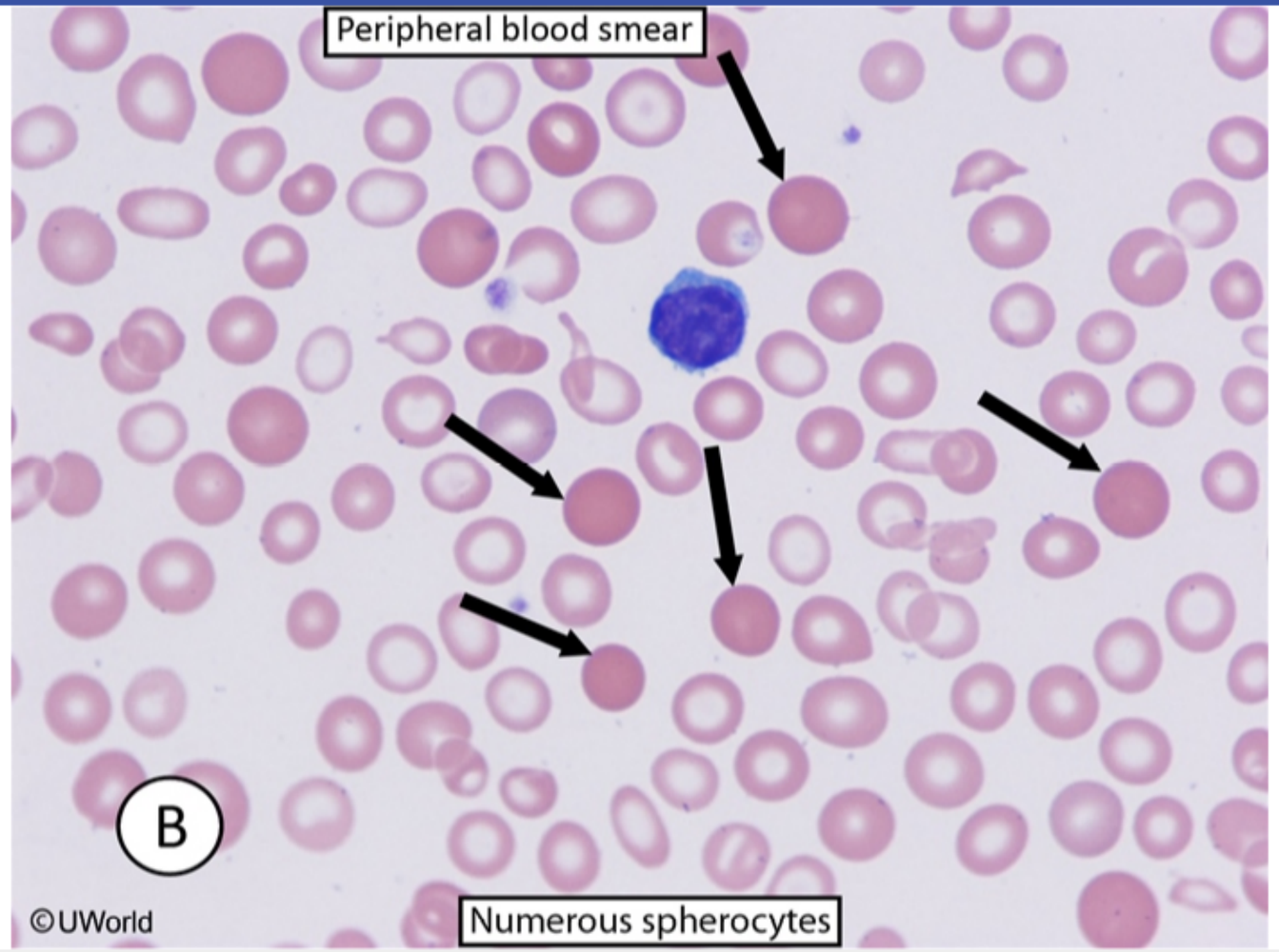

Zoom In | Zoom Out | Reset | Add To New Card | Existing Card

Target cells form when erythrocytes have reduced cell volume (eg, thalassemia, iron deficiency) or excessive membrane (eg, obstructive liver

excessive surface area-to-volume ratio, which results in redundant erythrocyte cell membrane folding upon itself (thereby creating the

Exhibit Display

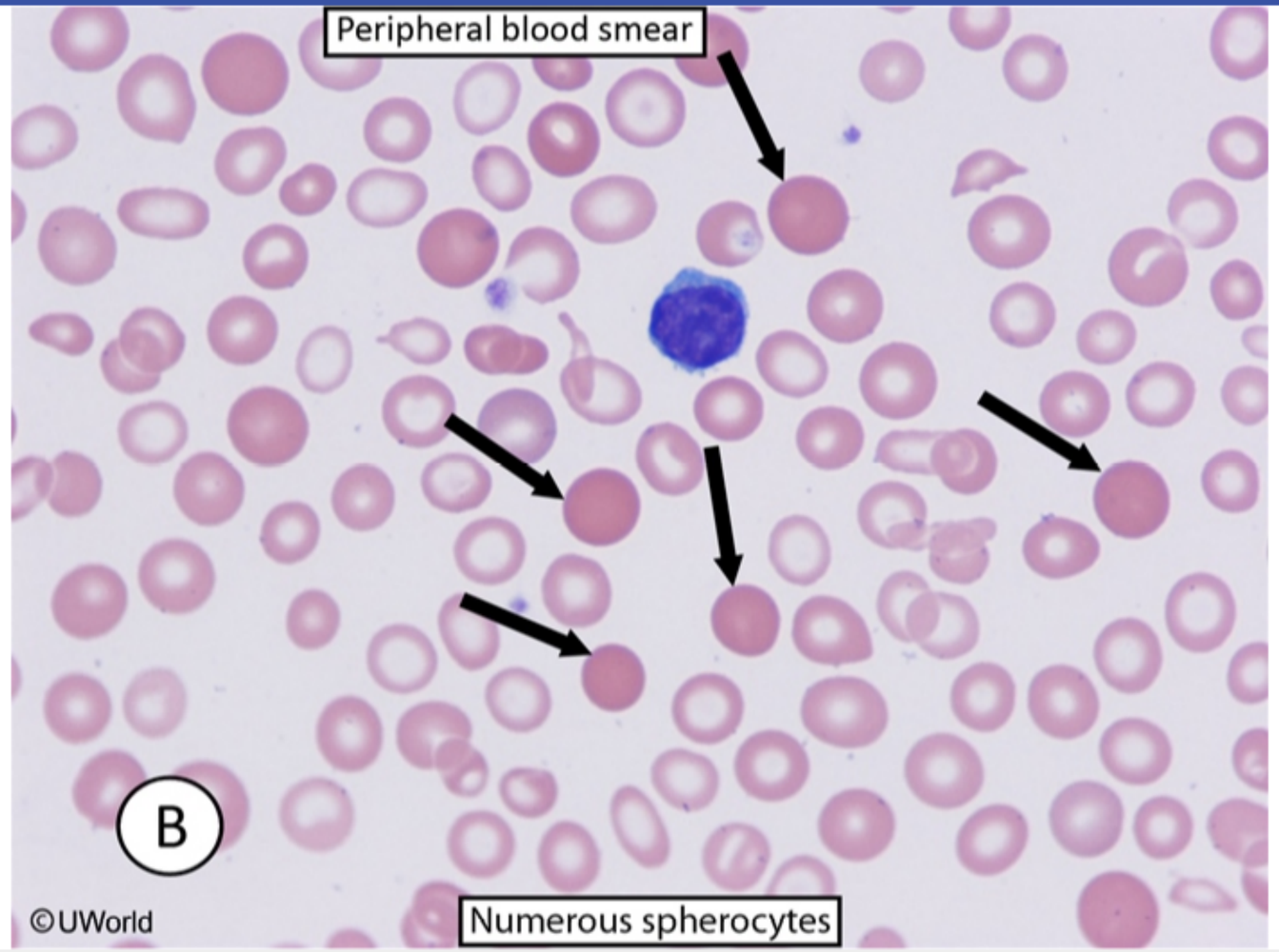

Zoom In | Zoom Out | Reset | Add To New Card | Existing Card

excessive red cell membrane.

excessive surface area-to-volume ratio, which results in redundant erythrocyte cell membrane folding upon itself (thereby creating the

Exhibit Display

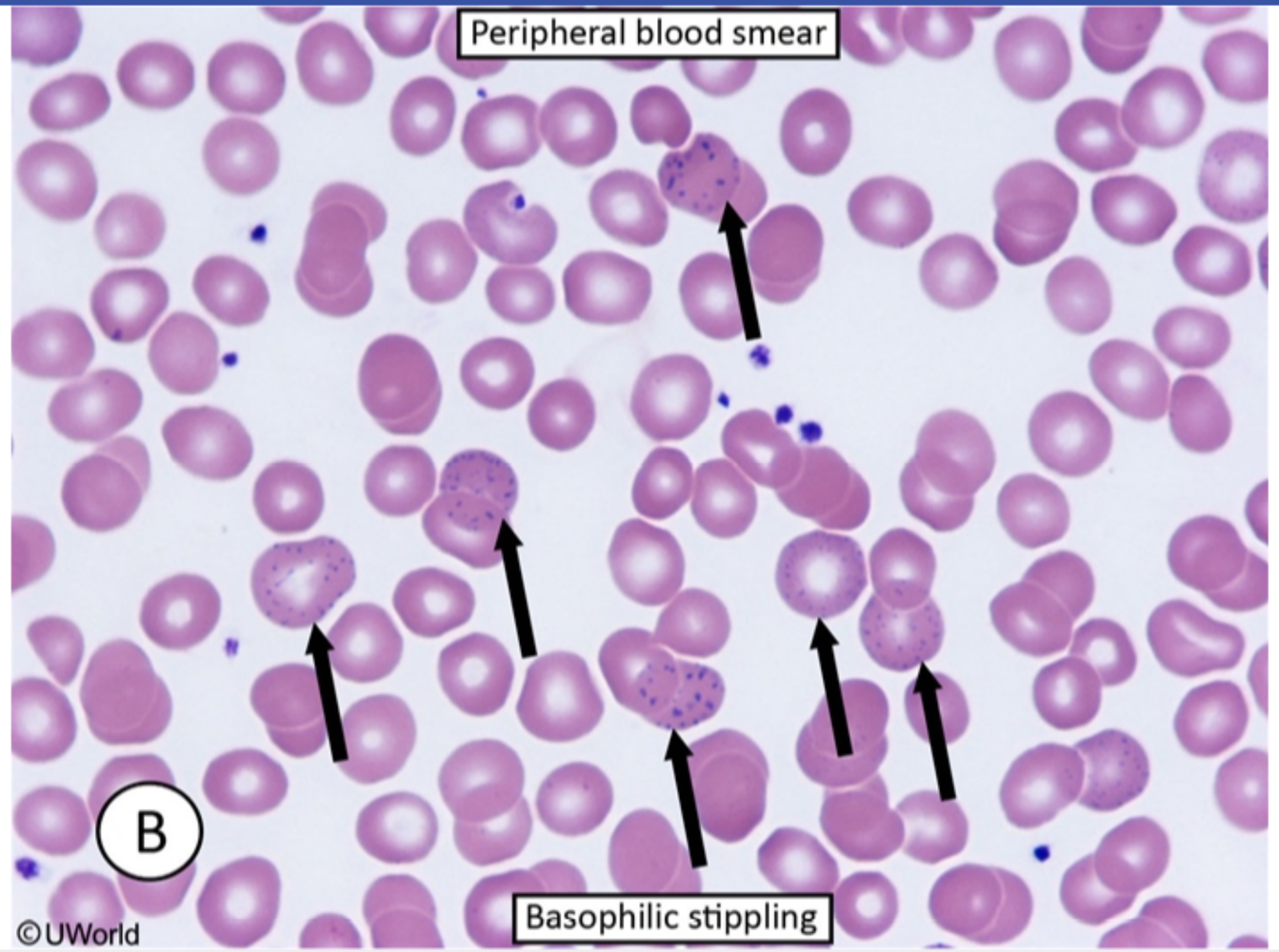

Zoom In | Zoom Out | Reset | Add To New Card | Existing Card

excessive red cell membrane.

1 2 3 4 5 6 7 8 9 10 11 12 13 14 15 16 17 18 19 20 21 22 23 24 25 26 27 28 29 30 31

Macrophages in the red pulp of the spleen remove excess membrane from red cells, a process called "**splenic conditioning**." Patients who undergo splenectomy are **unable to prune** erythrocytes and generally develop target cells a few weeks following the procedure. However, over time, macrophages in nonsplenic tissue (eg, liver) take up the task of pruning erythrocytes, which typically eliminates (or diminishes) the presence of target cells in the circulation.

(Choice A) Pappenheimer bodies are aggregated iron deposits in erythrocytes that are often seen in patients with sideroblastic anemia. They appear as dark blue inclusions.

(Choice B) Howell-Jolly bodies are clusters of DNA remnants in erythrocytes due to hyposplenism or asplenism (the spleen usually removes the DNA remnants). They appear as peripheral, round, dark purple, blue, or red inclusions.

(Choice C) Heinz bodies are aggregates of denatured hemoglobin that may be present in erythrocytes when patients have glucose-6-phosphate deficiency or thalassemia. They cannot be seen on routine staining.

(Choice D) Spherocytes have low surface area-to-volume ratios and are more susceptible to osmotic stress. They are seen most commonly in hemolytic anemia and hereditary spherocytosis and appear as dense, round red blood cells. Target cells are less susceptible to osmotic stress than normal red blood cells or spherocytes due to their excess membrane.

(Choice E) Basophilic stippling is blue granules dispersed within the cytosol of erythrocytes due to precipitated ribosomes. It is seen most commonly in thalassemias, alcohol abuse, and lead/heavy metal poisoning.

Educational objective:
Target cells form when erythrocytes have reduced cell volume (eg, thalassemia, iron deficiency) or excessive membrane (eg, obstructive liver disease, postsplenectomy). Patients who undergo splenectomy usually develop target cells because the spleen is the primary organ that prunes excessive red cell membrane.

Pathophysiology	Hematology & Oncology	Splenectomy
Subject	System	Topic

Copyright © UWorld. All rights reserved.

1
2
3
4
5
6
7
8
9
10
11
12
13
14
15
16
17
18
19
20
21
22
23
24
25
26
27
28
29
30
31

Physiologists conduct a study to evaluate erythropoiesis in various age groups. In one of the studies, healthy individuals who experience acute traumatic blood loss are enrolled. They divide the patients in 2 groups: younger individuals with a mean age of 35 years and older adults with a mean age of 70. These patients have normal iron, folic acid, vitamin B_{12}, and plasma protein studies. Results indicate that older patients with acute traumatic blood loss have a much lower reticulocyte count and a much longer time to recovery to pretrauma hemoglobin level when compared to younger patients. Which of the following age-related processes best explains the observed findings?

A. Decreased bone marrow mass

B. Decreased medullary cavity size

C. Decreased red blood cell life span

D. Increased extramedullary hematopoiesis

E. Increased marrow fibrous tissue

Submit

Physiologists conduct a study to evaluate erythropoiesis in various age groups. In one of the studies, healthy individuals who experience acute traumatic blood loss are enrolled. They divide the patients in 2 groups: younger individuals with a mean age of 35 years and older adults with a mean age of 70. These patients have normal iron, folic acid, vitamin B_{12}, and plasma protein studies. Results indicate that older patients with acute traumatic blood loss have a much lower reticulocyte count and a much longer time to recovery to pretrauma hemoglobin level when compared to younger patients. Which of the following age-related processes best explains the observed findings?

- ✓ A. Decreased bone marrow mass (59%)
- B. Decreased medullary cavity size (6%)
- C. Decreased red blood cell life span (1%)
- D. Increased extramedullary hematopoiesis (1%)
- E. Increased marrow fibrous tissue (31%)

Omitted
Correct answer
A

59%
Answered correctly

02 secs
Time Spent

05/13/2020
Last Updated

Explanation

Although patients with advanced age typically have normal serum blood counts, age-related changes in cytokine signaling and the cellular composition of the bone marrow **impairs the generation of new cells** in response to acute stressors such as **blood loss** or hypoxia. When compared to younger patients, the bone marrow of older patients has a **higher quantity of fat** and a **reduced overall mass**, which limits the functional reserve of hematopoietic cells. In addition, hematopoietic progenitor cell diversity and the response to stimulatory cytokines (eg, stem-cell factor, granulocyte macrophage colony-stimulating factor) are also impaired, thereby limiting the generation of new cells in response to stress.

1
2
3
4
5
6
7
8
9
10
11
12
13
14
15
16
17
18
19
20
21
22
23
24
25
26
27
28
29
30
31

Explanation

Although patients with advanced age typically have normal serum blood counts, age-related changes in cytokine signaling and the cellular composition of the bone marrow **impairs the generation of new cells** in response to acute stressors such as **blood loss** or hypoxia. When compared to younger patients, the bone marrow of older patients has a **higher quantity of fat** and a **reduced overall mass**, which limits the functional reserve of hematopoietic cells. In addition, hematopoietic progenitor cell diversity and the response to stimulatory cytokines (eg, stem-cell factor, granulocyte macrophage colony-stimulating factor) are also impaired, thereby limiting the generation of new cells in response to stress. Because of these changes, older individuals cannot rapidly generate new blood cells.

(Choice B) Patients with advanced age generally have increased (not decreased) medullary cavity size due to loss of endosteal cortical bone. This increases the risk of fractures.

(Choice C) Red blood cell life span is preserved in patients with advanced age; therefore, healthy older individuals usually have normal hemoglobin level. However, they are much less capable of generating new erythrocytes in times of blood loss or other stressors (eg, hemolysis).

(Choice D) Extramedullary hematopoiesis is common in newborns but does not generally occur in older patients unless there is insufficient marrow space for hematopoietic cell proliferation. Therefore, extramedullary hematopoiesis is typically associated with significant bone marrow pathology (eg, myelofibrosis).

(Choice E) Although bone marrow fat increases with age, bone marrow fibrosis is not a part of normal aging. Bone marrow fibrosis is associated with primary myelofibrosis, a chronic myeloproliferative disorder marked by anemia and extramedullary hematopoiesis (hepatosplenomegaly).

Educational objective:
Patients of advanced age have increased bone marrow fat and reduced bone marrow mass, leading to impaired bone marrow reserve. This results in an inability to rapidly generate new blood cells in response to acute stress (eg, blood loss, hypoxia).

Pathophysiology	Hematology & Oncology	Aging
Subject	System	Topic

Copyright © UWorld. All rights reserved.

1
2
3
4
5
6
7
8
9
10
11
12
13
14
15
16
17
18
19
20
21
22
23
24
25
26
27
28
29
30
31

A 66-year-old man comes to the office due to several weeks of back and lower extremity pain. The pain feels dull and achy and is worsened by movement, causing him to have difficulty bearing weight and ambulating. He has had no bladder or bowel dysfunction, extremity weakness, or numbness. The patient takes metformin for type 2 diabetes mellitus. He drinks 2 alcoholic beverages daily. Physical examination shows no gross abnormality or deformity of the back or extremities. There is no swelling or redness of the legs, and neurological examination is normal. A radiograph of the right lower extremity is shown in the exhibit. Laboratory results are as follows:

Hemoglobin	9.6 g/dL
Mean corpuscular volume	92/μm³
Creatinine	1.6 mg/dL
Calcium	11.0 mg/dL
Glucose	220 mg/dL
Total protein	8.8 g/dL
Albumin	3.8 g/dL

Which of the following is the most likely explanation for this patient's bone changes?

A. Decreased urinary calcium excretion

B. Increased 1,25-dihydroxyvitamin D production

C. Increased secretion of parathyroid hormone

D. Local tumor cell–mediated activation of osteoblasts

E. Local tumor cell–mediated activation of osteoclasts

1
2
3
4
5
6
7
8
9
10
11
12
13
14
15
16
17
18
19
20
21
22
23
24
25
26
27
28
29
30
31

Exhibit Display

Zoom In | Zoom Out | Reset | Add To New Card | Existing Card

movement, causing him to have difficulty bearing weight and ambulating. He has had no bladder or bowel dysfunction, extremity weakness, or numbness. The patient takes metformin for type 2 diabetes mellitus. He drinks 2 alcoholic beverages daily. Physical examination shows no gross abnormality or deformity of the back or extremities. There is no swelling or redness of the legs, and neurological examination is normal. A radiograph of the right lower extremity is shown in the exhibit. Laboratory results are as follows:

Hemoglobin	9.6 g/dL
Mean corpuscular volume	92/μm³
Creatinine	1.6 mg/dL
Calcium	11.0 mg/dL
Glucose	220 mg/dL
Total protein	8.8 g/dL
Albumin	3.8 g/dL

Which of the following is the most likely explanation for this patient's bone changes?

A. Decreased urinary calcium excretion
B. Increased 1,25-dihydroxyvitamin D production
C. Increased secretion of parathyroid hormone
D. Local tumor cell–mediated activation of osteoblasts
E. Local tumor cell–mediated activation of osteoclasts

Submit

movement, causing him to have difficulty bearing weight and ambulating. He has had no bladder or bowel dysfunction, extremity weakness, or numbness. The patient takes metformin for type 2 diabetes mellitus. He drinks 2 alcoholic beverages daily. Physical examination shows no gross abnormality or deformity of the back or extremities. There is no swelling or redness of the legs, and neurological examination is normal. A radiograph of the right lower extremity is shown in the exhibit. Laboratory results are as follows:

Hemoglobin	9.6 g/dL
Mean corpuscular volume	92/μm³
Creatinine	1.6 mg/dL
Calcium	11.0 mg/dL
Glucose	220 mg/dL
Total protein	8.8 g/dL
Albumin	3.8 g/dL

Which of the following is the most likely explanation for this patient's bone changes?

A. Decreased urinary calcium excretion (4%)
B. Increased 1,25-dihydroxyvitamin D production (2%)
C. Increased secretion of parathyroid hormone (27%)
D. Local tumor cell–mediated activation of osteoblasts (7%)
✓ E. Local tumor cell–mediated activation of osteoclasts (58%)

Omitted
Correct answer
58%
10 secs
03/08/2020

1
2
3
4
5
6
7
8
9
10
11
12
13
14
15
16
17
18
19
20
21
22
23
24
25
26
27
28
29
30
31

Osteoclast differentiation

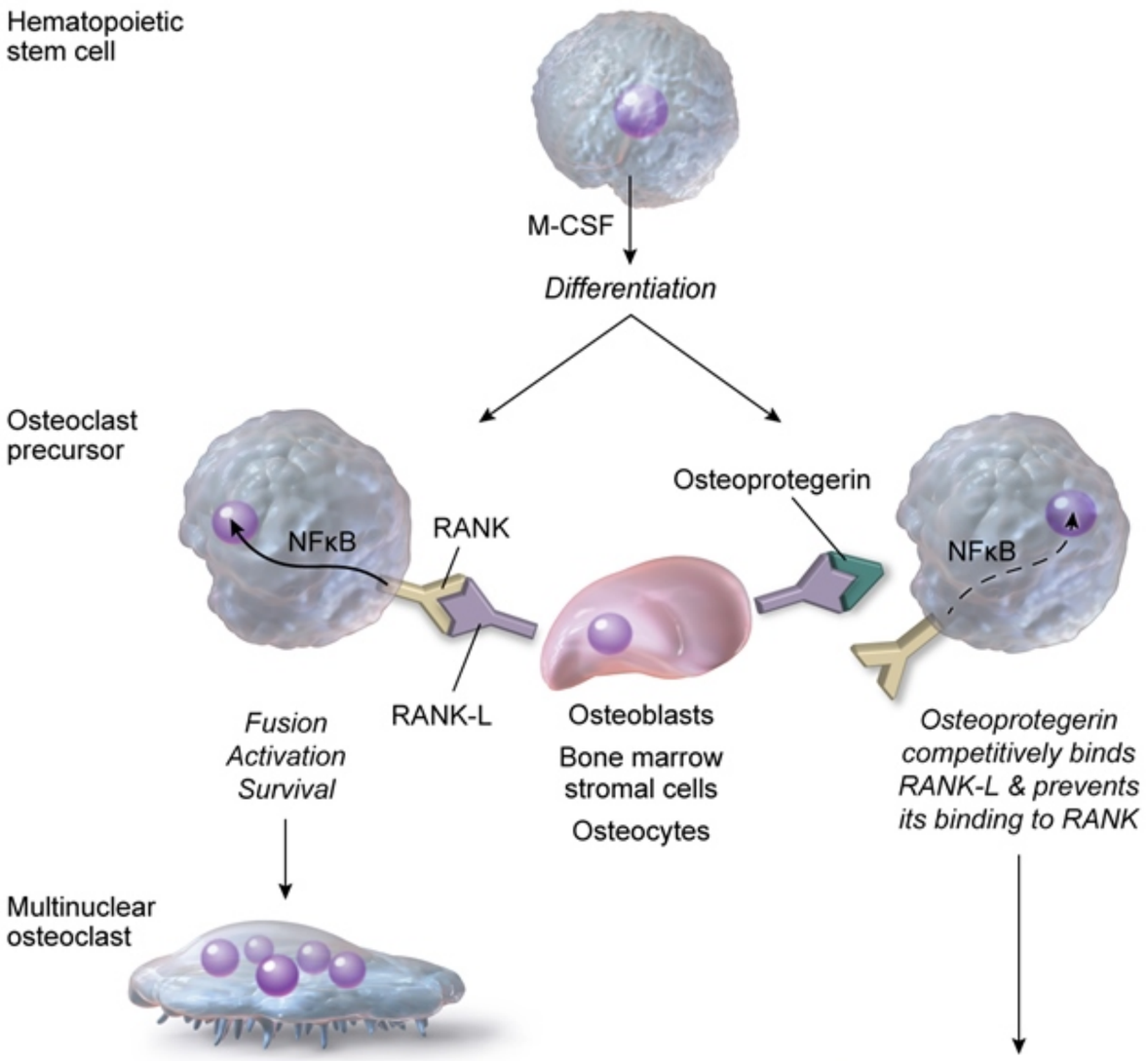

1
2
3
4
5
6
7
8
9
10
11
12
13
14
15
16
17
18
19
20
21
22
23
24
25
26
27
28
29
30
31

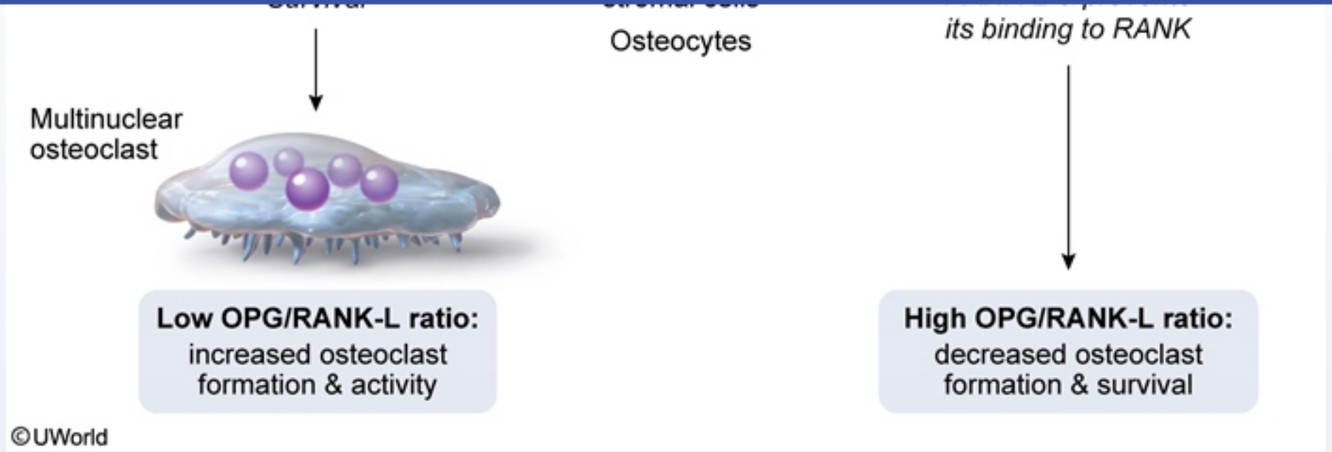

This patient with mild renal insufficiency, normocytic anemia, hypercalcemia, and bone pain has the classic manifestations of **multiple myeloma** (MM), a plasma cell malignancy associated with excessive production of monoclonal immunoglobulin (paraprotein). Myeloma cells replicate in the bone marrow and release cytokines that stimulate osteoclasts and inhibit osteoblasts, which leads to the generation of purely osteolytic (radiolucent) bone lesions.

Bone remodeling is tightly regulated by osteocytes (stromal bone marrow cells that are embedded within the lacuna-canalicular network) in conjunction with signals from the bone marrow and the bone surface. The RANK/RANKL pathway plays a prominent role. RANK is a transmembrane receptor on the surface of osteoclast precursors, which is activated by RANK-ligand (RANKL) produced by osteocytes. **Activation of RANK** leads to the differentiation of osteoclast precursors into mature osteoclasts.

Myeloma cells stimulate osteoclast maturation by producing RANKL and by destroying OPG (mediated by a secreted proteoglycan). They also uniquely inhibit osteoblast activity by secreting cytokines that block osteoblast function (eg, IL-3, IL-7, Wnt pathway inhibitors). This tilts the balance of bone remodeling strongly toward **osteolytic bone destruction**, which results in many of the characteristic findings seen in MM, including bone pain, **hypercalcemia** (liberation of calcium during osteolysis), and purely radiolucent (osteolytic) bone lesions.

(Choice A) Decreased urinary calcium excretion can be seen with thiazide diuretic use and can result in hypercalcemia. However, this effect is associated with an increase in bone density; radiolucent bone lesions would not be seen.

(Choices B and C) 1,25 dihydroxyvitamin D and parathyroid hormone break down bone by increasing RANKL and decreasing OPG expression.

transmembrane receptor on the surface of osteoclast precursors, which is activated by RANK-ligand (RANKL) produced by osteocytes. **Activation of RANK** leads to the differentiation of osteoclast precursors into mature osteoclasts.

Myeloma cells stimulate osteoclast maturation by producing RANKL and by destroying OPG (mediated by a secreted proteoglycan). They also uniquely inhibit osteoblast activity by secreting cytokines that block osteoblast function (eg, IL-3, IL-7, Wnt pathway inhibitors). This tilts the balance of bone remodeling strongly toward **osteolytic bone destruction**, which results in many of the characteristic findings seen in MM, including bone pain, **hypercalcemia** (liberation of calcium during osteolysis), and purely radiolucent (osteolytic) bone lesions.

(Choice A) Decreased urinary calcium excretion can be seen with thiazide diuretic use and can result in hypercalcemia. However, this effect is associated with an increase in bone density; radiolucent bone lesions would not be seen.

(Choices B and C) 1,25 dihydroxyvitamin D and parathyroid hormone break down bone by increasing RANKL and decreasing OPG expression. Although vitamin D toxicosis and hyperparathyroidism can be associated with hypercalcemia, they are not associated with anemia or elevations in total serum protein.

(Choice D) Several tumors that spread to the bones stimulate osteoclasts, but only myeloma cells also inhibit osteoblasts. Therefore, myeloma cells are one of the few tumors to cause purely osteolytic (radiolucent) lesions. Most other tumors have at least some areas of sclerosis (osteoblastic activity).

Educational objective:
Multiple myeloma is a plasma cell malignancy associated with purely radiolucent (osteolytic) bone lesions due to the stimulation of osteoclasts and the inhibition of osteoblasts. Myeloma cells stimulate osteoclast development by secreting RANK-ligand and destroying osteoprotegerin, which increases RANK activity and results in osteoclast differentiation.

References

- Pathogenesis of bone disease in multiple myeloma: from bench to bedside.

Pathophysiology	Hematology & Oncology	Multiple myeloma
Subject	System	Topic

Copyright © UWorld. All rights reserved.

1
2
3
4
5
6
7
8
9
10
11
12
13
14
15
16
17
18
19
20
21
22
23
24
25
26
27
28
29
30
31

Exhibit Display

Zoom In
Zoom Out
Reset
Add To New Card | Existing Card

1
2
3
4
5
6
7
8
9
10
11
12
13
14
15
16
17
18
19
20
21
22
23
24
25
26
27
28
29
30
31

Exhibit Display

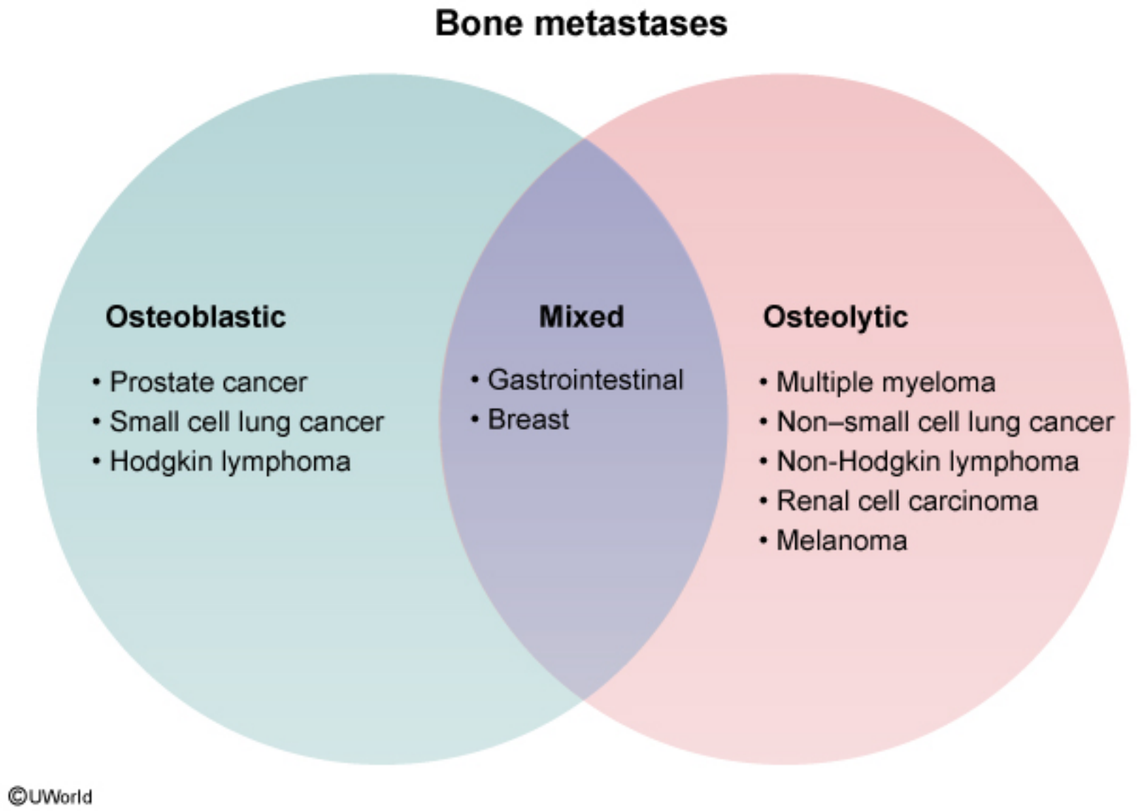

Zoom In | Zoom Out | Reset | Add To New Card | Existing Card

transmembrane receptor on the surface of osteoclast precursors, which is activated by RANK-ligand (RANKL) produced by osteocytes. **Activation of RANK** leads to the differentiation of osteoclast precursors into mature osteoclasts.

Myeloma cells stimulate osteoclast maturation by producing RANKL and by destroying OPG (mediated by a secreted proteoglycan). They also uniquely inhibit osteoblast activity by secreting cytokines that block osteoblast function (eg, IL-3, IL-7, Wnt pathway inhibitors). This tilts the balance of bone remodeling strongly toward **osteolytic bone destruction**, which results in many of the characteristic findings seen in MM, including bone pain, **hypercalcemia** (liberation of calcium during osteolysis), and purely radiolucent (osteolytic) bone lesions.

(Choice A) Decreased urinary calcium excretion can be seen with thiazide diuretic use and can result in hypercalcemia. However, this effect is associated with an increase in bone density; radiolucent bone lesions would not be seen.

(Choices B and C) 1,25 dihydroxyvitamin D and parathyroid hormone break down bone by increasing RANKL and decreasing OPG expression. Although vitamin D toxicosis and hyperparathyroidism can be associated with hypercalcemia, they are not associated with anemia or elevations in total serum protein.

(Choice D) Several tumors that spread to the bones stimulate osteoclasts, but only myeloma cells also inhibit osteoblasts. Therefore, myeloma cells are one of the few tumors to cause purely osteolytic (radiolucent) lesions. Most other tumors have at least some areas of sclerosis (osteoblastic activity).

Educational objective:
Multiple myeloma is a plasma cell malignancy associated with purely radiolucent (osteolytic) bone lesions due to the stimulation of osteoclasts and the inhibition of osteoblasts. Myeloma cells stimulate osteoclast development by secreting RANK-ligand and destroying osteoprotegerin, which increases RANK activity and results in osteoclast differentiation.

References

- Pathogenesis of bone disease in multiple myeloma: from bench to bedside.

Pathophysiology	Hematology & Oncology	Multiple myeloma
Subject	System	Topic

Copyright © UWorld. All rights reserved.

A 65-year-old man comes to the office due to a few weeks of progressive exertional dyspnea and fatigue. He has had no chest pain, fever, or cough. The patient has a history of mild aortic stenosis, gastroesophageal reflux disease, obesity, hypertension, and hypercholesterolemia. Temperature is 36.7 C (98 F), blood pressure is 130/78 mm Hg, pulse is 82/min, and respirations are 16/min. BMI is 28 kg/m^2. Pulse oximetry shows 96% on room air. Mucosal pallor is present, but there is no jaundice, lymphadenopathy, or jugular venous distension. Cardiopulmonary examination reveals a 2/6 systolic ejection murmur at the second right intercostal area. The abdomen is soft and nontender; there is no palpable hepatosplenomegaly. Peripheral pulses are normal. Laboratory results are as follows:

Complete blood count

Hemoglobin	7.8 g/dL
Platelets	98,000/mm^3
Leukocytes	3,800/mm^3

Peripheral blood smear is shown below:

Which of the following is most likely responsible for this patient's current condition?

- A. Impaired DNA synthesis
- B. Impaired heme production
- C. Inadequate erythropoietin production
- D. Replacement of bone marrow with fat cells
- E. Replacement of bone marrow with fibrosis
- F. Traumatic hemolysis

1
2
3
4
5
6
7
8
9
10
11
12
13
14
15
16
17
18
19
20
21
22
23
24
25
26
27
28
29
30
31

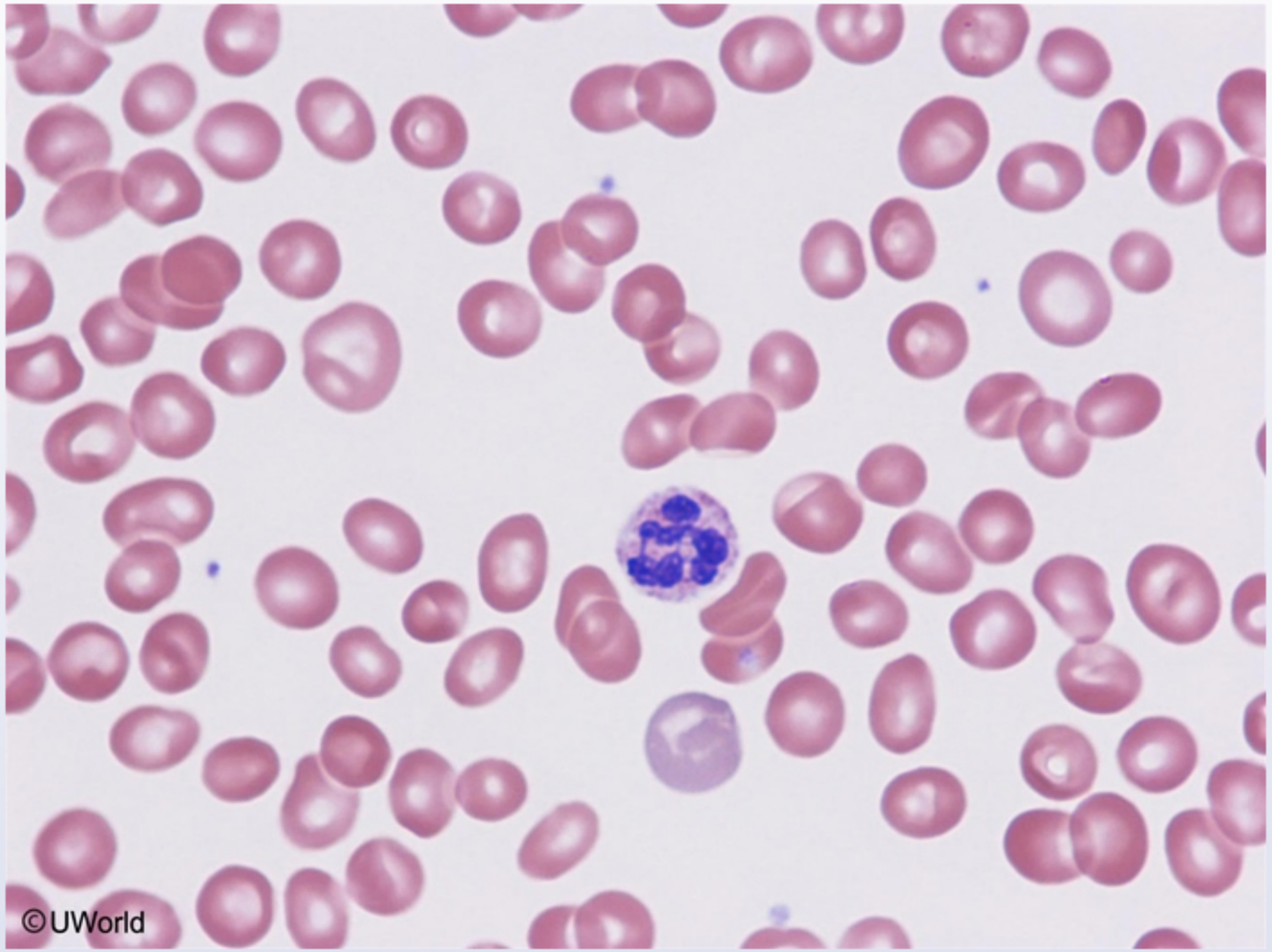

Which of the following is most likely responsible for this patient's current condition?

A. Impaired DNA synthesis

B. Impaired heme production

1
2
3
4
5
6
7
8
9
10
11
12
13
14
15
16
17
18
19
20
21
22
23
24
25
26
27
28
29
30
31

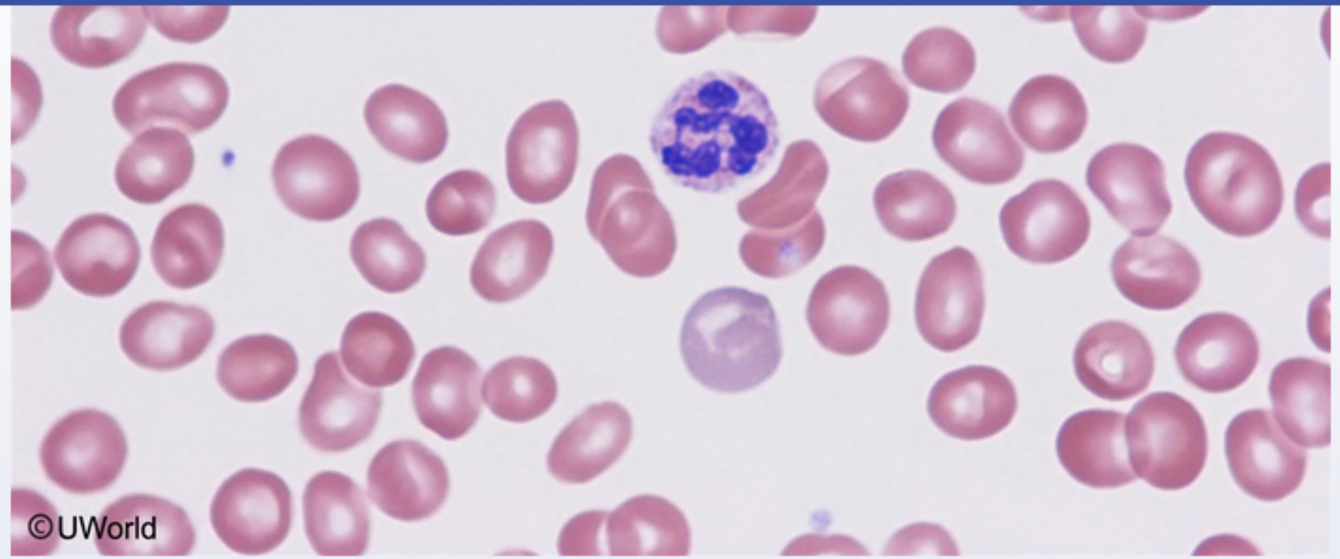

Which of the following is most likely responsible for this patient's current condition?

- A. Impaired DNA synthesis
- B. Impaired heme production
- C. Inadequate erythropoietin production
- D. Replacement of bone marrow with fat cells
- E. Replacement of bone marrow with fibrosis
- F. Traumatic hemolysis

Submit

1
2
3
4
5
6
7
8
9
10
11
12
13
14
15
16
17
18
19
20
21
22
23
24
25
26
27
28
29
30
31

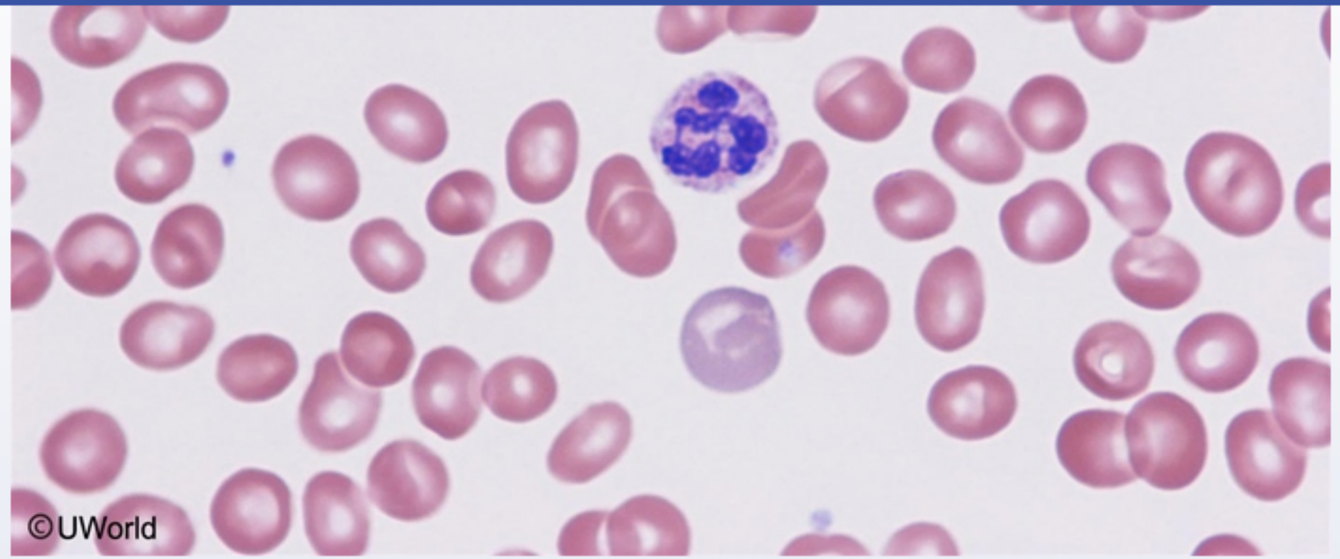

Which of the following is most likely responsible for this patient's current condition?

- A. Impaired DNA synthesis (70%)
- B. Impaired heme production (5%)
- C. Inadequate erythropoietin production (2%)
- D. Replacement of bone marrow with fat cells (9%)
- E. Replacement of bone marrow with fibrosis (7%)
- F. Traumatic hemolysis (4%)

Omitted
Correct answer

70%
Answered correctly

09 secs
Time Spent

06/02/2020
Last Updated

1
2
3
4
5
6
7
8
9
10
11
12
13
14
15
16
17
18
19
20
21
22
23
24
25
26
27
28
29
30
31

Macrocytic anemia

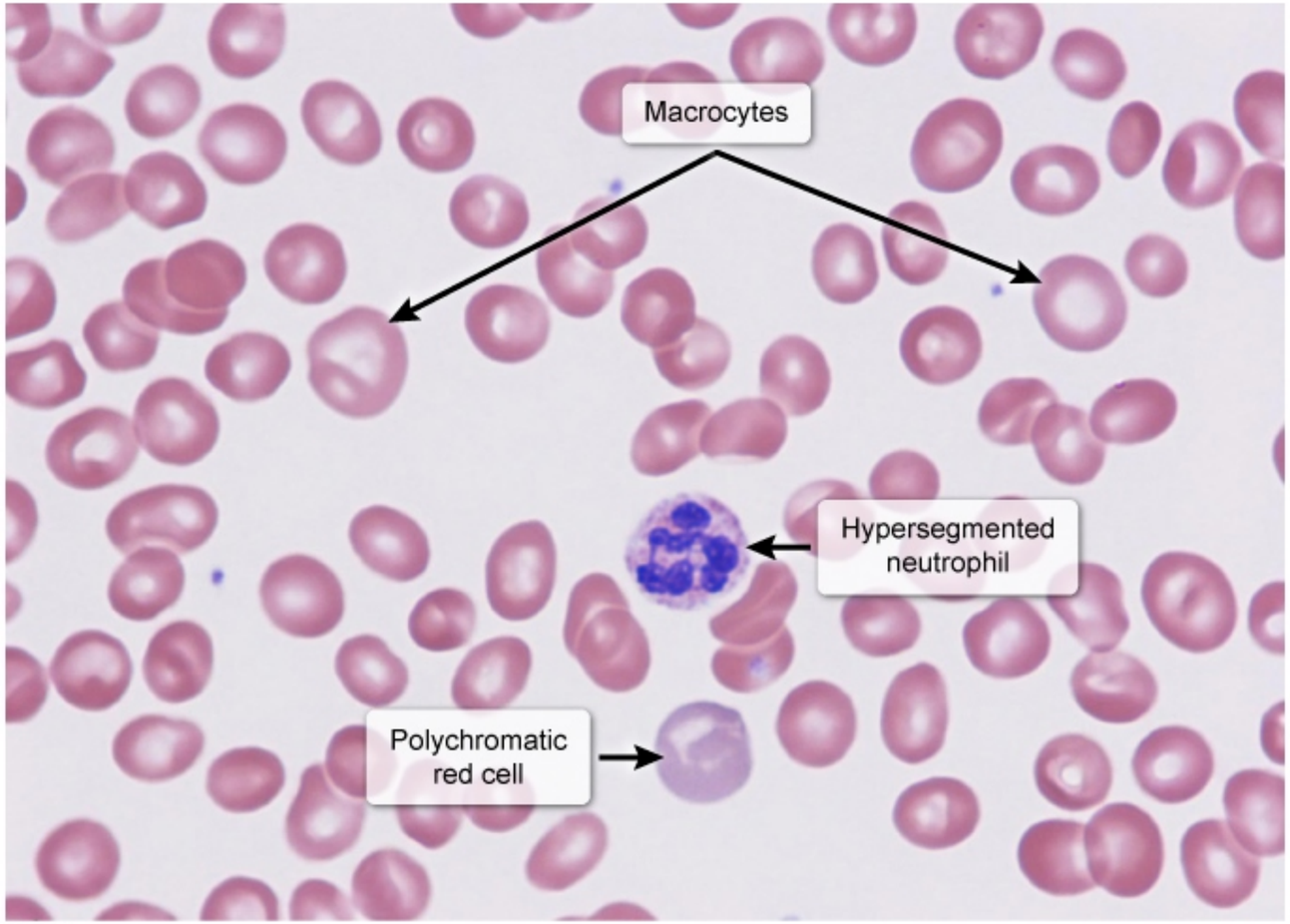

©UWorld

This patient with exertional dyspnea, fatigue, conjunctival pallor, and a systolic ejection murmur has symptomatic anemia. The presence peripheral blood smear findings of **macrocytosis** and a **hypersegmented neutrophil** indicate likely **megaloblastic anemia**. This condition

©UWorld

This patient with exertional dyspnea, fatigue, conjunctival pallor, and a systolic ejection murmur has symptomatic anemia. The presence peripheral blood smear findings of **macrocytosis** and a **hypersegmented neutrophil** indicate likely **megaloblastic anemia**. This condition sometimes arises in older individuals who take antacids for gastroesophageal reflux disease, as gastric acid is required for proper vitamin B_{12} absorption.

Vitamin B_{12} acts as a cofactor in the recycling of 5-methyl-tetrahydrofolate to tetrahydrofolate (reduced form of folate), which serves as a one-carbon donor in the synthesis of amino acids, purines, and thymidine monophosphate. Therefore, folate or **vitamin B_{12} deficiency** reduces available purines and thymidine, which **impairs DNA synthesis** and causes cell cycle arrest (in S-phase) or apoptotic cell death.

Hematopoietic cells are primarily affected due to their high replication rate. In these cells, nuclear division slows relative to cytoplasmic maturation (nuclear-cytoplasmic desynchrony), which results in **megaloblastic changes** (eg, macrocytosis, hypersegmented neutrophils); in addition, increased apoptosis causes **anemia** and often **mild thrombocytopenia/leukopenia**.

(Choice B) Iron deficiency anemia is associated with impaired production of heme; however, peripheral blood smear would show microcytosis (not macrocytosis), and no hypersegmented neutrophils would be seen.

(Choice C) Chronic kidney disease can reduce production of erythropoietin in the peritubular cells of the kidney, which causes normocytic anemia due to reduced erythropoiesis. However, leukopenia and thrombocytopenia are not typically seen, and peripheral blood smear would not show megaloblastic changes.

(Choice D) Aplastic anemia is associated with destruction of hematopoietic stem cells and replacement of the bone marrow with fat cells. Although patients usually have pancytopenia, peripheral blood smear would not show macrocytosis or hypersegmented neutrophils.

(Choice E) Primary myelofibrosis is a chronic myeloproliferative disorder characterized by fibrosis of the bone marrow. Anemia is common but patients usually have dacrocytes (tear-drop cells) and nucleated red blood cells on peripheral blood smear, not macrocytosis and hypersegmented neutrophils.

(Choice F) Aortic stenosis can sometimes cause traumatic hemolysis due to red blood cell shearing. However, peripheral smear generally shows schistocytes, and thrombocytopenia/leukopenia would be unusual.

Educational objective:

©UWorld

Exhibit Display

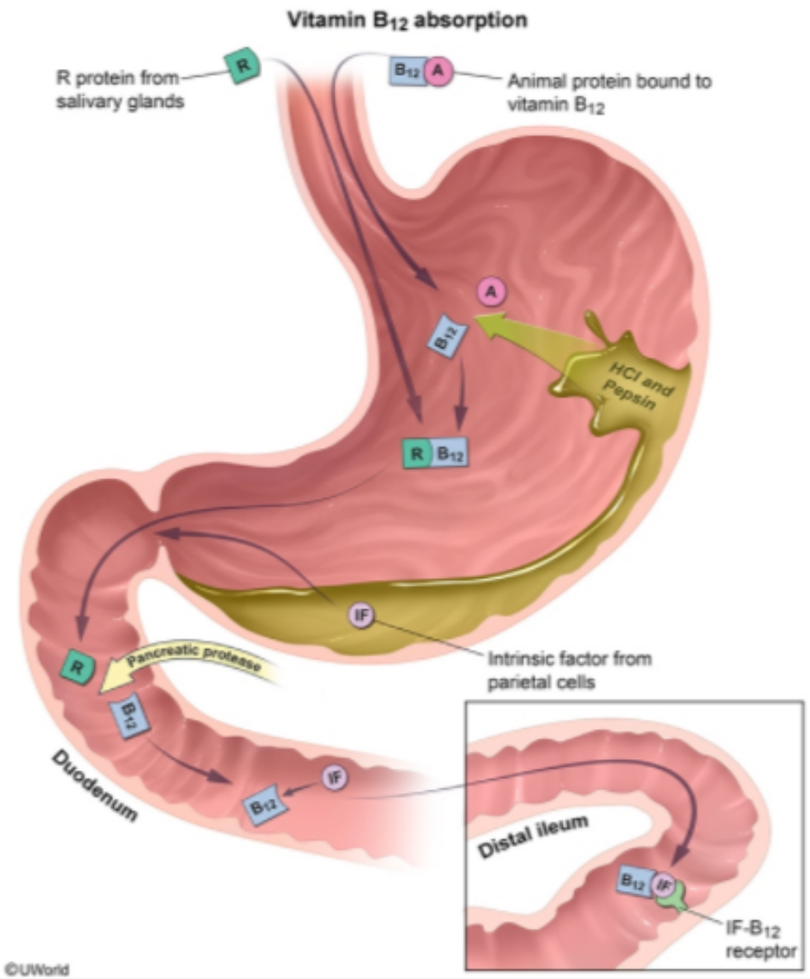

Zoom In | Zoom Out | Reset | Add To New Card | Existing Card

Educational objective:

©UWorld

Exhibit Display

Iron deficiency anemia

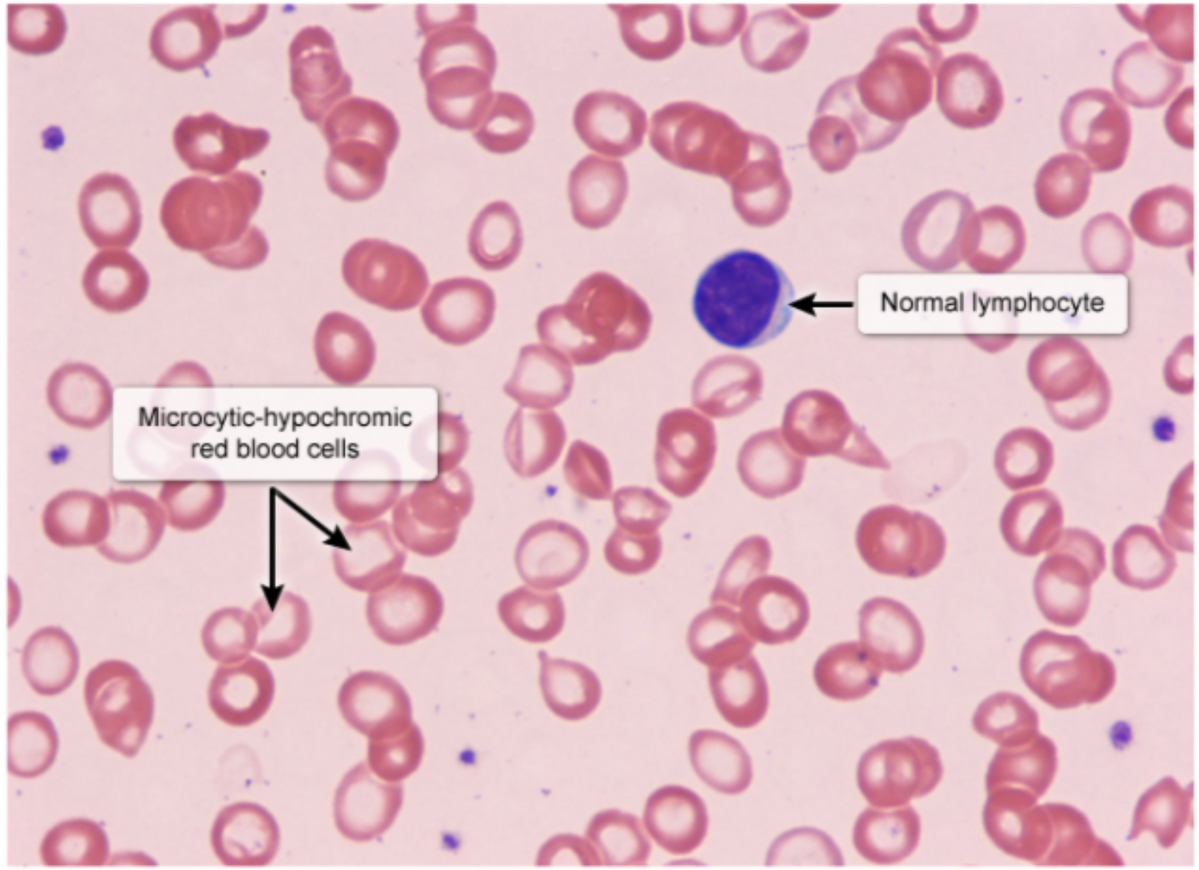

©UWorld

Zoom In | Zoom Out | Reset | Add To New Card | Existing Card

Educational objective:

1
2
3
4
5
6
7
8
9
10
11
12
13
14
15
16
17
18
19
20
21
22
23
24
25
26
27
28
29
30
31

Exhibit Display

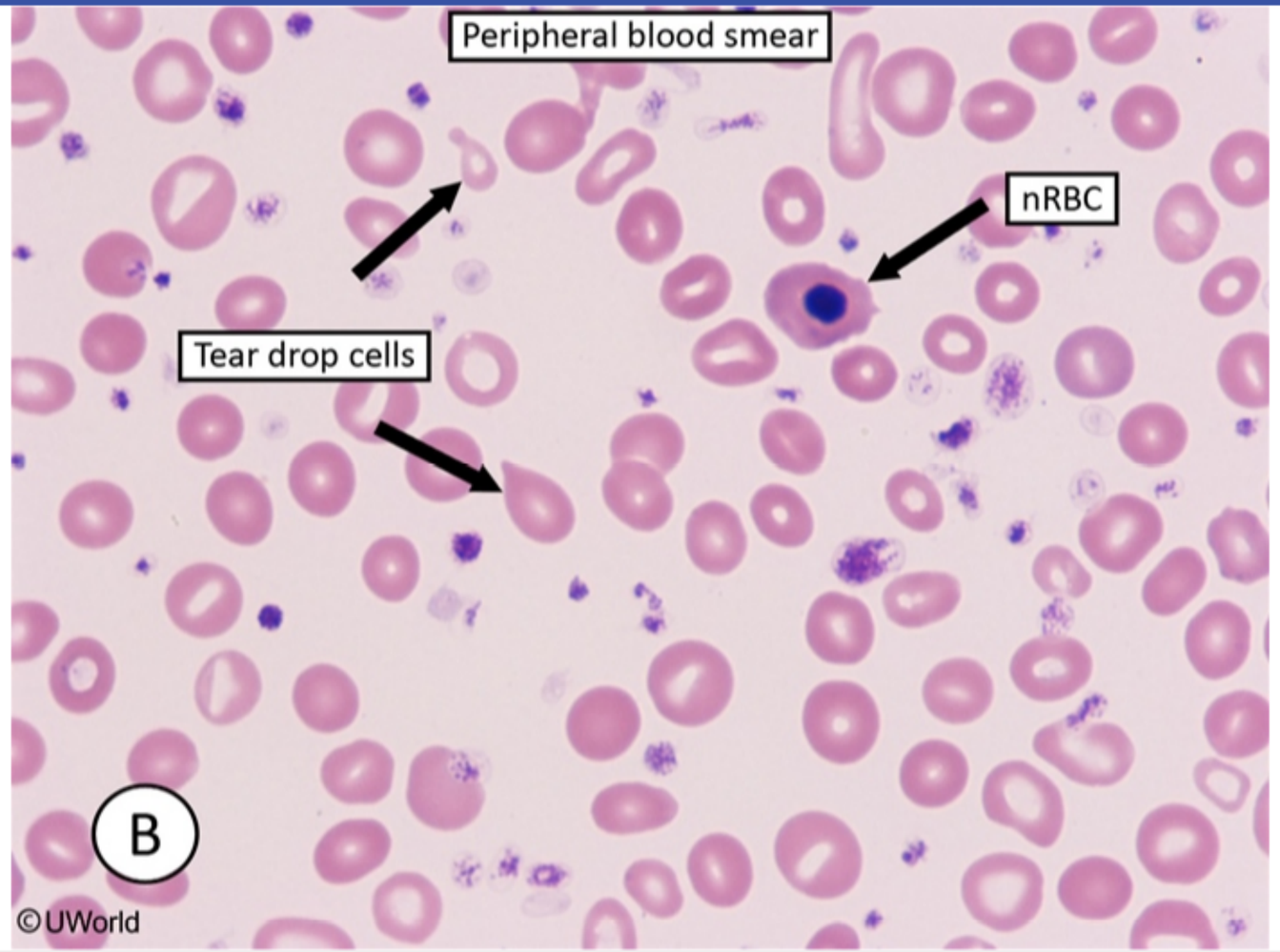

Zoom In | Zoom Out | Reset | Add To New Card | Existing Card

Copyright © UWorld. All rights reserved.

1
2
3
4
5
6
7
8
9
10
11
12
13
14
15
16
17
18
19
20
21
22
23
24
25
26
27
28
29
30
31

A 47-year-old woman comes to the office with a red rash on her breast that has been present for approximately 2 months. The rash is itchy, and the skin feels rough to the touch. The itching has worsened in the past few weeks, and moisturizers have provided no relief. The patient has a history of surgery for bilateral silicone breast implants 10 years ago. Temperature is 37 C (98.6 F). Physical examination shows redness and swelling of the right breast without any discrete masses. The overlying skin is indurated with a dimpled texture, and several enlarged, hard lymph nodes are palpated in the right axilla. The left breast is normal. Which of the following is the most likely cause of this patient's skin changes?

A. Deep venous thrombosis

B. Foreign body reaction

C. Infectious process

D. Lymphatic obstruction

E. Scar formation

Submit

1
2
3
4
5
6
7
8
9
10
11
12
13
14
15
16
17
18
19
20
21
22
23
24
25
26
27
28
29
30
31

A 47-year-old woman comes to the office with a red rash on her breast that has been present for approximately 2 months. The rash is itchy, and the skin feels rough to the touch. The itching has worsened in the past few weeks, and moisturizers have provided no relief. The patient has a history of surgery for bilateral silicone breast implants 10 years ago. Temperature is 37 C (98.6 F). Physical examination shows redness and swelling of the right breast without any discrete masses. The overlying skin is indurated with a dimpled texture, and several enlarged, hard lymph nodes are palpated in the right axilla. The left breast is normal. Which of the following is the most likely cause of this patient's skin changes?

- A. Deep venous thrombosis (0%)
- B. Foreign body reaction (19%)
- C. Infectious process (8%)
- ✓ D. Lymphatic obstruction (68%)
- E. Scar formation (3%)

Omitted
Correct answer
D

68%
Answered correctly

02 secs
Time Spent

02/03/2020
Last Updated

Explanation

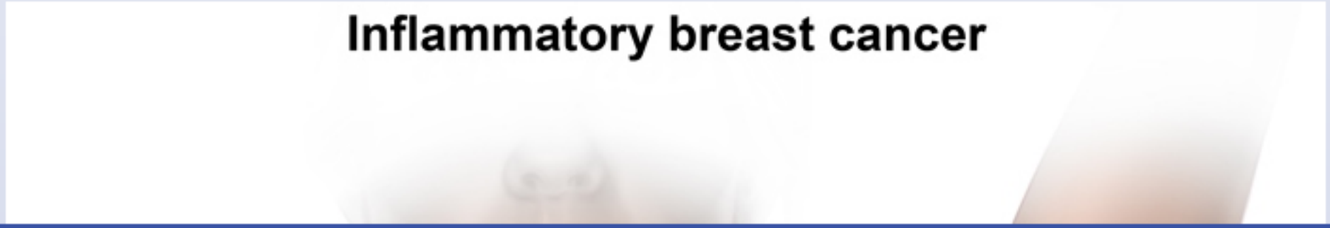

1
2
3
4
5
6
7
8
9
10
11
12
13
14
15
16
17
18
19
20
21
22
23
24
25
26
27
28
29
30
31

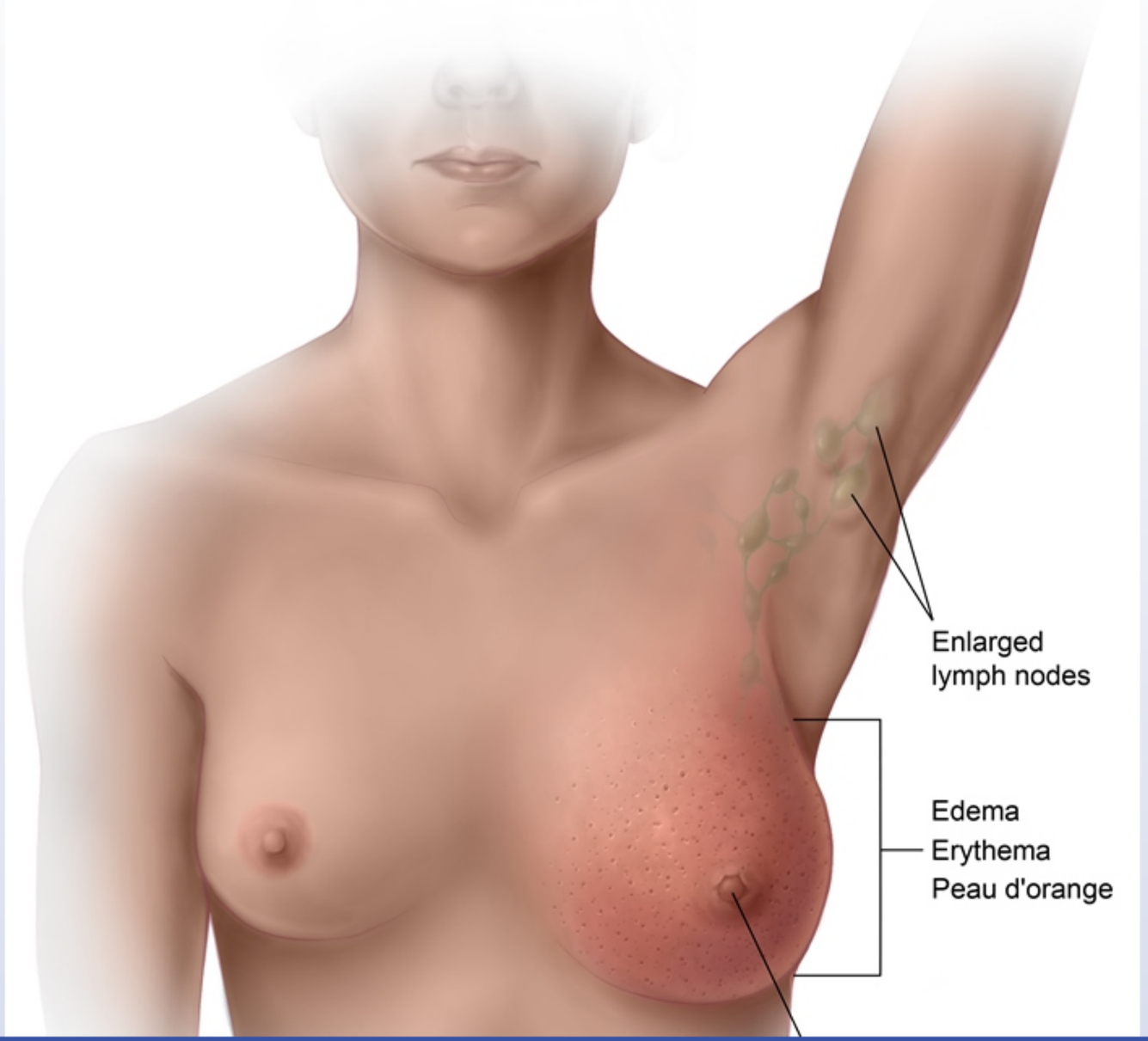

©UWorld

This patient has a classic **peau d'orange** rash, which is characterized by a generalized, **erythematous** rash that may be tender or itchy. The skin texture is **firm** and **coarsely pitted** like an orange peel (after which it is named). This rapidly progressive dermatological finding (with or without an underlying mass) and **breast edema** are consistent with the characteristic presentation of **inflammatory breast cancer**, a poorly differentiated breast malignancy with an unfavorable prognosis.

The term "inflammatory" is a misnomer because the classic skin findings are not due to infection but are instead caused by cancerous cells **obstructing lymphatic drainage** after spreading to the dermal lymphatic spaces. Because of this cancer's propensity to metastasize to the lymphatic system, most patients have lymph node involvement (eg, **axillary lymphadenopathy**) at the time of presentation.

(Choice A) Deep venous thrombosis occurs due to hypercoagulability related to malignancy, surgery, or intravenous catheter placement. Deep venous thrombosis most often affects the lower extremities but can also involve the upper extremities. It presents with edema and pain in the affected limb.

(Choice B) Rupture of a silicone breast implant can lead to a foreign body reaction with local inflammation (eg, edema, induration), and granuloma formation can result in a palpable, tender mass. Although these findings can mimic inflammatory breast cancer, this patient's pitted skin texture (indicating lymphatic obstruction) and hard axillary lymph nodes make malignancy a more likely diagnosis.

(Choice C) Mastitis (ie, breast infection) most commonly occurs in lactating women and presents with pain, breast swelling, and erythema. Most patients also have systemic findings such as fever, malaise, and leukocytosis.

(Choice E) Breast implant surgery requires surgical incisions that can leave scars on the breast skin. A hypertrophic scar is a thick, raised, and pink fibrous tissue line that follows the original incision. Keloid scars occur due to disorganized collagen deposits; they have a thick, rubbery appearance and extend outside the incision borders.

Educational objective:
Peau d'orange is an erythematous, itchy breast rash with skin texture changes that resemble an orange peel. It is the key dermatologic presentation of inflammatory breast cancer and is caused by cancerous cells spreading to the dermal lymphatic spaces and obstructing lymphatic drainage.

References

- Inflammatory breast cancer: an overview

©UWorld

This patient has a classic **peau d'orange** rash, which is characterized by a generalized, **erythematous** rash that may be tender or itchy. The skin texture is **firm** and **coarse** ut
an underlying mass) and ated
breast malignancy with an

The term "inflammatory" is
obstructing lymphatic d
lymphatic system, most pa

(Choice A) Deep venous ep
venous thrombosis most c
affected limb.

(Choice B) Rupture of a
granuloma formation can
skin texture (indicating lym

(Choice C) Mastitis (ie, b ost
patients also have system

(Choice E) Breast implan nd
pink fibrous tissue line tha
appearance and extend o

Educational objective:
Peau d'orange is an eryth
presentation of inflammato atic
drainage.

References

- Inflammatory breast cancer: an overview

Exhibit Display

Breast cancer classification

	Diagnosis	Key features
Noninvasive	DCIS	• Central necrosis • Precancerous lesion • Confined to ducts & lobules
	Paget disease	• Eczematous nipple lesion • Extension of DCIS into ducts
Invasive	Ductal carcinoma	• Most common type • Nests & cords of cells
	Lobular carcinoma	• Small cells in single file • Mammary stroma invasion
	Inflammatory breast cancer	• Peau d'orange • Dermal lymphatic invasion

DCIS = ductal carcinoma in situ.

Add To New Card | Existing Card

©UWorld

Exhibit Display

Zoom In | Zoom Out | Reset | Add To New Card | Existing Card

Inflammatory breast cancer: an overview

©UWorld

Exhibit Display

Zoom In | Zoom Out | Reset | Add To New Card | Existing Card

- Inflammatory breast cancer: an overview

1
2
3
4
5
6
7
8
9
10
11
12
13
14
15
16
17
18
19
20
21
22
23
24
25
26
27
28
29
30
31

1
2
3
4
5
6
7
8
9
10
11
12
13
14
15
16
17
18
19
20
21
22
23
24
25
26
27
28
29
30
31

A 30-year-old woman comes to the emergency department with sudden-onset abdominal pain and ascites. Laboratory studies show anemia, reticulocytosis, leukopenia, and thrombocytopenia. Flow cytometry of the patient's peripheral blood cells using the appropriate monoclonal antibodies shows CD55 and CD59 deficiency. CT scan of the abdomen shows hepatic vein thrombosis. Which of the following is the most likely cause of this patient's anemia?

A. Complement activation

B. Factor V mutation

C. Intracellular dehydration

D. Mutation in beta globin chain

E. Splenic sequestration

Submit

1
2
3
4
5
6
7
8
9
10
11
12
13
14
15
16
17
18
19
20
21
22
23
24
25
26
27
28
29
30
31

A 30-year-old woman comes to the emergency department with sudden-onset abdominal pain and ascites. Laboratory studies show anemia, reticulocytosis, leukopenia, and thrombocytopenia. Flow cytometry of the patient's peripheral blood cells using the appropriate monoclonal antibodies shows CD55 and CD59 deficiency. CT scan of the abdomen shows hepatic vein thrombosis. Which of the following is the most likely cause of this patient's anemia?

- A. Complement activation (64%)
- B. Factor V mutation (10%)
- C. Intracellular dehydration (1%)
- D. Mutation in beta globin chain (4%)
- E. Splenic sequestration (17%)

Omitted
Correct answer
A

64%
Answered correctly

02 secs
Time Spent

01/30/2020
Last Updated

Explanation

1
2
3
4
5
6
7
8
9
10
11
12
13
14
15
16
17
18
19
20
21
22
23
24
25
26
27
28
29
30
31

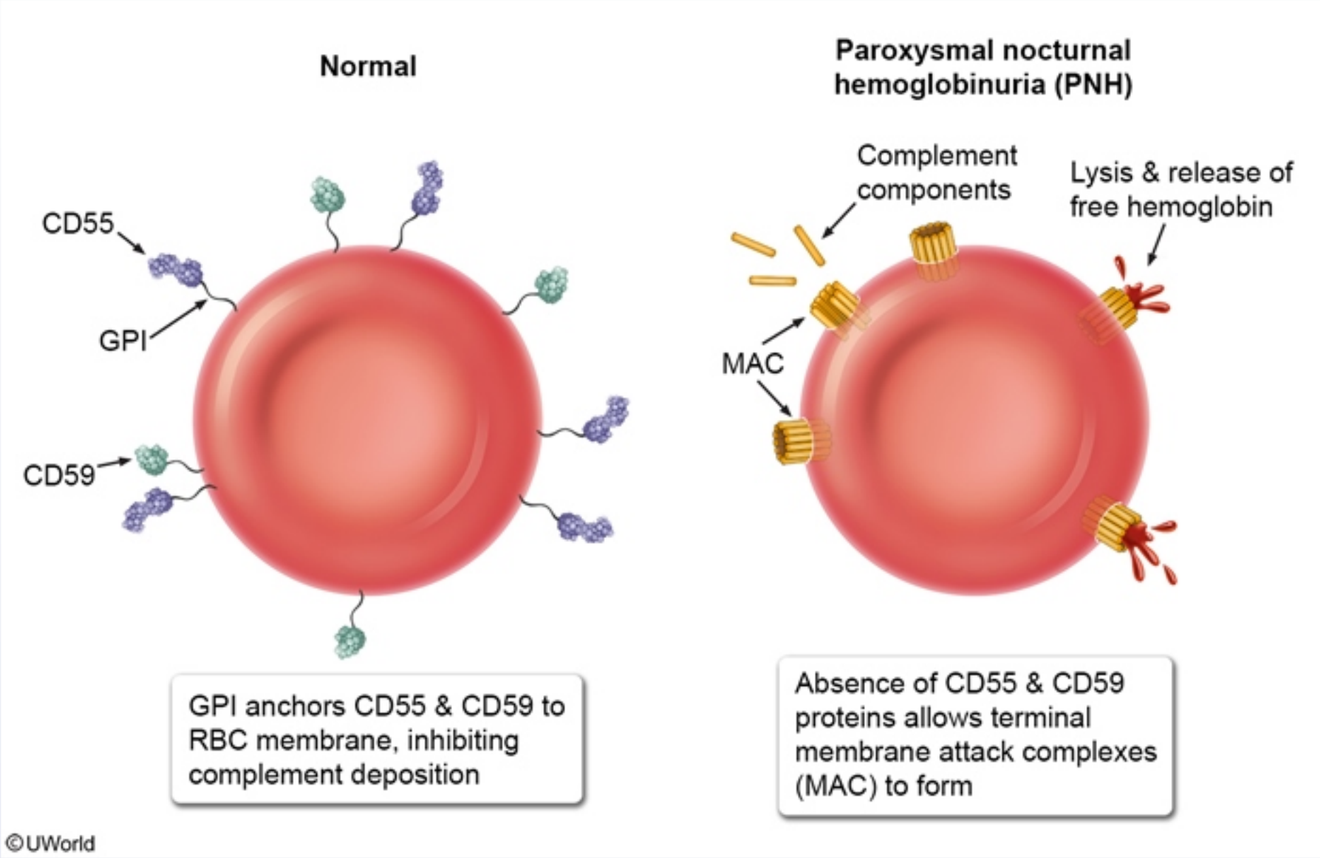

This patient's combination of hemolytic anemia, hypercoagulability (eg, hepatic vein thrombosis), and pancytopenia are characteristic of **paroxysmal nocturnal hemoglobinuria (PNH)**. Despite the name, hemolysis has been shown to occur at low baseline levels throughout the day, with exacerbations caused by a variety of inflammatory triggers (eg, infections, surgery).

PNH is caused by an acquired mutation of the *PIGA* gene within a clonal population of multipotent hematopoietic stem cells. This gene is involved in the synthesis of the **glycosylphosphatidylinositol (GPI) anchor**, a glycolipid necessary for the attachment of several cell-surface proteins, including CD55 (decay-accelerating factor) and CD59 (MAC inhibitory protein). These proteins help inactivate complement and prevent the

This patient's combination of hemolytic anemia, hypercoagulability (eg, hepatic vein thrombosis), and pancytopenia are characteristic of **paroxysmal nocturnal hemoglobinuria (PNH)**. Despite the name, hemolysis has been shown to occur at low baseline levels throughout the day, with exacerbations caused by a variety of inflammatory triggers (eg, infections, surgery).

PNH is caused by an acquired mutation of the *PIGA* gene within a clonal population of multipotent hematopoietic stem cells. This gene is involved in the synthesis of the **glycosylphosphatidylinositol (GPI) anchor**, a glycolipid necessary for the attachment of several cell-surface proteins, including CD55 (decay-accelerating factor) and CD59 (MAC inhibitory protein). These proteins help inactivate complement and prevent the membrane attack complex from forming on normal cells.

Absence of the GPI anchor results in CD55 and CD59 deficiency and **complement-mediated hemolysis**. The hemolysis occurs more often at night because complement activity is increased during sleep due to lower blood pH. Patients also develop **thrombotic complications** (eg, Budd-Chiari syndrome), likely due to release of free hemoglobin and other prothrombotic factors from lysed red blood cells and platelets. PNH is often associated with pancytopenia and **aplastic anemia** (possibly due to autoimmune attack against GPI-antigens on stem cells). Flow cytometry is the gold standard for the diagnosis of PNH and will show absence of the GPI anchor and **CD55 and CD59 deficiency**.

(Choice B) Factor V mutation can result in an aberration called factor V Leiden, which is resistant to cleavage by activated protein C. Patients with factor V Leiden are at increased risk of thrombotic events, but hemolytic anemia and pancytopenia are not seen.

(Choice C) Intracellular dehydration occurs during the pathogenesis of sickle cell anemia and spherocytosis.

(Choice D) Mutations affecting the beta globin chain cause β-thalassemia.

(Choice E) Splenic sequestration is a common complication of sickle cell anemia.

Educational objective:
The triad of hemolytic anemia, hypercoagulability, and pancytopenia suggests paroxysmal nocturnal hemoglobinuria (PNH). PNH results from an acquired mutation in the *PIGA* gene that causes absence of the glycosylphosphatidylinositol anchor and associated deficiency of CD55 and CD59 complement inhibitor proteins.

References

- The phenotype of a germline mutation in PIGA: the gene somatically mutated in paroxysmal nocturnal hemoglobinuria.

1
2
3
4
5
6
7
8
9
10
11
12
13
14
15
16
17
18
19
20
21
22
23
24
25
26
27
28
29
30
31

A 1-year-old African American boy is brought to the emergency department by his parents with a 3-hour history of severe swelling and tenderness of the hands and feet. They do not know what caused the swelling and say that the boy cries when his hands or feet are touched. The patient has no history of recent illness and is up to date on all immunizations. The boy attends day care, but his parents are unsure about any sick contacts. His family history is significant for an older brother who died of pneumococcal sepsis at age 6. Physical examination shows bilateral, severe swelling of the hands and feet. Which of the following is most likely abnormal in this patient?

A. Left ventricular systolic function
B. Serum albumin
C. Serum C4 complement fraction
D. Serum haptoglobin
E. Systemic venous pressure
F. Urine cortisol excretion

Submit

A 1-year-old African American boy is brought to the emergency department by his parents with a 3-hour history of severe swelling and tenderness of the hands and feet. They do not know what caused the swelling and say that the boy cries when his hands or feet are touched. The patient has no history of recent illness and is up to date on all immunizations. The boy attends day care, but his parents are unsure about any sick contacts. His family history is significant for an older brother who died of pneumococcal sepsis at age 6. Physical examination shows bilateral, severe swelling of the hands and feet. Which of the following is most likely abnormal in this patient?

A. Left ventricular systolic function (2%)

B. Serum albumin (9%)

C. Serum C4 complement fraction (26%)

✓ D. Serum haptoglobin (53%)

E. Systemic venous pressure (7%)

F. Urine cortisol excretion (1%)

Omitted
Correct answer
D

53%
Answered correctly

01 sec
Time Spent

01/13/2020
Last Updated

Explanation

Sickle cell disease (SCD) is the most common autosomal recessive disorder in African Americans. Its manifestations include the following:

1. **Hemolysis:** Repeated sickling of red blood cells leads to permanent deformation and premature erythrocyte destruction by macrophages and mechanical stress. This causes **intra- and extravascular hemolysis**, resulting in increased indirect bilirubin and lactate dehydrogenase and **decreased haptoglobin**. Haptoglobin binds circulating hemoglobin and reduces renal excretion of free hemoglobin.

1
2
3
4
5
6
7
8
9
10
11
12
13
14
15
16
17
18
19
20
21
22
23
24
25
26
27
28
29
30
31

Sickle cell disease (SCD) is the most common autosomal recessive disorder in African Americans. Its manifestations include the following:

1. **Hemolysis:** Repeated sickling of red blood cells leads to permanent deformation and premature erythrocyte destruction by macrophages and mechanical stress. This causes **intra- and extravascular hemolysis**, resulting in increased indirect bilirubin and lactate dehydrogenase and **decreased haptoglobin**. Haptoglobin binds circulating hemoglobin and reduces renal excretion of free hemoglobin, preventing tubular injury.

2. **Vasoocclusive symptoms:** Patients with SCD may experience pain from hypoxic tissue injury and infarctions due to obstruction of small vessels by sickled cells. Microvascular occlusion typically involves the bone marrow, periosteum, and deep muscles but can occur in other organs. This patient is presenting with **dactylitis** (hand-foot syndrome), which results from small infarctions in the bones of the extremities. These infarctions cause swelling, tenderness, and warmth. Dactylitis is common in patients with SCD during the first few years of life as the affected bones still contain hematopoietic bone marrow. In older children and adults, vascular occlusion leads to pain crises, acute chest syndrome, leg ulceration, priapism, autosplenectomy, and stroke.

3. **Infections:** Patients with SCD are predisposed to infections with **encapsulated organisms** (eg, *Streptococcus pneumoniae*) because repeated splenic infarcts cause functional asplenia.

(Choices A and E) The chronic anemia in SCD can result in cardiomegaly due to chronically increased cardiac output (systolic function is largely preserved due to an increase in stroke volume). However, this typically does not occur until after infancy. Older patients can develop congestive heart failure due to ischemic cardiomyopathy and present with decreased cardiac output and increased systemic venous pressure.

(Choices B and F) Serum albumin and urine cortisol excretion are typically normal in patients with SCD.

(Choice C) Hereditary angioedema is a rare autosomal dominant disorder that is associated with painless episodes of swelling involving the face, lips, larynx, and extremities. It is caused by C1-inhibitor deficiency, not vasoocclusion.

Educational objective:
Dactylitis (painful swelling of the hands and feet) is a common presentation of sickle cell disease (SCD) in young children. It is one of many vasoocclusive manifestations of SCD. Sickling episodes result in hemolysis, which leads to increased indirect bilirubin and lactate dehydrogenase and decreased levels of haptoglobin.

1
2
3
4
5
6
7
8
9
10
11
12
13
14
15
16
17
18
19
20
21
22
23
24
25
26
27
28
29
30
31

Exhibit Display

Sickle cell anemia in crisis

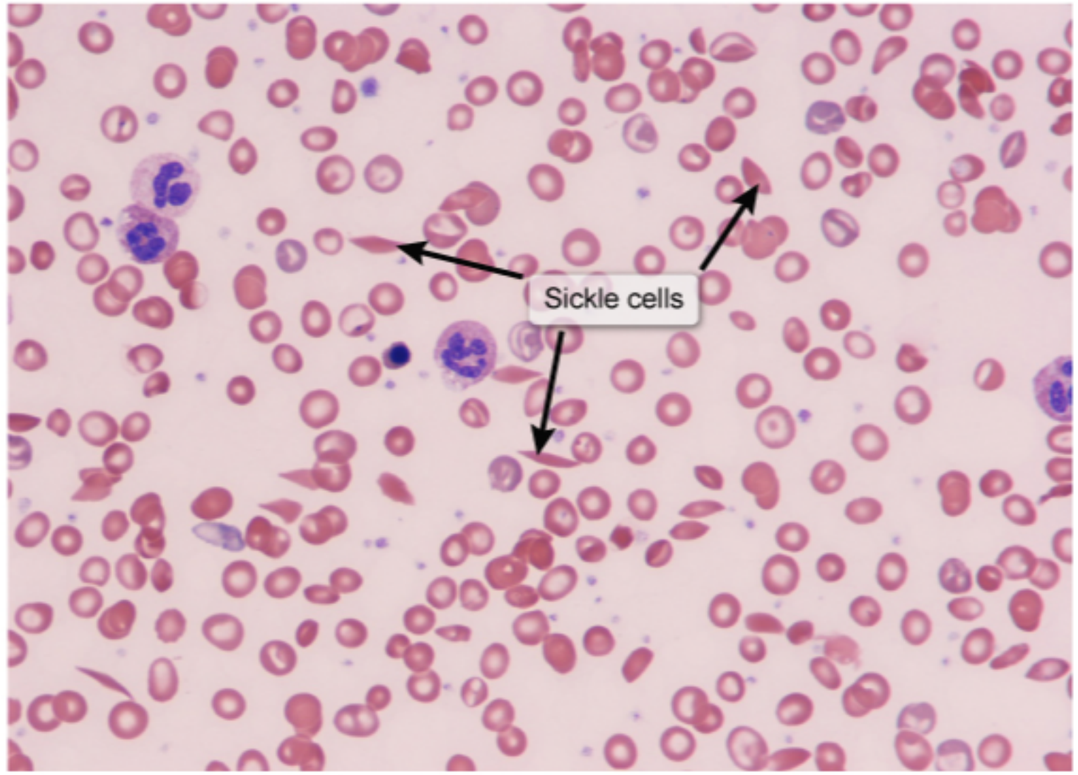

©UWorld

Zoom In | Zoom Out | Reset | Add To New Card | Existing Card

1
2
3
4
5
6
7
8
9
10
11
12
13
14
15
16
17
18
19
20
21
22
23
24
25
26
27
28
29
30
31

organs. This patient is presenting with **dactylitis** (hand-foot syndrome), which results from small infarctions in the bones of the extremities. These infarctions cause swelling, tenderness, and warmth. Dactylitis is common in patients with SCD during the first few years of life as the affected bones still contain hematopoietic bone marrow. In older children and adults, vascular occlusion leads to pain crises, acute chest syndrome, leg ulceration, priapism, autosplenectomy, and stroke.

3. **Infections:** Patients with SCD are predisposed to infections with **encapsulated organisms** (eg, *Streptococcus pneumoniae*) because repeated splenic infarcts cause functional asplenia.

(Choices A and E) The chronic anemia in SCD can result in cardiomegaly due to chronically increased cardiac output (systolic function is largely preserved due to an increase in stroke volume). However, this typically does not occur until after infancy. Older patients can develop congestive heart failure due to ischemic cardiomyopathy and present with decreased cardiac output and increased systemic venous pressure.

(Choices B and F) Serum albumin and urine cortisol excretion are typically normal in patients with SCD.

(Choice C) Hereditary angioedema is a rare autosomal dominant disorder that is associated with painless episodes of swelling involving the face, lips, larynx, and extremities. It is caused by C1-inhibitor deficiency, not vasoocclusion.

Educational objective:
Dactylitis (painful swelling of the hands and feet) is a common presentation of sickle cell disease (SCD) in young children. It is one of many vasoocclusive manifestations of SCD. Sickling episodes result in hemolysis, which leads to increased indirect bilirubin and lactate dehydrogenase and decreased levels of haptoglobin.

References

- Vaso-occlusion in sickle cell disease: pathophysiology and novel targeted therapies
- Lactate dehydrogenase and hemolysis in sickle cell disease

Pathophysiology	Hematology & Oncology	Sickle cell
Subject	System	Topic

Copyright © UWorld. All rights reserved.

1
2
3
4
5
6
7
8
9
10
11
12
13
14
15
16
17
18
19
20
21
22
23
24
25
26
27
28
29
30
31

A 50-year-old woman comes to the physician due to periodic reddening of her skin that is starting to become bothersome. The redness involves mainly her face and neck and is accompanied by mild warmth. The episodes initially lasted only a few minutes, but now they sometimes exceed 20 minutes. The patient has also had persistent watery diarrhea and associated abdominal cramping for the last several months. Physical examination shows several, purple vascular lesions surrounding her nose. Urinary excretion of 5-hydroxyindoleacetic acid (5-HIAA) over 24 hours is increased. Abdominal imaging shows a tumor in the small intestine. Which of the following is most likely responsible for this patient's condition?

A. Localized adenocarcinoma

B. Localized carcinoid

C. Metastatic carcinoid

D. Metastatic lymphoma

E. Secretory leiomyoma

Submit

A 50-year-old woman comes to the physician due to periodic reddening of her skin that is starting to become bothersome. The redness involves mainly her face and neck and is accompanied by mild warmth. The episodes initially lasted only a few minutes, but now they sometimes exceed 20 minutes. The patient has also had persistent watery diarrhea and associated abdominal cramping for the last several months. Physical examination shows several, purple vascular lesions surrounding her nose. Urinary excretion of 5-hydroxyindoleacetic acid (5-HIAA) over 24 hours is increased. Abdominal imaging shows a tumor in the small intestine. Which of the following is most likely responsible for this patient's condition?

A. Localized adenocarcinoma (2%)

B. Localized carcinoid (21%)

✓ C. Metastatic carcinoid (72%)

D. Metastatic lymphoma (2%)

E. Secretory leiomyoma (1%)

Omitted
Correct answer
C

72%
Answered correctly

02 secs
Time Spent

03/08/2020
Last Updated

Explanation

Carcinoid tumors most frequently arise from the enterochromaffin (endocrine) cells of the intestinal mucosa. These cells produce a number of vasoactive substances, such as serotonin (5-HT), bradykinin, and prostaglandins. When the tumor is confined to the intestine, these secretory products are metabolized by the liver and patients do not develop carcinoid syndrome. In contrast, if intestinal carcinoid **metastasizes to the liver**, these vasoactive substances bypass the liver and enter the systemic circulation, resulting in **carcinoid syndrome**. Extraintestinal carcinoid tumors (eg, bronchial carcinoid) can cause carcinoid syndrome without metastasizing as the vasoactive substances are secreted directly into

Features of carcinoid syndrome	
Clinical manifestations	• Skin: **Flushing**, telangiectasias, cyanosis • Gastrointestinal: **Watery diarrhea**, cramping • Pulmonary: **Bronchospasm**, dyspnea, wheezing • Cardiac: Valvular fibrous plaques (right > left)
Diagnosis	• Elevated 24-hour urinary excretion of **5-HIAA** • CT/MRI of abdomen & pelvis to localize tumor
Treatment	• Octreotide for symptomatic patients • Surgery for liver metastases

5-HIAA = 5-hydroxyindoleacetic acid.

©UWorld

Carcinoid tumors most frequently arise from the enterochromaffin (endocrine) cells of the intestinal mucosa. These cells produce a number of vasoactive substances, such as serotonin (5-HT), bradykinin, and prostaglandins. When the tumor is confined to the intestine, these secretory products are metabolized by the liver and patients do not develop carcinoid syndrome. In contrast, if intestinal carcinoid **metastasizes to the liver**, these vasoactive substances bypass the liver and enter the systemic circulation, resulting in **carcinoid syndrome**. Extraintestinal carcinoid tumors (eg, bronchial carcinoid) can cause carcinoid syndrome without metastasizing as the vasoactive substances are secreted directly into systemic circulation (again bypassing hepatic metabolism).

Increased level of the serotonin metabolite **5-hydroxyindoleacetic acid (5-HIAA)** in a 24-hour urine sample is the most useful initial test for confirming carcinoid syndrome.

(Choices A, D, and E) Adenocarcinoma, lymphoma, and secretory leiomyoma would not result in carcinoid syndrome or elevated urinary 5-HIAA levels.

(Choice B) The vasoactive substances secreted by a localized intestinal carcinoid tumor are metabolized by the liver via first-pass metabolism.

	• Surgery for liver metastases

5-HIAA = 5-hydroxyindoleacetic acid.

©UWorld

Carcinoid tumors most frequently arise from the enterochromaffin (endocrine) cells of the intestinal mucosa. These cells produce a number of vasoactive substances, such as serotonin (5-HT), bradykinin, and prostaglandins. When the tumor is confined to the intestine, these secretory products are metabolized by the liver and patients do not develop carcinoid syndrome. In contrast, if intestinal carcinoid **metastasizes to the liver**, these vasoactive substances bypass the liver and enter the systemic circulation, resulting in **carcinoid syndrome**. Extraintestinal carcinoid tumors (eg, bronchial carcinoid) can cause carcinoid syndrome without metastasizing as the vasoactive substances are secreted directly into systemic circulation (again bypassing hepatic metabolism).

Increased level of the serotonin metabolite **5-hydroxyindoleacetic acid (5-HIAA)** in a 24-hour urine sample is the most useful initial test for confirming carcinoid syndrome.

(Choices A, D, and E) Adenocarcinoma, lymphoma, and secretory leiomyoma would not result in carcinoid syndrome or elevated urinary 5-HIAA levels.

(Choice B) The vasoactive substances secreted by a localized intestinal carcinoid tumor are metabolized by the liver via first-pass metabolism, preventing the development of carcinoid syndrome. Extraintestinal metastasis of intestinal carcinoid tumors is required to produce carcinoid symptoms.

Educational objective:
Carcinoid tumors confined to the intestine do not cause carcinoid syndrome as their secretory products are metabolized by the liver before entering the systemic circulation. In contrast, intestinal carcinoids that metastasize to the liver and extraintestinal (eg, bronchial) carcinoids release vasoactive substances that avoid first-pass metabolism, resulting in carcinoid syndrome (eg, flushing, diarrhea, bronchospasm).

Pathophysiology	Hematology & Oncology	Carcinoid tumors
Subject	System	Topic

Copyright © UWorld. All rights reserved.

1
2
3
4
5
6
7
8
9
10
11
12
13
14
15
16
17
18
19
20
21
22
23
24
25
26
27
28
29
30
31

A 19-year-old woman comes to the office due to exertional dyspnea and intermittent lightheadedness. On examination, mucosal pallor is present. Laboratory studies reveal a red blood cell count of 3.5 million/hpf and a hemoglobin concentration of 8.5 g/dL. Peripheral smear is shown in the image below:

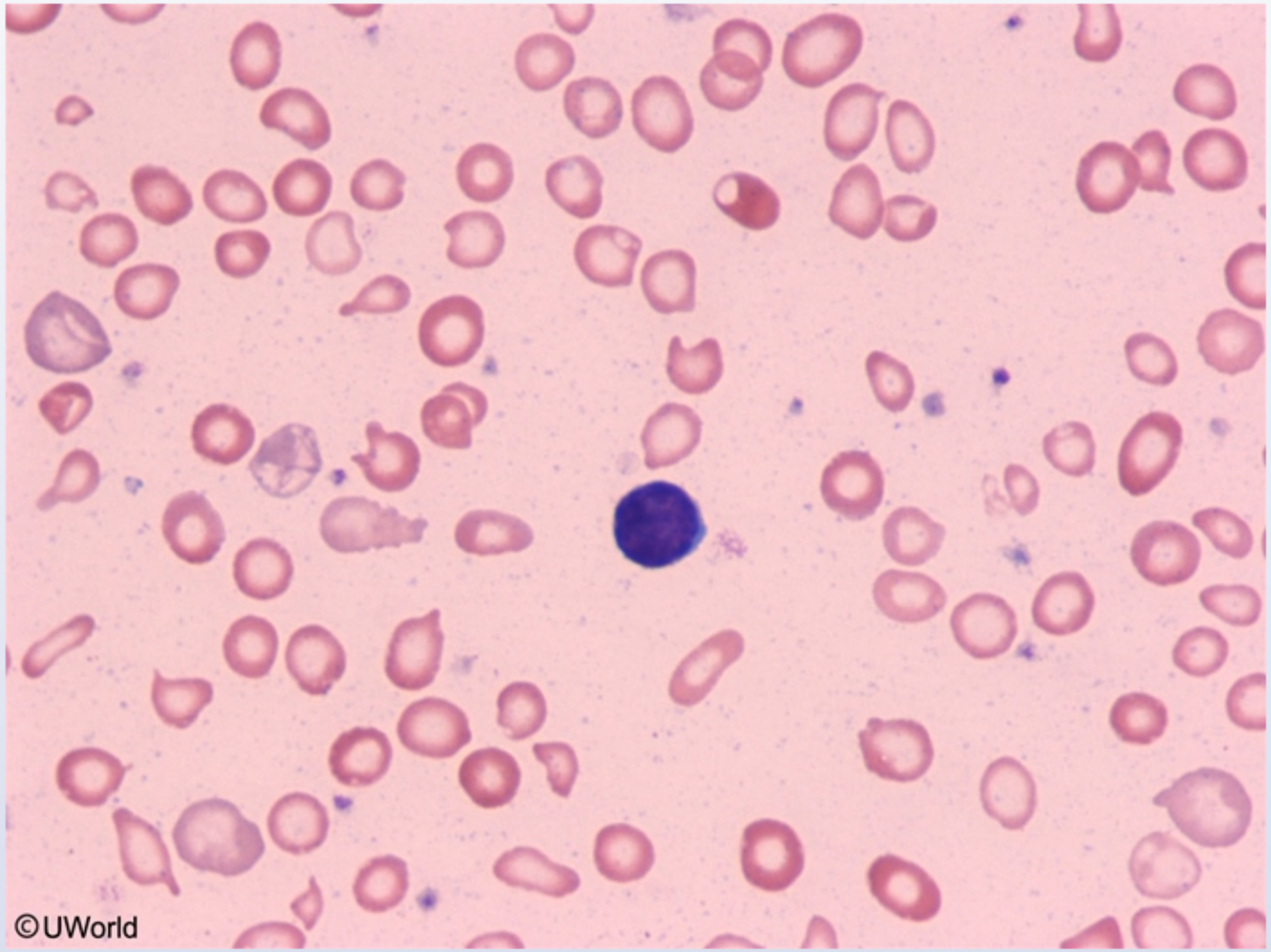

1
2
3
4
5
6
7
8
9
10
11
12
13
14
15
16
17
18
19
20
21
22
23
24
25
26
27
28
29
30
31

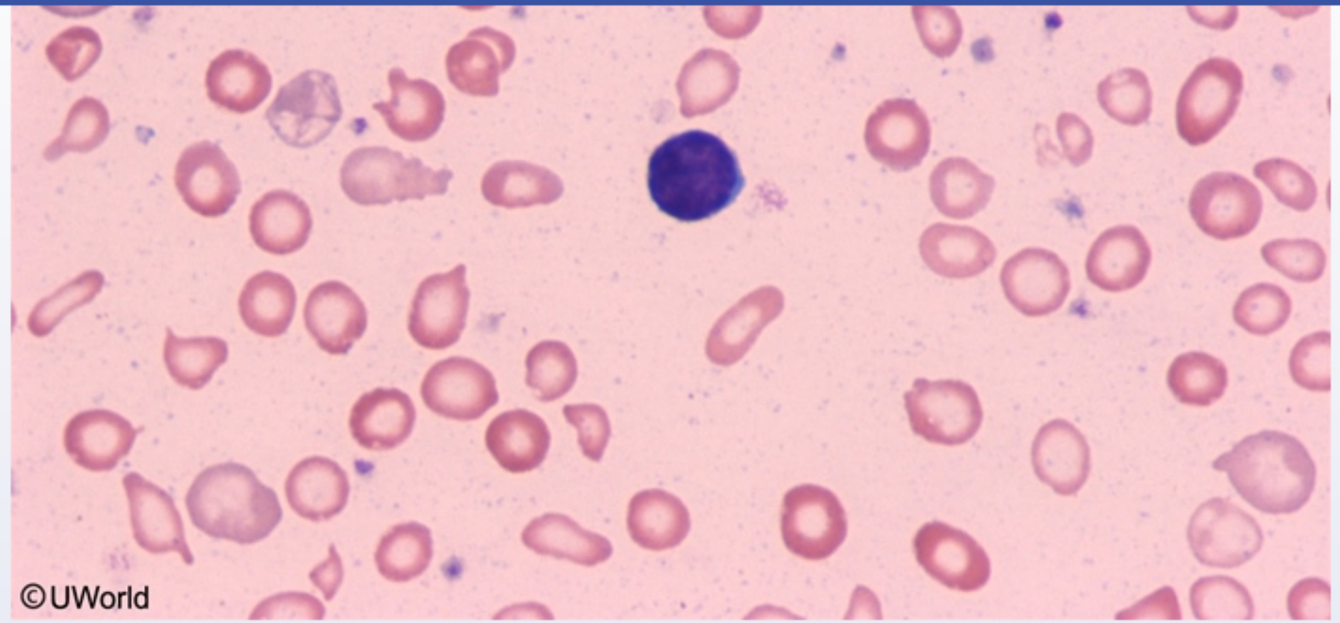

Which of the following findings are most likely present in this patient?

- A. Decreased transferrin binding capacity
- B. Increased macrophage iron retention
- C. Increased serum cytokine levels
- D. Increased serum erythropoietin levels
- E. Increased serum hepcidin levels

Submit

1
2
3
4
5
6
7
8
9
10
11
12
13
14
15
16
17
18
19
20
21
22
23
24
25
26
27
28
29
30
31

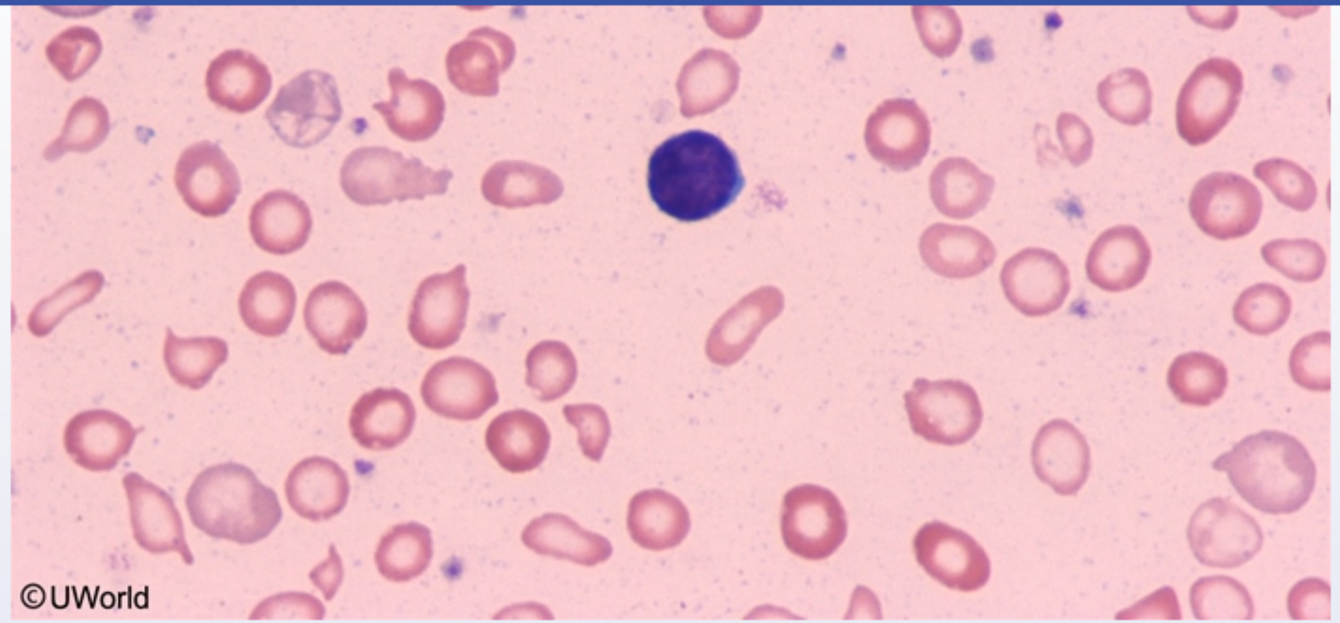

Which of the following findings are most likely present in this patient?

A. Decreased transferrin binding capacity (12%)

B. Increased macrophage iron retention (8%)

C. Increased serum cytokine levels (5%)

✓ D. Increased serum erythropoietin levels (59%)

E. Increased serum hepcidin levels (12%)

Omitted
Correct answer

59%
Answered correctly

08 secs
Time Spent

06/26/2020
Last Updated

	Iron deficiency anemia	Anemia of chronic disease
Serum ferritin	↓	Normal or ↑
Serum iron	↓	↓
Mean corpuscular volume	↓	Normal or ↓
Transferrin (total iron-binding capacity)	↑	Normal or ↓
Transferrin saturation	↓	↓
Erythropoietin	↑	Normal or ↑
Hepcidin	↓	↑
C-reactive protein	Normal	↑
Serum cytokines	Normal	↑

This patient's dyspnea, lightheadedness, and mucosal pallor are likely due to **symptomatic anemia**. A number of underlying processes can cause anemia, but the differential diagnosis can usually be narrowed by concurrent clinical data. In this case, the peripheral blood smear demonstrates hypochromic, microcytic erythrocytes and a variety of erythrocyte shapes **(poikilocytosis)**, raising strong suspicion for severe **iron deficiency anemia** (IDA). Young women often develop IDA from heavy menstruation.

Patients with severe IDA do not have enough iron to generate adequate hemoglobin for each erythrocyte, which results in low mean corpuscular hemoglobin concentration (hypochromia) and small erythrocyte size (microcytosis). Interstitial fibroblasts in the peritubular capillaries and proximal convoluted tubule of the kidney detect the reduced oxygen carrying capacity of the blood (mild tissue hypoxia) and **increase**

Serum cytokines	Normal	↑

This patient's dyspnea, lightheadedness, and mucosal pallor are likely due to **symptomatic anemia**. A number of underlying processes can cause anemia, but the differential diagnosis can usually be narrowed by concurrent clinical data. In this case, the peripheral blood smear demonstrates hypochromic, microcytic erythrocytes and a variety of erythrocyte shapes **(poikilocytosis)**, raising strong suspicion for severe **iron deficiency anemia** (IDA). Young women often develop IDA from heavy menstruation.

Patients with severe IDA do not have enough iron to generate adequate hemoglobin for each erythrocyte, which results in low mean corpuscular hemoglobin concentration (hypochromia) and small erythrocyte size (microcytosis). Interstitial fibroblasts in the peritubular capillaries and proximal convoluted tubule of the kidney detect the reduced oxygen carrying capacity of the blood (mild tissue hypoxia) and **increase erythropoietin release** to drive the generation of new erythrocytes. However, new erythrocytes cannot be produced at a level to compensate for the anemia due to insufficient serum iron; therefore, patients typically have **minimal reticulocytes** and **low red blood cell counts** in the peripheral blood.

(Choice A) Transferrin is a serum protein that binds free iron. The concentration of transferrin is increased in IDA (to maximize free iron scavenge), but the amount of iron bound to it is reduced, leading to a low transferrin saturation on laboratory evaluation.

(Choices B, C, E) Hepcidin is a small peptide released by the liver in response to inflammation. It binds to and inhibits iron channels on the surface of enterocytes and on reticuloendothelial macrophages, which reduces iron absorption in the gut and reduces iron release from the reticuloendothelial system (the primary site of iron recycling). Because IDA is not mediated by inflammation, hepcidin levels are typically low; this increases gastrointestinal iron absorption and iron release from the reticuloendothelial system (eg, splenic macrophages). In contrast, anemia of chronic disease is associated with very high levels of hepcidin (and other inflammatory cytokines), which reduces iron availability for erythrocytosis despite adequate total body stores of iron; patients with anemia of chronic disease typically have normocytic anemia and normochromia (not hypochromia).

Educational objective:
Patients with severe iron deficiency anemia typically have evidence of hypochromic, microcytic erythrocytes on peripheral blood smear with poikilocytosis. Laboratory studies will reveal low red blood cell count, low hepcidin, and high transferrin. Although erythropoietin is markedly elevated in iron deficiency anemia, there is not enough iron to efficiently generate erythrocytes; therefore, reticulocyte count is low.

demonstrates hypochromic, microcytic erythrocytes and a variety of erythrocyte shapes **(poikilocytosis)**, raising strong suspicion for severe **iron deficiency anemia** (IDA). Young women often develop IDA from heavy menstruation.

Patients with severe IDA do not have enough iron to generate adequate hemoglobin for each erythrocyte, which results in low mean corpuscular hemoglobin concentration (hypochromia) and small erythrocyte size (microcytosis). Interstitial fibroblasts in the peritubular capillaries and proximal convoluted tubule of the kidney detect the reduced oxygen carrying capacity of the blood (mild tissue hypoxia) and **increase erythropoietin release** to drive the generation of new erythrocytes. However, new erythrocytes cannot be produced at a level to compensate for the anemia due to insufficient serum iron; therefore, patients typically have **minimal reticulocytes** and **low red blood cell counts** in the peripheral blood.

(Choice A) Transferrin is a serum protein that binds free iron. The concentration of transferrin is increased in IDA (to maximize free iron scavenge), but the amount of iron bound to it is reduced, leading to a low transferrin saturation on laboratory evaluation.

(Choices B, C, E) Hepcidin is a small peptide released by the liver in response to inflammation. It binds to and inhibits iron channels on the surface of enterocytes and on reticuloendothelial macrophages, which reduces iron absorption in the gut and reduces iron release from the reticuloendothelial system (the primary site of iron recycling). Because IDA is not mediated by inflammation, hepcidin levels are typically low; this increases gastrointestinal iron absorption and iron release from the reticuloendothelial system (eg, splenic macrophages). In contrast, anemia of chronic disease is associated with very high levels of hepcidin (and other inflammatory cytokines), which reduces iron availability for erythrocytosis despite adequate total body stores of iron; patients with anemia of chronic disease typically have normocytic anemia and normochromia (not hypochromia).

Educational objective:
Patients with severe iron deficiency anemia typically have evidence of hypochromic, microcytic erythrocytes on peripheral blood smear with poikilocytosis. Laboratory studies will reveal low red blood cell count, low hepcidin, and high transferrin. Although erythropoietin is markedly elevated in iron deficiency anemia, there is not enough iron to efficiently generate erythrocytes; therefore, reticulocyte count is low.

Pathophysiology	Hematology & Oncology	Iron deficiency anemia
Subject	System	Topic

Copyright © UWorld. All rights reserved.

Transferrin

Exhibit Display

Microcytic anemia

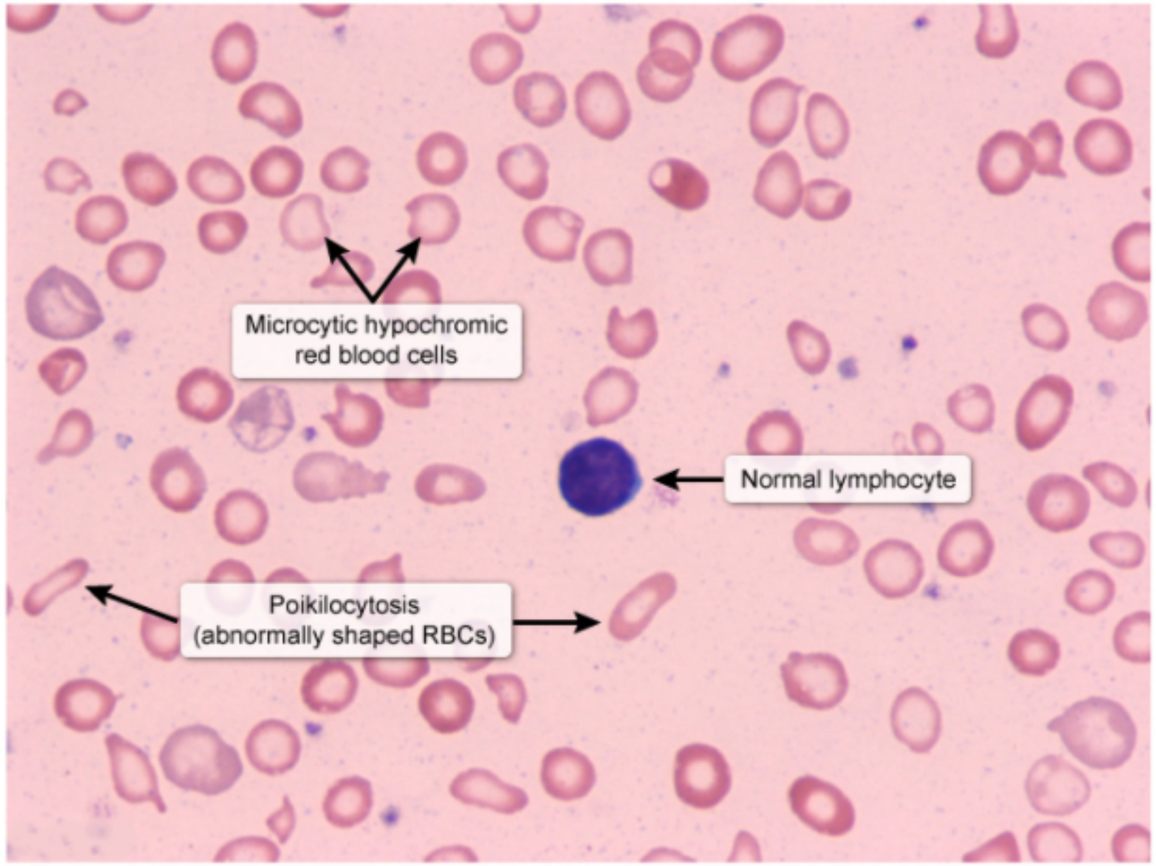

©UWorld

Zoom In Zoom Out Reset Add To Flash Card

reticuloendothelial system (the primary site of iron recycling). Because IDA is not mediated by inflammation, hepcidin levels are typically low; this

A 20-year-old man comes to the emergency department due to a 2-day history of increasing tiredness and exertional dyspnea. He also reports yellowish discoloration of the eyes and dark urine. The patient has no chronic medical conditions, but 5 days ago, he went to an urgent care clinic due to right leg cellulitis; a 7-day course of trimethoprim-sulfamethoxazole was prescribed. The cellulitis has improved. The patient, an exchange student from Israel, does not use tobacco, alcohol, or illicit drugs. Temperature is 37 C (98.6 F), blood pressure is 116/76 mm Hg, and pulse is 104/min. Physical examination shows mild scleral icterus, pale oral mucous membranes, a faint systolic ejection murmur, and a nontender abdomen with no organomegaly. Hemoglobin is 7.4 g/dL and mean corpuscular volume is 90 μm^3. Which of the following additional findings are most likely present in this patient?

	Reticulocyte count	Lactate dehydrogenase	Haptoglobin
A.	Decreased	Decreased	Normal
B.	Decreased	Normal	Normal
C.	Increased	Increased	Decreased
D.	Increased	Normal	Normal
E.	Normal	Increased	Decreased

Submit

A 20-year-old man comes to the emergency department due to a 2-day history of increasing tiredness and exertional dyspnea. He also reports yellowish discoloration of the eyes and dark urine. The patient has no chronic medical conditions, but 5 days ago, he went to an urgent care clinic due to right leg cellulitis; a 7-day course of trimethoprim-sulfamethoxazole was prescribed. The cellulitis has improved. The patient, an exchange student from Israel, does not use tobacco, alcohol, or illicit drugs. Temperature is 37 C (98.6 F), blood pressure is 116/76 mm Hg, and pulse is 104/min. Physical examination shows mild scleral icterus, pale oral mucous membranes, a faint systolic ejection murmur, and a nontender abdomen with no organomegaly. Hemoglobin is 7.4 g/dL and mean corpuscular volume is 90 μm^3. Which of the following additional findings are most likely present in this patient?

	Reticulocyte count	Lactate dehydrogenase	Haptoglobin
A. (0%)	Decreased	Decreased	Normal
B. (2%)	Decreased	Normal	Normal
✓ C. (86%)	Increased	Increased	Decreased
D. (5%)	Increased	Normal	Normal
E. (5%)	Normal	Increased	Decreased

Omitted
Correct answer
C

86%
Answered correctly

03 secs
Time Spent

05/19/2020
Last Updated

Glucose-6-phosphate dehydrogenase deficiency	
Epidemiology	• Hemolytic anemia due to oxidative stress (infection, sulfa drugs, fava beans) • X-linked: Asian, African, or Middle Eastern descent
Manifestations	• Pallor & fatigue • Dark urine, jaundice & icterus • Abdominal/back pain
Laboratory findings	• Hemolysis: ↓ hemoglobin, ↓ haptoglobin, ↑ bilirubin & LDH, ↑ reticulocytes • Peripheral smear: bite cells & Heinz bodies • Negative Coombs test • ↓ G6PD activity level (may be normal during attack)
Management	• Remove or treat responsible agent/condition • Provide supportive care
G6PD = glucose-6-phosphate dehydrogenase; **LDH** = lactate dehydrogenase.	

This patient has anemia and signs of hemolysis (eg, dark urine, scleral icterus) after taking a **sulfa drug** (ie, trimethoprim-sulfamethoxazole), findings consistent with **glucose-6-phosphate dehydrogenase (G6PD) deficiency**. G6PD is a red blood cell (RBC) enzyme that helps neutralize reactive oxygen species by producing NADPH. In the absence of G6PD, oxygen radicals accumulate during times of **oxidative stress** (eg, infection, sulfa drugs, fava bean ingestion), causing damage to RBCs and intravascular hemolysis.

Characteristic findings of **hemolysis** include the following:

- **Normocytic anemia**, which can cause dyspnea, pallor, fatigue, or flow murmur (systolic ejection murmur due to hyperdynamic circulation)
- **Increased** production of **reticulocytes** (immature RBCs) by the bone marrow in response to the drop in hemoglobin
- **Increased** breakdown products of RBCs, including **lactate dehydrogenase** (LDH) and hemoglobin (Increased urinary excretion of hemoglobin occurs with intravascular hemolysis and causes dark urine.)

1
2
3
4
5
6
7
8
9
10
11
12
13
14
15
16
17
18
19
20
21
22
23
24
25
26
27
28
29
30
31

This patient has anemia and signs of hemolysis (eg, dark urine, scleral icterus) after taking a **sulfa drug** (ie, trimethoprim-sulfamethoxazole), findings consistent with **glucose-6-phosphate dehydrogenase (G6PD) deficiency**. G6PD is a red blood cell (RBC) enzyme that helps neutralize reactive oxygen species by producing NADPH. In the absence of G6PD, oxygen radicals accumulate during times of **oxidative stress** (eg, infection, sulfa drugs, fava bean ingestion), causing damage to RBCs and intravascular hemolysis.

Characteristic findings of **hemolysis** include the following:

- **Normocytic anemia**, which can cause dyspnea, pallor, fatigue, or flow murmur (systolic ejection murmur due to hyperdynamic circulation)
- **Increased** production of **reticulocytes** (immature RBCs) by the bone marrow in response to the drop in hemoglobin
- **Increased** breakdown products of RBCs, including **lactate dehydrogenase** (LDH) and hemoglobin (Increased urinary excretion of hemoglobin occurs with intravascular hemolysis and causes dark urine.)
- **Decreased haptoglobin** because it binds free circulating hemoglobin
- Degradation of hemoglobin (heme → biliverdin → bilirubin), resulting in **elevated indirect bilirubin**, which manifests as jaundice and scleral icterus

G6PD deficiency can be differentiated from other hemolytic anemias by the presence of Heinz bodies (inclusions of denatured hemoglobin) and bite cells (caused by phagocytic removal of Heinz bodies) on peripheral smear. Low G6PD activity within RBCs is diagnostic; however, this test may be inaccurate during an acute episode due to increased reticulocytes. Management generally involves avoiding known hemolytic triggers.

Educational objective:
Glucose-6-phosphate dehydrogenase deficiency presents with signs of anemia (eg, fatigue, pallor) and hemolysis (eg, jaundice, dark urine) after oxidative stress (eg, sulfa drug). Hemolysis is associated with reticulocytosis, increased lactate dehydrogenase, decreased haptoglobin, and elevated indirect bilirubin.

References

- Glucose-6-phosphate dehydrogenase deficiency.

Pathophysiology Hematology & Oncology G6PD deficiency

1
2
3
4
5
6
7
8
9
10
11
12
13
14
15
16
17
18
19
20
21
22
23
24
25
26
27
28
29
30
31

Exhibit Display

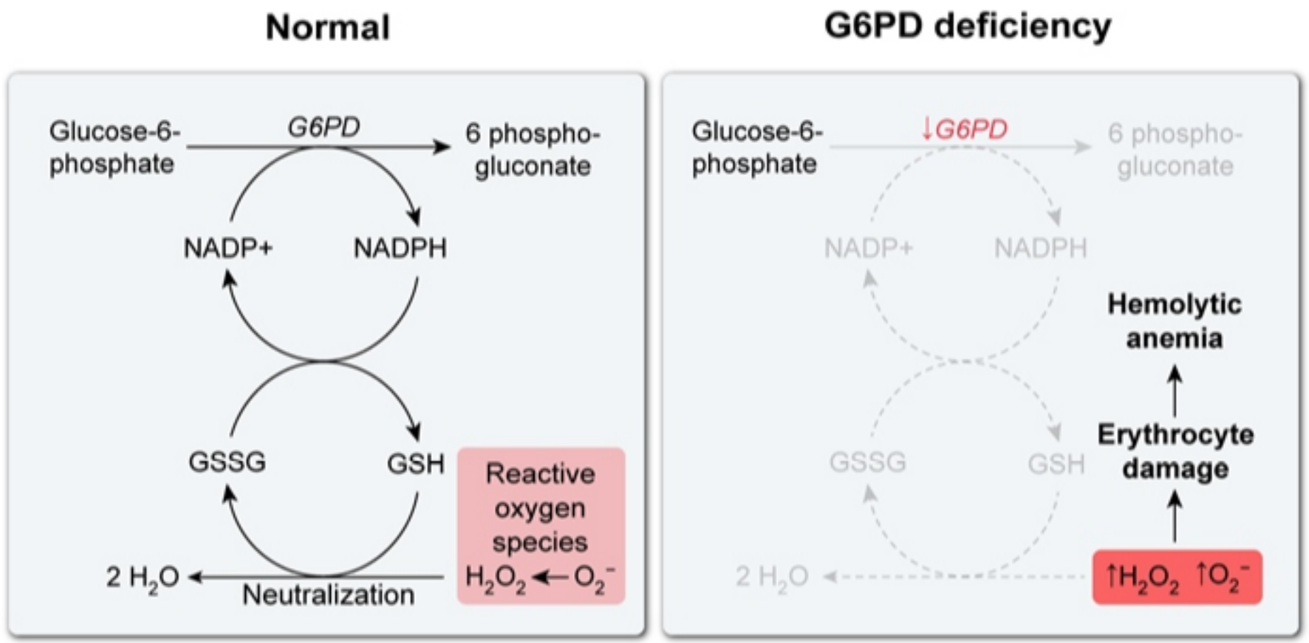

G6PD = glucose-6-phosphate dehydrogenase; **GSH** = glutathione; **GSSG** = glutathione disulfide.

©UWorld

Zoom In Zoom Out Reset Add To Flash Card

Pathophysiology Hematology & Oncology G6PD deficiency

1
2
3
4
5
6
7
8
9
10
11
12
13
14
15
16
17
18
19
20
21
22
23
24
25
26
27
28
29
30
31

Exhibit Display

G6PD deficiency anemia

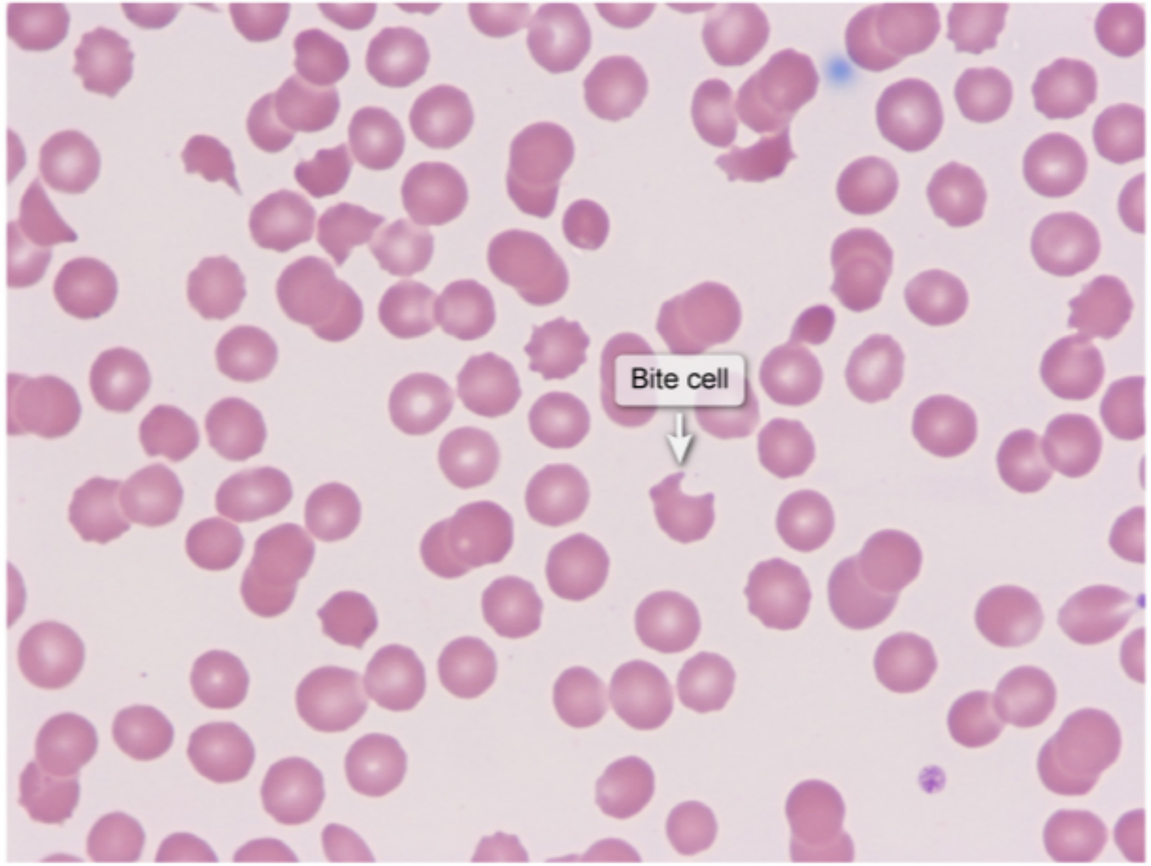

Zoom In
Zoom Out
Reset
Add To Flash Card

Pathophysiology
Hematology & Oncology
G6PD deficiency

findings consistent with **glucose-6-phosphate dehydrogenase (G6PD) deficiency**. G6PD is a red blood cell (RBC) enzyme that helps neutralize reactive oxygen species by producing NADPH. In the absence of G6PD, oxygen radicals accumulate during times of **oxidative stress** (eg, infection, sulfa drugs, fava bean ingestion), causing damage to RBCs and intravascular hemolysis.

Characteristic findings of **hemolysis** include the following:

- **Normocytic anemia**, which can cause dyspnea, pallor, fatigue, or flow murmur (systolic ejection murmur due to hyperdynamic circulation)
- **Increased** production of **reticulocytes** (immature RBCs) by the bone marrow in response to the drop in hemoglobin
- **Increased** breakdown products of RBCs, including **lactate dehydrogenase** (LDH) and hemoglobin (Increased urinary excretion of hemoglobin occurs with intravascular hemolysis and causes dark urine.)
- **Decreased haptoglobin** because it binds free circulating hemoglobin
- Degradation of hemoglobin (heme → biliverdin → bilirubin), resulting in **elevated indirect bilirubin**, which manifests as jaundice and scleral icterus

G6PD deficiency can be differentiated from other hemolytic anemias by the presence of Heinz bodies (inclusions of denatured hemoglobin) and bite cells (caused by phagocytic removal of Heinz bodies) on peripheral smear. Low G6PD activity within RBCs is diagnostic; however, this test may be inaccurate during an acute episode due to increased reticulocytes. Management generally involves avoiding known hemolytic triggers.

Educational objective:
Glucose-6-phosphate dehydrogenase deficiency presents with signs of anemia (eg, fatigue, pallor) and hemolysis (eg, jaundice, dark urine) after oxidative stress (eg, sulfa drug). Hemolysis is associated with reticulocytosis, increased lactate dehydrogenase, decreased haptoglobin, and elevated indirect bilirubin.

References

- Glucose-6-phosphate dehydrogenase deficiency.

Pathophysiology	Hematology & Oncology	G6PD deficiency
Subject	System	Topic

A 64-year-old man comes to the office due to a lump in his neck. He has a long history of using chewing tobacco. On examination, there is an ulcerative lesion in the left floor of mouth. There is also a firm, palpable, nontender left submandibular mass. Biopsy of the submandibular mass is shown in the image below. Which of the following is the most likely route of spread from the floor of mouth to the submandibular mass?

A. Direct invasion through the floor of mouth

B. Field cancerization of the oral cavity mucosa

C. Lymphatic drainage to the submandibular lymph nodes

D. Perineural spread through the lingual nerve

E. Sublingual vein to the submandibular gland

Submit

1
2
3
4
5
6
7
8
9
10
11
12
13
14
15
16
17
18
19
20
21
22
23
24
25
26
27
28
29
30
31

A 64-year-old man comes to the office due to a lump in his neck. He has a long history of using chewing tobacco. On examination, there is an ulcerative lesion in the left floor of mouth. There is also a firm, palpable, nontender left submandibular mass. Biopsy of the submandibular mass is shown in the image below. Which of the following is the most likely route of spread from the floor of mouth to the submandibular mass?

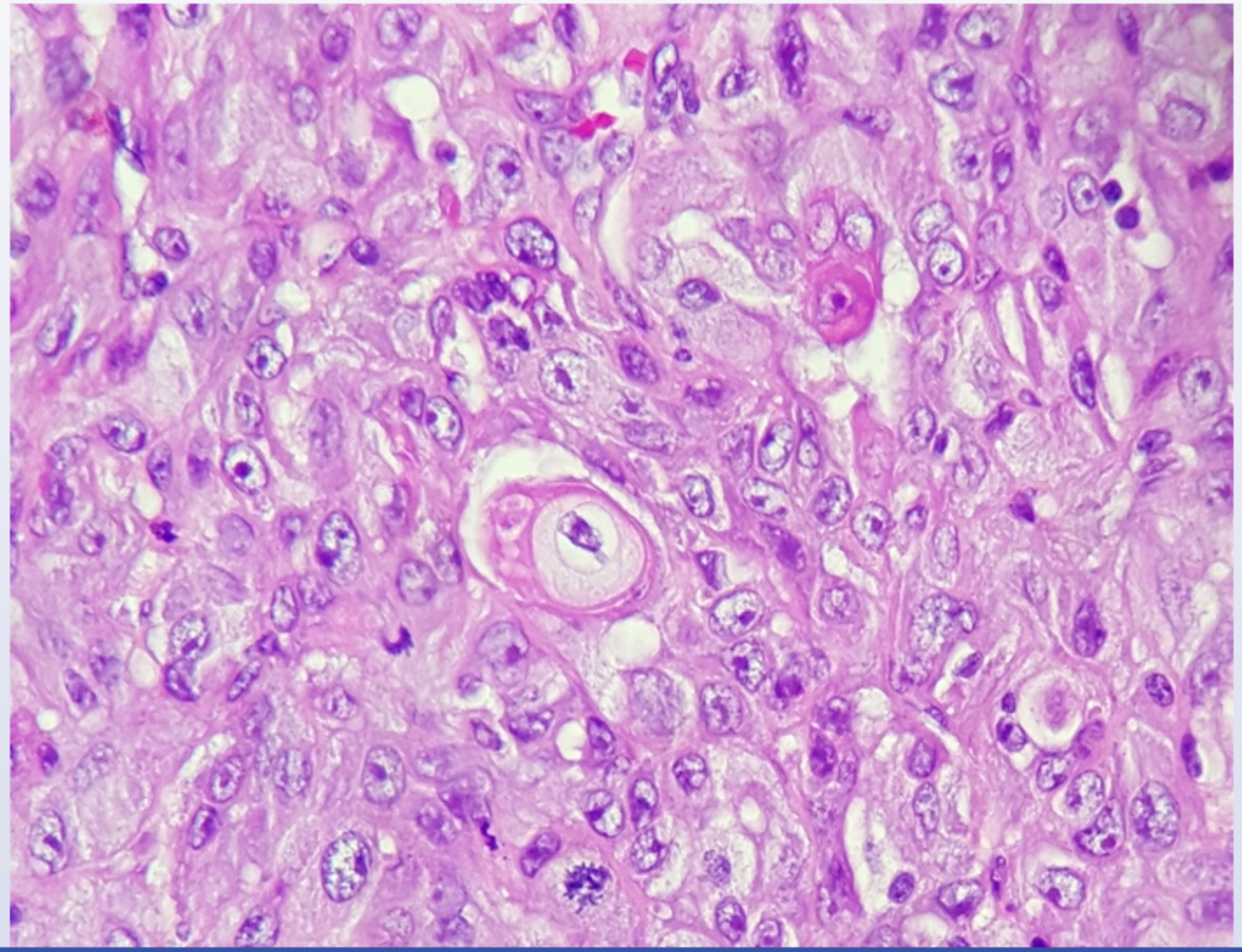

1
2
3
4
5
6
7
8
9
10
11
12
13
14
15
16
17
18
19
20
21
22
23
24
25
26
27
28
29
30
31

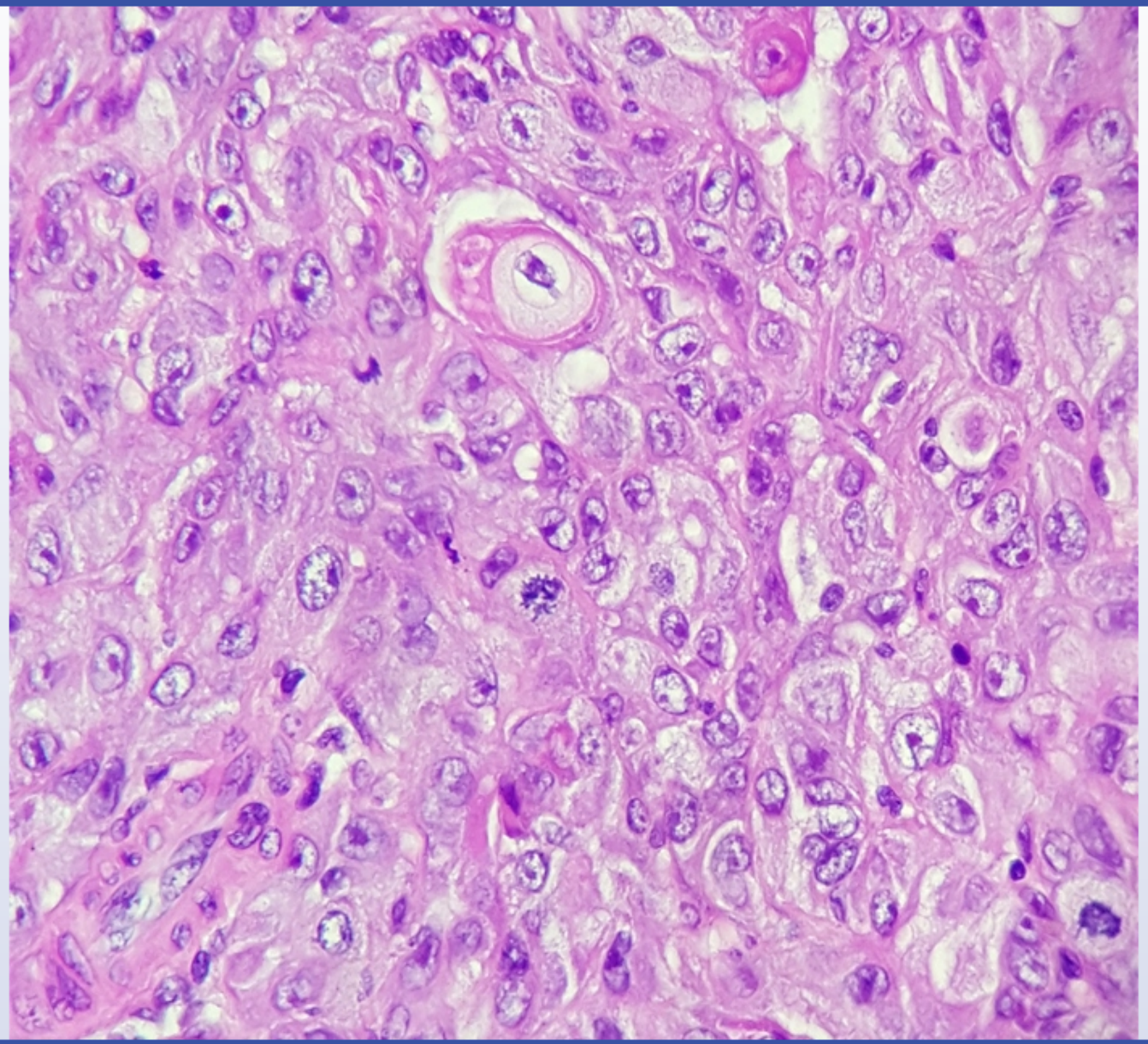

1
2
3
4
5
6
7
8
9
10
11
12
13
14
15
16
17
18
19
20
21
22
23
24
25
26
27
28
29
30
31

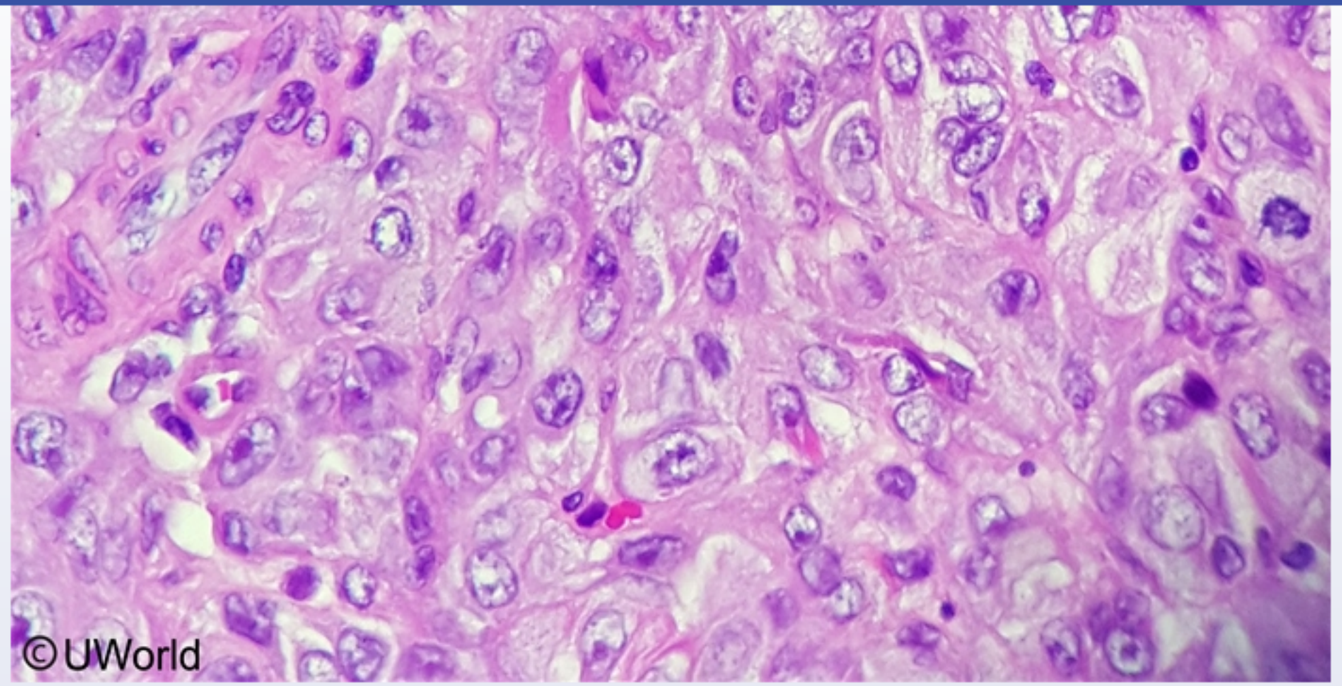

A. Direct invasion through the floor of mouth

B. Field cancerization of the oral cavity mucosa

C. Lymphatic drainage to the submandibular lymph nodes

D. Perineural spread through the lingual nerve

E. Sublingual vein to the submandibular gland

Submit

1
2
3
4
5
6
7
8
9
10
11
12
13
14
15
16
17
18
19
20
21
22
23
24
25
26
27
28
29
30
31

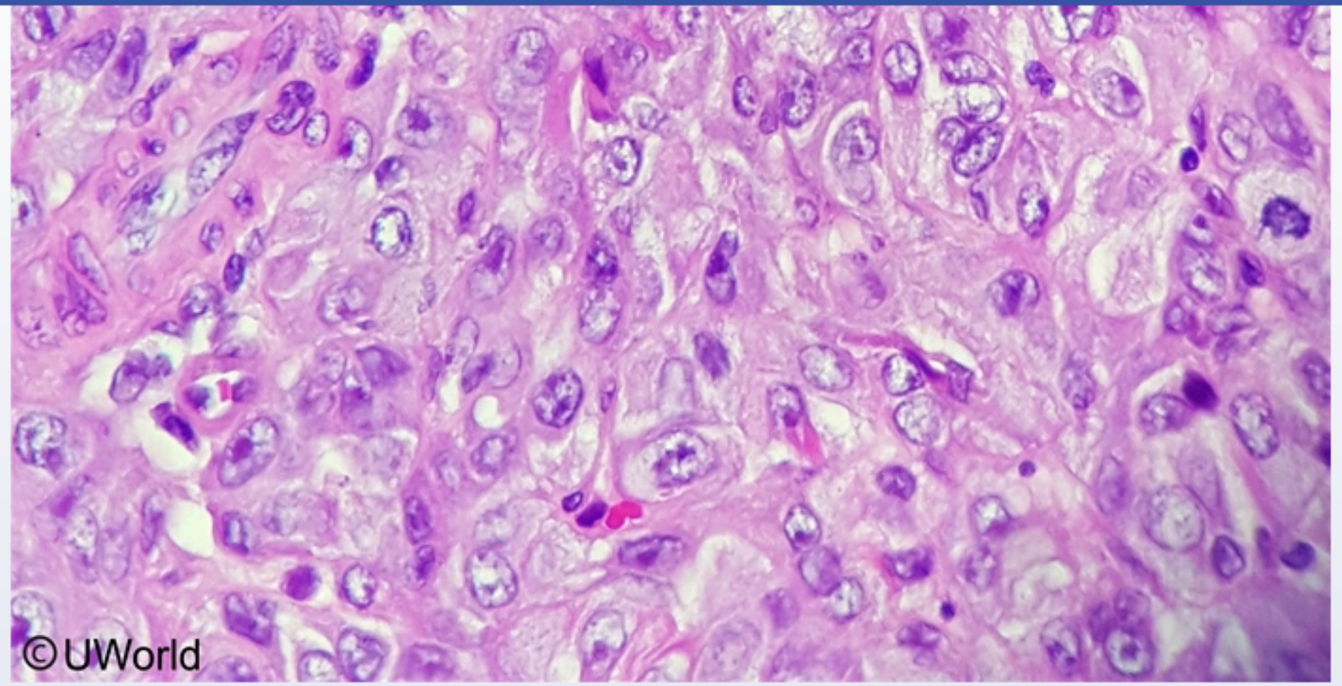

A. Direct invasion through the floor of mouth (7%)

B. Field cancerization of the oral cavity mucosa (14%)

✓ C. Lymphatic drainage to the submandibular lymph nodes (71%)

D. Perineural spread through the lingual nerve (1%)

E. Sublingual vein to the submandibular gland (4%)

Omitted
Correct answer

71%
Answered correctly

10 secs
Time Spent

03/27/2020
Last Updated

Cancer routes of spread		
Type	**Definition**	**Examples**
Direct invasion	Extension into neighboring tissues	• Most cancers
Lymphatics	Embolic drainage or invasion into lymphatic channels allows spread to regional lymph nodes	• Most carcinomas
Hematogenous	Embolic spread through the vasculature (usually veins)	• Sarcomas • Renal cell carcinoma • Hepatocellular carcinoma
Transcoelomic	Spread throughout a body cavity	• Ovarian tumor → surface of the liver
Perineural	Spread along nerves or nerve sheaths	• Pancreatic ductal adenocarcinoma • Prostate cancer

This patient with an ulcerative lesion in the floor of mouth and ipsilateral lymphadenopathy in the submandibular area has a biopsy that shows malignant cells with atypical mitotic figures and keratin pearls, findings which are consistent with **head and neck mucosal squamous cell carcinoma** (HNSCC).

Most **carcinomas**, including head and neck squamous cell carcinoma, first **spread** from the primary site of the tumor to **regional lymph nodes** via the **lymphatics**. In this patient with a floor of mouth squamous cell carcinoma, the spread is to the upper anterior cervical lymph nodes, manifesting as submandibular lymphadenopathy.

Assessment of regional lymph node status is important for tumor staging based on the **TNM staging system**, which evaluates the size and characteristics of the **T**umor, regional lymph **N**ode involvement, and distant **M**etastases. The presence of metastases is indicative of advanced cancer and often confers a poor prognosis.

Most **carcinomas**, including head and neck squamous cell carcinoma, first **spread** from the primary site of the tumor to **regional lymph nodes** via the **lymphatics**. In this patient with a floor of mouth squamous cell carcinoma, the spread is to the upper anterior cervical lymph nodes, manifesting as submandibular lymphadenopathy.

Assessment of regional lymph node status is important for tumor staging based on the **TNM staging system**, which evaluates the size and characteristics of the **T**umor, regional lymph **N**ode involvement, and distant **M**etastases. The presence of metastases is indicative of advanced cancer and often confers a poor prognosis.

(Choice A) Direct invasion through the floor of mouth can occur in head and neck squamous cell carcinoma and result in extension to the submandibular space. However, it is likely to present as a large, fungating mass with local destruction (eg, bony invasion).

(Choice B) Field cancerization refers to widespread, premalignant damage to cells in a large area. It is thought to be responsible for the high rate of synchronous tumors in patients with head and neck squamous cell carcinomas.

(Choice D) Perineural invasion occurs in many cancers, including head and neck cancer, and conveys a poor prognosis. It may contribute to some symptoms of cancer, including numbness or pain, but is not responsible for disease in the lymph nodes of this patient.

(Choice E) Hematogenous spread of cancer typically follows venous drainage routes and is common in sarcomas and a few carcinomas (eg, renal cell carcinoma, hepatocellular carcinoma); however, it is not typical in head and neck squamous cell carcinoma.

Educational objective:
Head and neck squamous cell carcinomas typically spread first to the anterior cervical lymph nodes via the lymphatics. The involvement of anterior cervical lymph nodes affects the staging of the disease.

References

- The molecular biology of head and neck cancer.
- An evolutionary perspective on field cancerization.

Pathophysiology	Hematology & Oncology	Head and neck cancers
Subject	System	Topic

1
2
3
4
5
6
7
8
9
10
11
12
13
14
15
16
17
18
19
20
21
22
23
24
25
26
27
28
29
30
31

Lymphatics | lymph nodes | Most carcinomas

Exhibit Display

Metastatic SCC in a lymph node

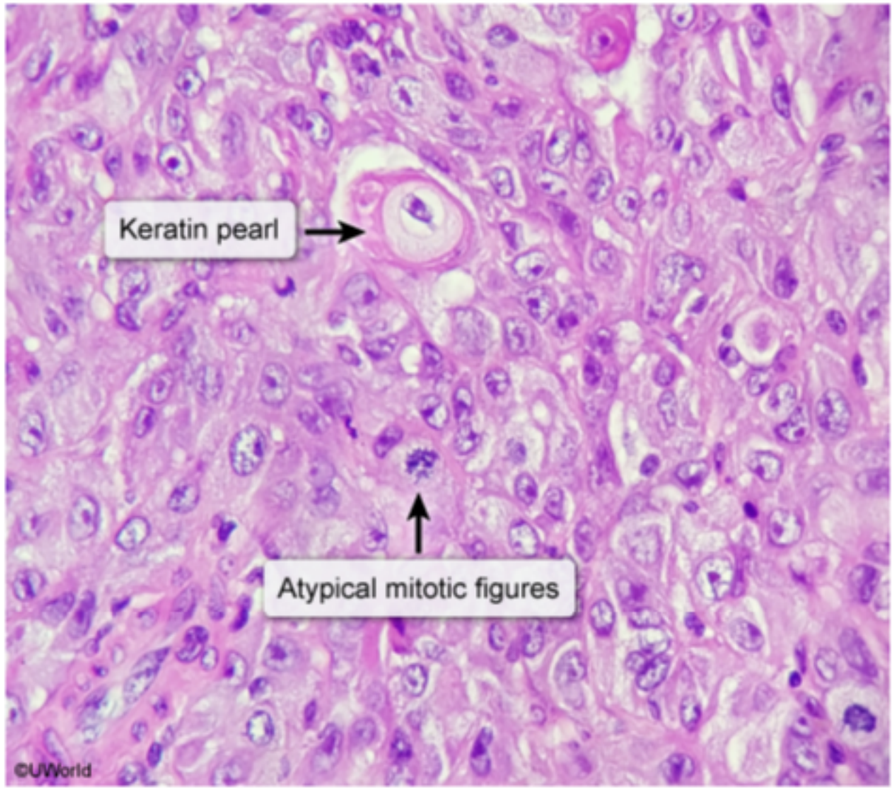

Zoom In | Zoom Out | Reset | Add To Flash Card

some symptoms of cancer, including numbness or pain, but is not responsible for disease in the lymph nodes of this patient.

1
2
3
4
5
6
7
8
9
10
11
12
13
14
15
16
17
18
19
20
21
22
23
24
25
26
27
28
29
30
31

via the **lymphatics**. In this patient with a floor of mouth squamous cell carcinoma, the spread is to the upper anterior cervical lymph nodes, manifesting as submandibular lymphadenopathy.

Assessment of regional lymph node status is important for tumor staging based on the **TNM staging system**, which evaluates the size and characteristics of the **T**umor, regional lymph **N**ode involvement, and distant **M**etastases. The presence of metastases is indicative of advanced cancer and often confers a poor prognosis.

(Choice A) Direct invasion through the floor of mouth can occur in head and neck squamous cell carcinoma and result in extension to the submandibular space. However, it is likely to present as a large, fungating mass with local destruction (eg, bony invasion).

(Choice B) Field cancerization refers to widespread, premalignant damage to cells in a large area. It is thought to be responsible for the high rate of synchronous tumors in patients with head and neck squamous cell carcinomas.

(Choice D) Perineural invasion occurs in many cancers, including head and neck cancer, and conveys a poor prognosis. It may contribute to some symptoms of cancer, including numbness or pain, but is not responsible for disease in the lymph nodes of this patient.

(Choice E) Hematogenous spread of cancer typically follows venous drainage routes and is common in sarcomas and a few carcinomas (eg, renal cell carcinoma, hepatocellular carcinoma); however, it is not typical in head and neck squamous cell carcinoma.

Educational objective:
Head and neck squamous cell carcinomas typically spread first to the anterior cervical lymph nodes via the lymphatics. The involvement of anterior cervical lymph nodes affects the staging of the disease.

References

- The molecular biology of head and neck cancer.
- An evolutionary perspective on field cancerization.

Pathophysiology	Hematology & Oncology	Head and neck cancers
Subject	System	Topic

Copyright © UWorld. All rights reserved.

A 56-year-old, previously healthy man has worsening fatigue and recurrent epistaxis. Evaluation shows anemia, thrombocytopenia, and abnormal circulating leukocytes. Bone marrow biopsy establishes a diagnosis of acute myeloid leukemia. The patient is initially treated with induction chemotherapy, and an allogeneic hematopoietic stem cell transplant is recommended. A nonrelated, HLA–matched donor is not found, so the patient's adult son volunteers to be the donor. The plan is for the patient to receive conditioning chemotherapy and radiotherapy followed by bone marrow transplant. Prior to transplant, a procedure is performed to deplete $CD3^+$ cells in the marrow graft. This pretransplant procedure would be most helpful in decreasing this patient's risk for which of the following?

A. Cytomegalovirus infection

B. Graft versus host disease

C. Immunoglobulin deficiency

D. Leukemia relapse

E. Lymphoproliferative disease

Submit

A 56-year-old, previously healthy man has worsening fatigue and recurrent epistaxis. Evaluation shows anemia, thrombocytopenia, and abnormal circulating leukocytes. Bone marrow biopsy establishes a diagnosis of acute myeloid leukemia. The patient is initially treated with induction chemotherapy, and an allogeneic hematopoietic stem cell transplant is recommended. A nonrelated, HLA–matched donor is not found, so the patient's adult son volunteers to be the donor. The plan is for the patient to receive conditioning chemotherapy and radiotherapy followed by bone marrow transplant. Prior to transplant, a procedure is performed to deplete $CD3^+$ cells in the marrow graft. This pretransplant procedure would be most helpful in decreasing this patient's risk for which of the following?

- A. Cytomegalovirus infection (2%)
- ✓ B. Graft versus host disease (85%)
- C. Immunoglobulin deficiency (0%)
- D. Leukemia relapse (7%)
- E. Lymphoproliferative disease (4%)

Omitted
Correct answer
B

85%
Answered correctly

02 secs
Time Spent

04/10/2020
Last Updated

Explanation

Graft versus host disease	
	• Most commonly occurs after allogeneic hematopoietic cell transplant • Donor $CD3^+$ T cells recognize host cells as foreign → widespread, multisystem inflammatory response

Graft versus host disease	

Etiology	• Most commonly occurs after allogeneic hematopoietic cell transplant
	• Donor CD3⁺ T cells recognize host cells as foreign → widespread, multisystem inflammatory response
	• Increased risk with:
	  ◦ HLA mismatch
	  ◦ Lack of pretransplant CD3⁺ T-cell depletion

Clinical manifestations	• Skin: maculopapular rash, which can progress to bullous lesions • Liver: abnormal function tests (eg, increased bilirubin & alkaline phosphatase) • Gastrointestinal tract: diarrhea, abdominal pain, nausea & vomiting

HLA = human leukocyte antigen.

Allogeneic stem cell transplantation is used in the treatment of leukemia to provide a new source of hematopoietic stem cells (HSCs) after destruction of the patient's immune cells (including malignant cells) with chemoradiotherapy. The donor's HSCs are frequently obtained from bone marrow or peripheral blood and contain differentiated immune cells such as **CD3⁺ T cells**.

These donor CD3⁺ (CD4⁺/CD8⁺) T cells can recognize human leukocyte antigen (HLA)–mismatched host cells (including residual leukemia cells) as foreign, providing a beneficial **graft versus leukemia/tumor** effect. However, they can also attack normal host cells and initiate **graft versus host disease** (GVHD), a widespread inflammatory response that characteristically damages the skin (eg, maculopapular rash), gastrointestinal tract (eg, diarrhea, abdominal pain), and liver (eg, elevated serum bilirubin).

Depletion of donor CD3⁺ T cells prior to HSC transplant is performed primarily to **decrease GVHD risk**, but it also has the following undesirable effects on the host:

- Decreased graft versus leukemia effect, increasing the risk of leukemia relapse **(Choice D)**.
- Depletion of memory T cells, which increases the risk of viral (eg, cytomegalovirus, human herpes virus 6) infections **(Choice A)**. This also increases the risk of posttransplant lymphoproliferative disease due to the reduction in donor T cells that normally attack proliferating B cells infected with Epstein-Barr virus **(Choice E)**.

Allogeneic stem cell transplantation is used in the treatment of leukemia to provide a new source of hematopoietic stem cells (HSCs) after destruction of the patient's immune cells (including malignant cells) with chemoradiotherapy. The donor's HSCs are frequently obtained from bone marrow or peripheral blood and contain differentiated immune cells such as **$CD3^+$ T cells**.

These donor $CD3^+$ ($CD4^+/CD8^+$) T cells can recognize human leukocyte antigen (HLA)–mismatched host cells (including residual leukemia cells) as foreign, providing a beneficial **graft versus leukemia/tumor** effect. However, they can also attack normal host cells and initiate **graft versus host disease** (GVHD), a widespread inflammatory response that characteristically damages the skin (eg, maculopapular rash), gastrointestinal tract (eg, diarrhea, abdominal pain), and liver (eg, elevated serum bilirubin).

Depletion of donor $CD3^+$ T cells prior to HSC transplant is performed primarily to **decrease GVHD risk**, but it also has the following undesirable effects on the host:

- Decreased graft versus leukemia effect, increasing the risk of leukemia relapse **(Choice D)**.
- Depletion of memory T cells, which increases the risk of viral (eg, cytomegalovirus, human herpes virus 6) infections **(Choice A)**. This also increases the risk of posttransplant lymphoproliferative disease due to the reduction in donor T cells that normally attack proliferating B cells infected with Epstein-Barr virus **(Choice E)**.

(Choice C) Immunoglobulin deficiency is a normal effect of myeloablative chemoradiotherapy that improves over time with engraftment (proliferation and differentiation) of donor HSCs. Removal of donor T cells before the transplant would increase the period of B cell and immunoglobulin deficiency by slowing engraftment and reestablishment of host immune function.

Educational objective:
Allogeneic hematopoietic stem cell grafts normally include donor $CD3^+$ T cells that can initiate graft versus host disease (GVHD), a widespread inflammatory response that can damage multiple organs. Depletion of donor $CD3^+$ T cells prior to transplant decreases the risk of GVHD but also decreases the beneficial graft versus tumor effect, increasing the likelihood of cancer relapse.

Pathophysiology	Hematology & Oncology	Bone marrow transplantation
Subject	System	Topic

Copyright © UWorld. All rights reserved.

1
2
3
4
5
6
7
8
9
10
11
12
13
14
15
16
17
18
19
20
21
22
23
24
25
26
27
28
29
30
31

A 66-year-old woman is brought to the emergency department due to left leg pain. Five days ago, the patient underwent elective right hip arthroplasty for advanced osteoarthritis. She had been recovering well at an acute rehabilitation facility until she woke today with severe left calf pain and swelling. The patient has taken daily subcutaneous, low-molecular-weight heparin and as-needed acetaminophen since the surgery. She has no other medical conditions. Temperature is 37 C (98.6 F), blood pressure is 130/70 mm Hg, and pulse is 92/min. The surgical incision over her right hip is healing well. Her left posterior calf is tender and swollen to the knee. Three days ago, complete blood count was normal, but platelet count is now 70,000/mm^3. Peripheral blood smear shows decreased platelet number but no other abnormalities. Which of the following is the most likely cause of this patient's thrombocytopenia?

A. Decreased bone marrow platelet production

B. Mechanical destruction of platelets

C. Non–immune-mediated platelet clumping

D. Platelet removal by splenic macrophages

E. Uncontrolled activation of the coagulation cascade

Submit

1
2
3
4
5
6
7
8
9
10
11
12
13
14
15
16
17
18
19
20
21
22
23
24
25
26
27
28
29
30
31

A 66-year-old woman is brought to the emergency department due to left leg pain. Five days ago, the patient underwent elective right hip arthroplasty for advanced osteoarthritis. She had been recovering well at an acute rehabilitation facility until she woke today with severe left calf pain and swelling. The patient has taken daily subcutaneous, low-molecular-weight heparin and as-needed acetaminophen since the surgery. She has no other medical conditions. Temperature is 37 C (98.6 F), blood pressure is 130/70 mm Hg, and pulse is 92/min. The surgical incision over her right hip is healing well. Her left posterior calf is tender and swollen to the knee. Three days ago, complete blood count was normal, but platelet count is now 70,000/mm^3. Peripheral blood smear shows decreased platelet number but no other abnormalities. Which of the following is the most likely cause of this patient's thrombocytopenia?

A. Decreased bone marrow platelet production (2%)

B. Mechanical destruction of platelets (9%)

C. Non–immune-mediated platelet clumping (40%)

✓ D. Platelet removal by splenic macrophages (26%)

E. Uncontrolled activation of the coagulation cascade (19%)

Omitted
Correct answer
D

26%
Answered correctly

01 sec
Time Spent

03/13/2020
Last Updated

Explanation

Heparin-induced thrombocytopenia & thrombosis

1
2
3
4
5
6
7
8
9
10
11
12
13
14
15
16
17
18
19
20
21
22
23
24
25
26
27
28
29
30
31

Heparin-induced thrombocytopenia & thrombosis

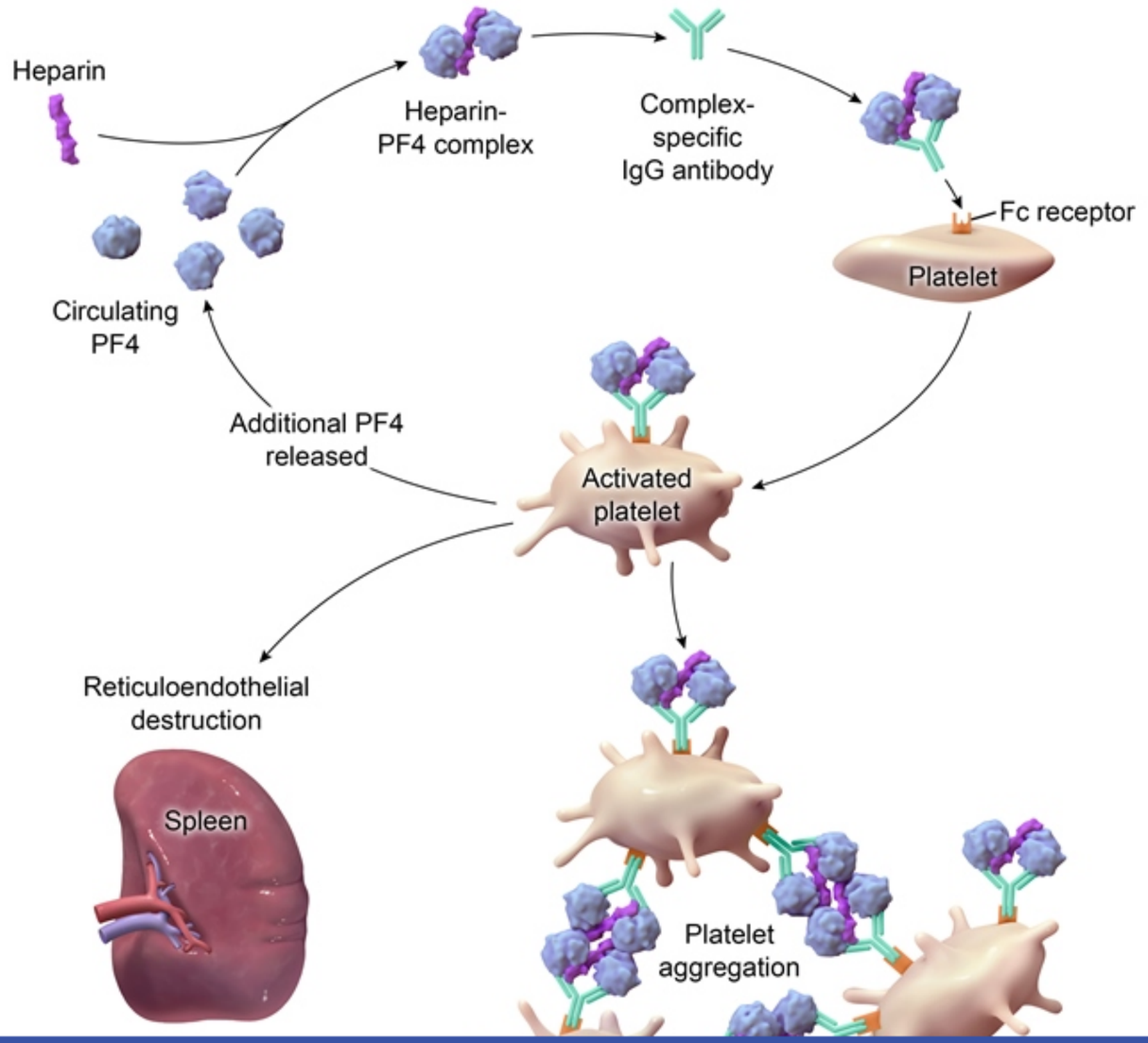

1
2
3
4
5
6
7
8
9
10
11
12
13
14
15
16
17
18
19
20
21
22
23
24
25
26
27
28
29
30
31

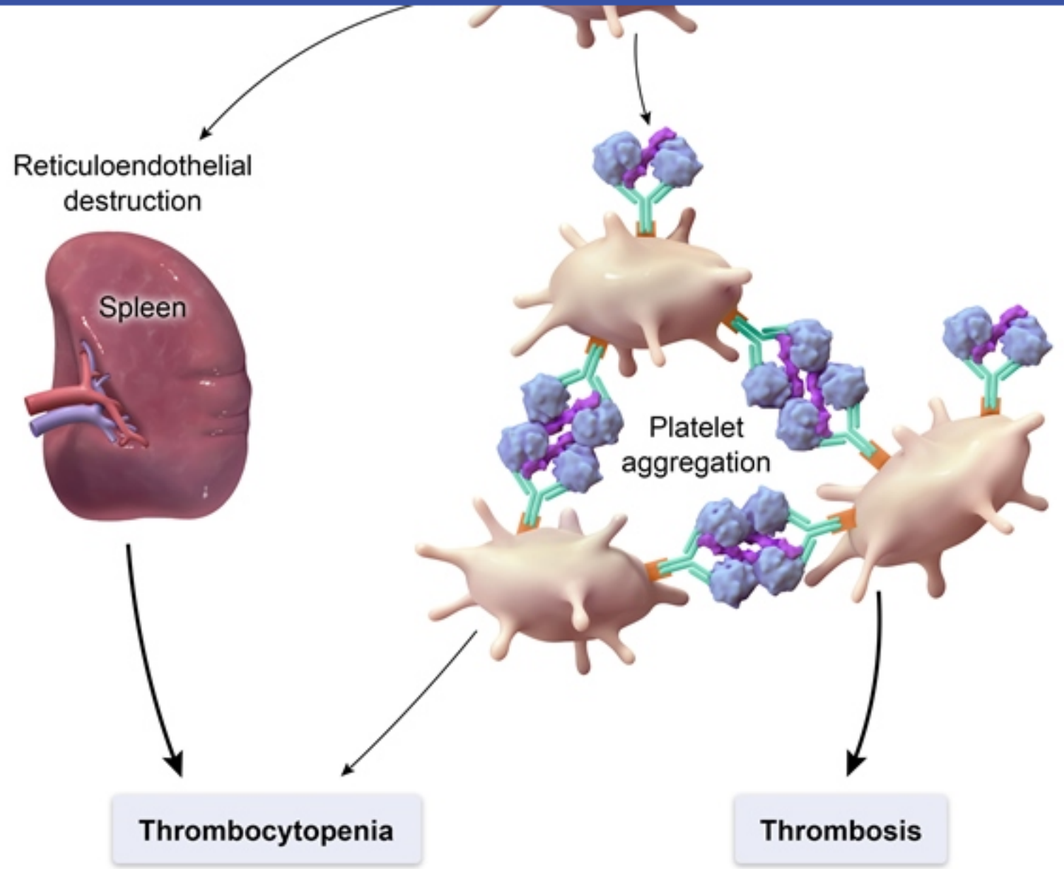

PF4 = platelet factor 4.

©UWorld

This patient on low-molecular-weight heparin developed thrombocytopenia and deep venous thrombosis (calf pain/swelling), raising strong suspicion for heparin-induced thrombocytopenia **(HIT) type 2**. In HIT type 2, heparin induces a conformational change in platelet-factor 4, leading to the formation of a neoantigen. **IgG antibodies** form against the neoantigen (**heparin-platelet factor 4**), which results in antibody aggregation on the platelet surface.

Patients generally develop manifestations **5-10 days** after heparin initiation. **Thrombocytopenia** is the hallmark feature due to the clearance of

Patients generally develop manifestations **5-10 days** after heparin initiation. **Thrombocytopenia** is the hallmark feature due to the clearance of antibody-coated platelets by **splenic macrophages**. Antibody aggregation on the platelet surface also results in wide-spread platelet aggregation, which worsens the thrombocytopenia and significantly increases the risk of **venous and arterial thrombosis**.

Patients with HIT-type 2 should immediately stop heparin and be initiated on a **nonheparin anticoagulant** (eg, argatroban) to help prevent/treat thrombosis.

(Choice A) Although bone marrow suppression can cause thrombocytopenia, it most often occurs in the setting of malignant invasion of the bone marrow (eg, leukemia) or chemical toxicity (eg, chemotherapy, excessive alcohol). Thrombosis is uncommon.

(Choices B and E) Mechanical destruction of platelets can be seen with a mechanical prosthetic heart valve or in disseminated intravascular coagulation, a condition marked by the excessive activation of the coagulation cascade. In both of these conditions, thrombocytopenia is accompanied by schistocytes on peripheral blood smear.

(Choice C) HIT type 1 is a non–immune-mediated condition caused by platelet clumping. Thrombocytopenia is typically mild (nadir ~100,000/mm^3), and most cases arise within 2 days of heparin administration. It does not cause thrombosis and is not considered clinically significant; therefore, heparin can be continued.

Educational objective:
Heparin-induced thrombocytopenia type 2 results from the formation of IgG antibodies to complexes of heparin and endogenous platelet factor 4. The major manifestation is thrombocytopenia, which typically occurs 5-10 days after heparin initiation due to the destruction of antibody-coated platelets by splenic macrophages. Widespread intravascular platelet activation also results in a high risk of arterial and venous thrombosis.

References

- Heparin-induced thrombocytopenia.

Pathophysiology	Hematology & Oncology	Heparin induced thrombocytopenia
Subject	System	Topic

Copyright © UWorld. All rights reserved.

A 54-year-old woman comes to the office due to 3 months of progressive pain and prolonged morning stiffness in her hand joints. She has tried over-the-counter naproxen without significant relief. Review of systems is positive for fatigue. The patient has no other chronic medical conditions and takes no other medications regularly. Vital signs are normal. Swelling and tenderness of the proximal interphalangeal joints and metacarpophalangeal joints are present in both hands. Laboratory studies reveal a hemoglobin of 9.8 g/dL and MCV of 86. The patient is prescribed methotrexate therapy. Laboratory results 6 months later reveal that hemoglobin has increased to 12 g/dL. If measured, which of the following changes were most likely present in this patient before the start of methotrexate therapy?

	Circulating iron level	Bone marrow iron
A.	Low	High
B.	Low	Low
C.	High	Low
D.	High	High
E.	Normal	Low
F.	High	Normal

Submit

A 54-year-old woman comes to the office due to 3 months of progressive pain and prolonged morning stiffness in her hand joints. She has tried over-the-counter naproxen without significant relief. Review of systems is positive for fatigue. The patient has no other chronic medical conditions and takes no other medications regularly. Vital signs are normal. Swelling and tenderness of the proximal interphalangeal joints and metacarpophalangeal joints are present in both hands. Laboratory studies reveal a hemoglobin of 9.8 g/dL and MCV of 86. The patient is prescribed methotrexate therapy. Laboratory results 6 months later reveal that hemoglobin has increased to 12 g/dL. If measured, which of the following changes were most likely present in this patient before the start of methotrexate therapy?

	Circulating iron level	Bone marrow iron
✓ A. (65%)	Low	High
B. (16%)	Low	Low
C. (5%)	High	Low
D. (1%)	High	High
E. (7%)	Normal	Low
F. (3%)	High	Normal

Omitted
Correct answer
A

65%
Answered correctly

02 secs
Time Spent

05/27/2020
Last Updated

Explanation

This patient's polyarticular hand joint pain, swelling, and prolonged morning stiffness are suggestive of rheumatoid arthritis (RA). Patients with chronic rheumatologic diseases such as RA have high circulating levels of inflammatory cytokines, which can trigger **anemia of chronic disease** (ACD) due to maladaptive changes in iron utilization.

ACD is primarily mediated by **hepcidin**, a small peptide released by the liver in response to inflammation. Hepcidin binds to and inactivates iron channels (ferroportin) on enterocytes and reticuloendothelial macrophages, leading to reduced iron absorption in the gut and reduced iron recycling by the reticuloendothelial system (the site of senescent erythrocyte destruction and the source of >95% of daily iron for new RBC production). These changes significantly **reduce circulating iron levels**, which impairs the generation of heme for new erythrocytes. Although patients with suspected ACD do not generally require bone marrow biopsy for diagnosis, it would show **increased sequestration of iron within macrophages** and reduced quantities of erythrocyte precursor cells (eg, normoblasts, reticulocytes).

Patients with ACD typically develop a normocytic (or slightly microcytic) anemia with low reticulocyte count. Treatment of the underlying inflammatory condition (eg, methotrexate for RA) reduces serum inflammatory cytokine levels and generally improves the anemia.

(Choice B) In contrast to ACD, patients with iron deficiency anemia have reduced serum iron levels and reduced bone marrow iron levels due to low total body iron stores.

Educational objective:
Anemia of chronic disease is caused by elevated inflammatory cytokine levels (eg, hepcidin), which increase sequestration of iron within the reticuloendothelial system and reduce circulating iron levels. Many patients have improvement in anemia with treatment of the underlying condition that caused the inflammation.

Pathophysiology	Hematology & Oncology	Anemia of inflammation
Subject	System	Topic

Copyright © UWorld. All rights reserved.

A 55-year-old man comes to the office due to several months of progressive fatigue. He does not have chest pain or shortness of breath. Medical history is significant for hypertension and obesity. BMI is 45 kg/m^2. Examination shows mild mucosal pallor. Laboratory results are as follows:

Complete blood count	
Hemoglobin	8.6 g/dL
Mean corpuscular volume	84 μm^3
Reticulocytes	0.2%
Platelets	200,000/mm^3
Leukocytes	7,500/mm^3

Serum chemistry	
Blood urea nitrogen	14 mg/dL
Creatinine	0.8 mg/dL

Which of the following is the most likely cause of this patient's anemia?

A. Anemia of chronic inflammation
B. Extravascular hemolysis
C. Microangiopathic hemolytic anemia
D. Occult blood loss
E. Vitamin B_{12} deficiency

Complete blood count	
Hemoglobin	8.6 g/dL
Mean corpuscular volume	84 μm^3
Reticulocytes	0.2%
Platelets	200,000/mm^3
Leukocytes	7,500/mm^3
Serum chemistry	
Blood urea nitrogen	14 mg/dL
Creatinine	0.8 mg/dL

Which of the following is the most likely cause of this patient's anemia?

- ✓ A. Anemia of chronic inflammation (52%)
- B. Extravascular hemolysis (8%)
- C. Microangiopathic hemolytic anemia (6%)
- D. Occult blood loss (29%)
- E. Vitamin B_{12} deficiency (2%)

Omitted
Correct answer

52%
Answered correctly

04 secs
Time Spent

06/15/2020
Last Updated

Anemia of chronic disease	
Pathogenesis	• ↑ inflammatory cytokines (eg, hepcidin) • Inhibition of ferroportin on enterocytes and macrophages • ↓ iron absorption and ↑ iron sequestration • Reduced circulating iron → impaired erythropoiesis
Common Etiologies	• Malignancy • Chronic infection • Rheumatic disease • Obesity • Diabetes mellitus • Congestive heart failure
Laboratory findings	• Normocytic/slightly microcytic anemia • ↓ serum iron, iron-binding capacity, reticulocyte count • ↑ bone marrow iron • ↑ erythropoietin
Treatment	• Treat underlying condition causing inflammation

This patient with morbid obesity has normocytic anemia with a low reticulocyte count, raising strong suspicion for **anemia of chronic disease** (ACD). Because ACD is triggered by **long-standing elevations in serum inflammatory cytokines**, it is classically associated with underlying rheumatologic disease, persistent infection, or malignancy. However, ACD is also commonly caused by less obvious sources of inflammation such as type 2 diabetes mellitus, congestive heart failure, severe traumatic injury, and **morbid obesity**.

The major inflammatory cytokine that drives ACD is **hepcidin**, a small peptide released from the liver in response to inflammation or bacterial lipopolysaccharide. Hepcidin binds to and **inhibits iron channels** (ferroportin) on the surface of enterocytes and reticuloendothelial macrophages, leading to decreased iron absorption in the gut and decreased iron release by the reticuloendothelial system (which supplies ~95%

(ACD). Because ACD is triggered by **long-standing elevations in serum inflammatory cytokines**, it is classically associated with underlying rheumatologic disease, persistent infection, or malignancy. However, ACD is also commonly caused by less obvious sources of inflammation such as type 2 diabetes mellitus, congestive heart failure, severe traumatic injury, and **morbid obesity**.

The major inflammatory cytokine that drives ACD is **hepcidin**, a small peptide released from the liver in response to inflammation or bacterial lipopolysaccharide. Hepcidin binds to and **inhibits iron channels** (ferroportin) on the surface of enterocytes and reticuloendothelial macrophages, leading to decreased iron absorption in the gut and decreased iron release by the reticuloendothelial system (which supplies ~95% of daily iron for erythropoiesis). Because heme synthesis is impaired without sufficient iron, patients with ACD typically develop a **normocytic** (or slightly microcytic) **anemia** with a **minimal reticulocyte response**.

(Choice B) Extravascular hemolysis typically occurs due to the formation of IgG autoantibodies against the erythrocyte membrane, which results in erythrocyte destruction by splenic macrophages. Patients generally develop an acute normocytic anemia with a strong (not suppressed) reticulocyte response.

(Choice C) Microangiopathic hemolytic anemia is associated with shearing of red blood cells in the microvasculature due to the formation of fibrin-rich platelet clots. Patients typically have normocytic anemia, significant reticulocytosis, and severe thrombocytopenia (~10,000/mm^3).

(Choice D) Iron deficiency anemia (IDA) from an occult gastrointestinal bleed is common in older individuals. IDA is also associated with a low reticulocyte count. Although IDA can cause mild normocytic anemia early in the disease course, by the time individuals develop profound anemia (eg, hemoglobin of 8.6 mg/dL), they almost always have severe microcytosis (eg, MCV < 70). This patient's severe anemia is accompanied by a normal MCV, making iron deficiency anemia highly unlikely.

(Choice E) Vitamin B_{12} deficiency is associated with macrocytic (not normocytic) anemia due to impaired maturation of erythrocytes.

Educational objective:
Anemia of chronic disease (ACD) occurs in patients with rheumatologic diseases, chronic infection, malignancy, congestive heart failure, and morbid obesity due to chronic elevation of inflammatory cytokines. The primary mediator is hepcidin, a peptide released from the liver that inhibits iron channels on enterocytes and reticuloendothelial macrophages. This reduces iron availability for erythropoiesis, which leads to normocytic (or slightly microcytic) anemia with a poor reticulocyte response.

Pathophysiology Hematology & Oncology Anemia of inflammation

A 45-year-old man comes to the office due to 3 months of exertional fatigue and weight loss. He is sexually active with multiple male partners. Temperature is 37.9 C (100.2 F), blood pressure is 110/70 mm Hg, pulse is 84/min, and respirations are 13/min. BMI is 20 kg/m^2. The patient appears chronically ill and has mucosal pallor. There are thick, white plaques over the buccal mucosa and soft palate. Anterior and posterior cervical lymphadenopathy is present. The lungs are clear to auscultation. The abdomen is soft and nontender. There is no organomegaly. Laboratory results are as follows:

Hematocrit	28%	
Mean corpuscular volume	76 μm^3	
Platelets	160,000/mm^3	
Leukocytes	4,100/mm^3	
Iron, serum	30 μg/dL	
Total iron-binding capacity	190 μg/dL	(normal: 250-460 μg/dL)

Which of the following is the most likely underlying cause of this patient's anemia?

A. Abnormal iron utilization
B. Decreased synthesis of globin chains
C. Deposition of fibrin in the microcirculation
D. Gastrointestinal blood loss
E. Deficiency of a heme synthesis enzyme

Submit

cervical lymphadenopathy is present. The lungs are clear to auscultation. The abdomen is soft and nontender. There is no organomegaly.

Laboratory results are as follows:

Hematocrit	28%	
Mean corpuscular volume	76 μm^3	
Platelets	160,000/mm^3	
Leukocytes	4,100/mm^3	
Iron, serum	30 µg/dL	
Total iron-binding capacity	190 µg/dL	(normal: 250-460 µg/dL)

Which of the following is the most likely underlying cause of this patient's anemia?

- ✓ A. Abnormal iron utilization (76%)
- B. Decreased synthesis of globin chains (4%)
- C. Deposition of fibrin in the microcirculation (2%)
- D. Gastrointestinal blood loss (12%)
- E. Deficiency of a heme synthesis enzyme (3%)

Omitted
Correct answer
A

76%
Answered correctly

02 secs
Time Spent

05/29/2020
Last Updated

Explanation

Anemia of chronic disease	
Pathogenesis	• ↑ inflammatory cytokines (eg, hepcidin) • Inhibition of ferroportin on enterocytes and macrophages • ↓ iron absorption and ↑ iron sequestration • Reduced circulating iron → impaired erythropoiesis
Common Etiologies	• Malignancy • Chronic infection • Rheumatic disease • Obesity • Diabetes mellitus • Congestive heart failure
Laboratory findings	• Normocytic/slightly microcytic anemia • ↓ serum iron, iron-binding capacity, reticulocyte count • ↑ bone marrow iron • ↑ erythropoietin
Treatment	• Treat underlying condition causing inflammation

This patient's high-risk sexual history, weight loss, lymphadenopathy, chronically ill appearance, and oral candidiasis (white buccal/soft palate plaques) suggest undiagnosed HIV infection. Patients with chronic infections such as HIV often develop **anemia of chronic disease** (ACD) due to high circulating levels of inflammatory cytokines, which cause maladaptive **changes to iron utilization**.

Although ACD is mediated by a wide range of inflammatory cytokines (eg, IL-1, IL-6, tumor necrosis factor-alpha, interferon gamma), the major player is **hepcidin**, a small peptide released by the liver in response to inflammation. Hepcidin binds to and inhibits iron channels on enterocytes and reticuloendothelial macrophages, leading to reduced iron absorption in the gut and reduced iron recycling in the reticuloendothelial system (the site of senescent erythrocyte destruction). This significantly **reduces circulating serum iron**, which limits iron availability for erythropoiesis.

This patient's high-risk sexual history, weight loss, lymphadenopathy, chronically ill appearance, and oral candidiasis (white buccal/soft palate plaques) suggest undiagnosed HIV infection. Patients with chronic infections such as HIV often develop **anemia of chronic disease** (ACD) due to high circulating levels of inflammatory cytokines, which cause maladaptive **changes to iron utilization**.

Although ACD is mediated by a wide range of inflammatory cytokines (eg, IL-1, IL-6, tumor necrosis factor-alpha, interferon gamma), the major player is **hepcidin**, a small peptide released by the liver in response to inflammation. Hepcidin binds to and inhibits iron channels on enterocytes and reticuloendothelial macrophages, leading to reduced iron absorption in the gut and reduced iron recycling in the reticuloendothelial system (the site of senescent erythrocyte destruction). This significantly **reduces circulating serum iron**, which limits iron availability for erythropoiesis.

Patients with ACD typically develop normocytic or **slightly microcytic anemia** with a low reticulocyte response. **Total iron-binding** capacity is generally **reduced** due to cytokine-mediated suppression of transferrin. Treatment of the underlying condition (eg, antiretroviral therapy) often ameliorates or resolves ACD.

(Choice B) Decreased synthesis of globin chains is seen in thalassemia, a genetic disorder that presents with microcytic anemia and reduced erythrocyte life span. Serum iron levels tend to be high with thalassemia due to increased erythropoiesis to compensate for the anemia.

(Choice C) Fibrin deposition in the microvasculature is seen in disseminated intravascular coagulation, a consumptive coagulopathy marked by microangiopathic hemolytic anemia and significant thrombocytopenia. Patients typically have normocytic (not microcytic) anemia and normal or high serum iron levels.

(Choice D) Iron deficiency anemia also typically causes microcytic anemia with low serum iron. However, unlike ACD, iron deficiency anemia is typically associated with a high iron-binding capacity due to increased circulating transferrin levels.

(Choice E) Porphyria is a genetic disorder caused by deficiency of heme synthesis enzymes. Patients typically develop neurovisceral (eg, abdominal pain) or cutaneous (eg, blistering) manifestations. Microcytic anemia with low serum iron would be atypical.

Educational objective:
Anemia of chronic disease is caused by chronic elevations in inflammatory cytokines, which lead to reduced iron absorption and increased iron retention in the reticuloendothelial system. This impairs iron availability and causes a normocytic or slightly microcytic anemia with low serum iron and low total iron-binding capacity.

Although ACD is mediated by a wide range of inflammatory cytokines (eg, IL-1, IL-6, tumor necrosis factor-alpha, interferon gamma), the major player is **hepcidin**, a small peptide released by the liver in response to inflammation. Hepcidin binds to and inhibits iron channels on enterocytes and reticuloendothelial macrophages, leading to reduced iron absorption in the gut and reduced iron recycling in the reticuloendothelial system (the site of senescent erythrocyte destruction). This significantly **reduces circulating serum iron**, which limits iron availability for erythropoiesis.

Patients with ACD typically develop normocytic or **slightly microcytic anemia** with a low reticulocyte response. **Total iron-binding** capacity is generally **reduced** due to cytokine-mediated suppression of transferrin. Treatment of the underlying condition (eg, antiretroviral therapy) often ameliorates or resolves ACD.

(Choice B) Decreased synthesis of globin chains is seen in thalassemia, a genetic disorder that presents with microcytic anemia and reduced erythrocyte life span. Serum iron levels tend to be high with thalassemia due to increased erythropoiesis to compensate for the anemia.

(Choice C) Fibrin deposition in the microvasculature is seen in disseminated intravascular coagulation, a consumptive coagulopathy marked by microangiopathic hemolytic anemia and significant thrombocytopenia. Patients typically have normocytic (not microcytic) anemia and normal or high serum iron levels.

(Choice D) Iron deficiency anemia also typically causes microcytic anemia with low serum iron. However, unlike ACD, iron deficiency anemia is typically associated with a high iron-binding capacity due to increased circulating transferrin levels.

(Choice E) Porphyria is a genetic disorder caused by deficiency of heme synthesis enzymes. Patients typically develop neurovisceral (eg, abdominal pain) or cutaneous (eg, blistering) manifestations. Microcytic anemia with low serum iron would be atypical.

Educational objective:
Anemia of chronic disease is caused by chronic elevations in inflammatory cytokines, which lead to reduced iron absorption and increased iron retention in the reticuloendothelial system. This impairs iron availability and causes a normocytic or slightly microcytic anemia with low serum iron and low total iron-binding capacity.

Pathophysiology	Hematology & Oncology	Anemia of inflammation
Subject	System	Topic

Copyright © UWorld. All rights reserved.